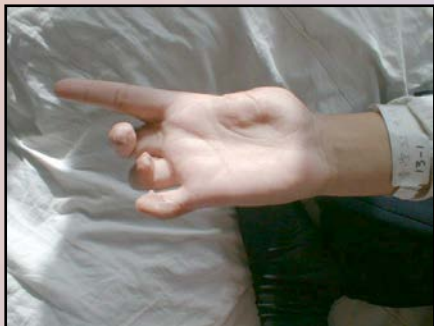
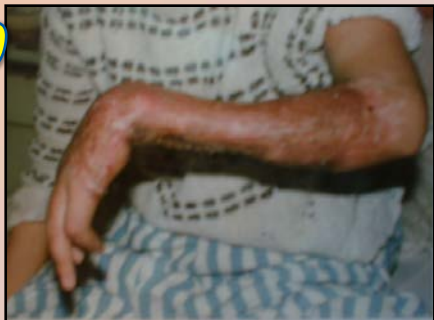
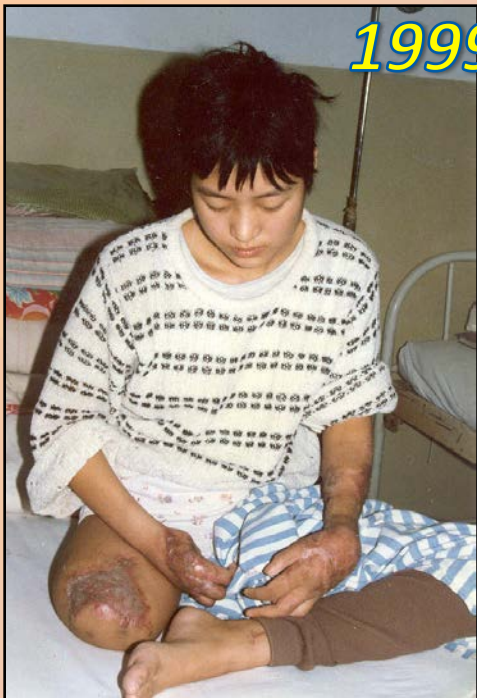1999

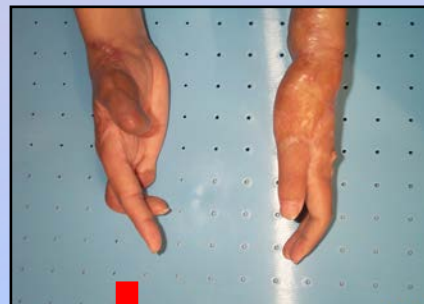
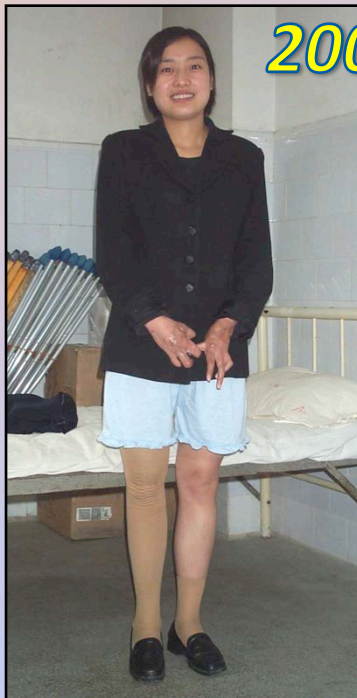

病人經過多次手術後並配了義肢



After several surgeries and fitting of prosthesis

2001



**1999年** 19歲女患者被火車撞倒，右手失去大姆指。左前臂骨折，手腕屈曲僵硬，左手基本上失去了功能。右腿因嚴重創傷而被切除。19 year old victim of train accident. Lost right thumb. Had fracture of left wrist with stiffness. Very poor function of left hand. Also had traumatic above-knee amputation.

**2001年** 天鄰骨科隊為她做了多次手，把右手的無名指轉移為大姆指，矯正了左腕的屈曲，為右下肢配上義肢。右手的功能恢復非常好，下肢行動自如。HIS Foundation surgery team performed many operations including transplantation of right ring finger to thumb, correction of left wrist, and fitting of above-knee prosthesis.

**2018年** 患者右手功能依然良好，行動自如。她除了照顧家人外，又幫助丈夫(農村醫生)的診所工作。Patient continues to have good right hand function and ambulates well. Besides taking care of family, she also assists her husband (village doctor) in the clinic.

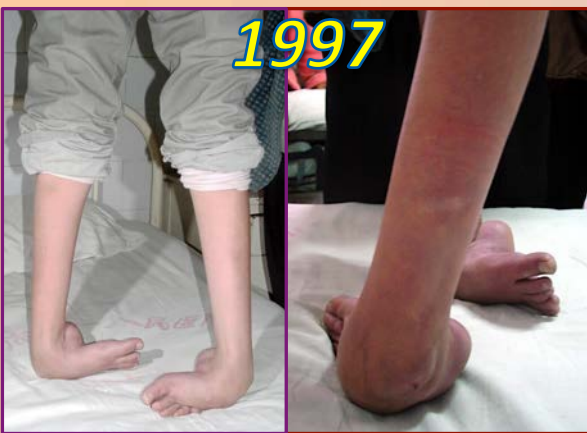2018



與天鄰工作人員合照  
photo with HIS workers



病人的家庭照 Family photo




1997

手術後  
雙足已  
矯正



Both feet  
were  
corrected  
after  
surgery



2018



16歲脊椎裂女病人雙足嚴重變形，不能走路。16 year old spina bifida female patient with severe feet deformity. Unable to walk.

病人及兒子。  
Patient and her son.

病人能正常工作及照顧家人。  
在鄭州機場迎接天鄰義工。  
Patient working and taking  
care of family. She welcome  
us at Zhangzhou Airport.



2018

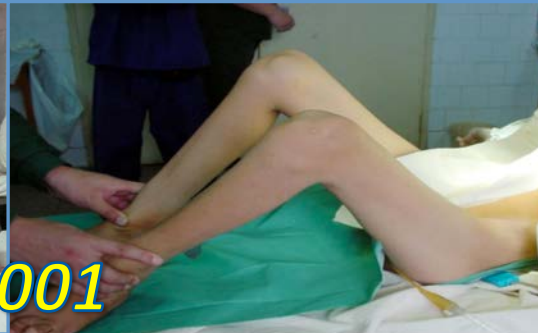手術後  
能用拐  
仗走路



Able to walk  
with crutches  
after surgery



2001



喜雙逢天鄰義工。  
Happy reunion.

病人全家照。  
Family photo.

13歲小兒麻痺病人，雙膝關節攣縮，不能站立。  
13 year old  
poliomyelitis patient with knee contractures. Unable to stand.

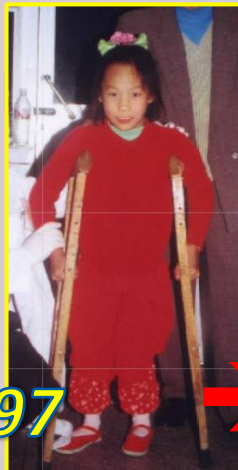

[www.his-foundation.org](http://www.his-foundation.org)  
HISFound@aol.com

1997年 9歲小兒麻痺女病人，下肢癱瘓，左髖關節攣縮，不能站立。手術後用拐杖走路。9 year old poliomyelitis patient with left hip flexion contracture. Unable to stand. Walked with crutches after surgery.



1997



2018



2018年 病人、家人和天鄰義工合照。  
Pictures with family  
and HIS worker