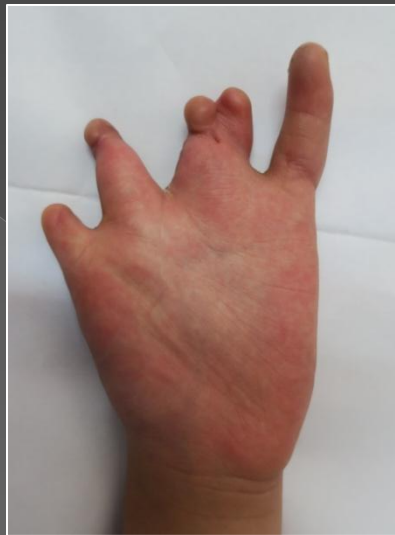
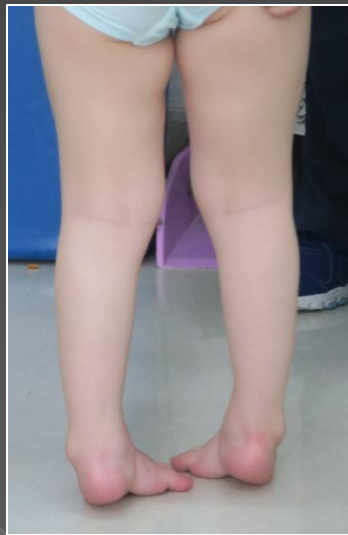


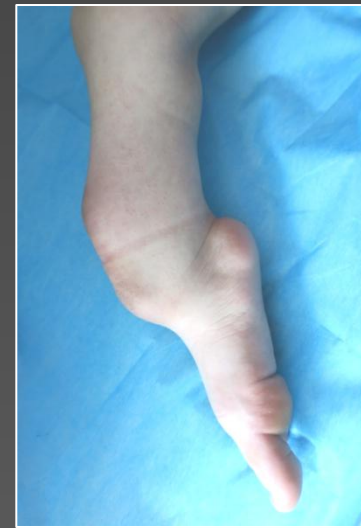腦癱，右偏癱
Cerebral palsy,
right hemiplegic
type



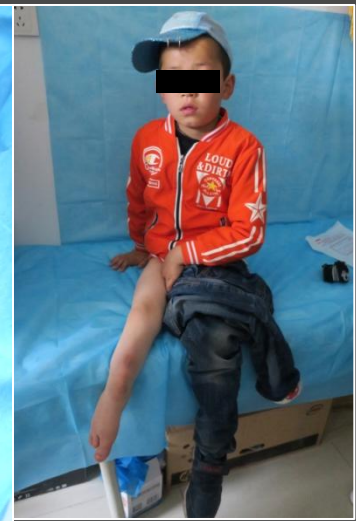併指
Syndactyly of fingers



先天內翻馬蹄
Bilateral congenital
clubfoot



先天性腓骨不全
Fibula hemelia



青海骨科及整形外科手術隊

Qinghai Orthopedics and Plastic Surgery Mission

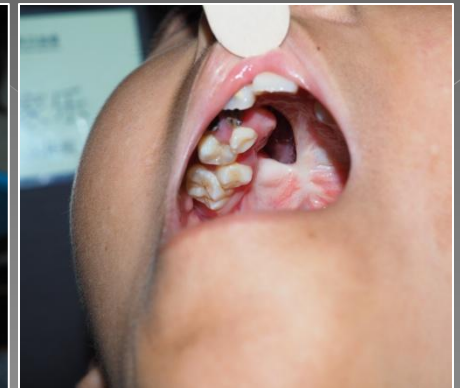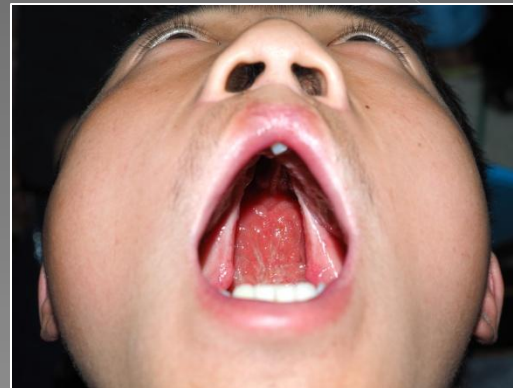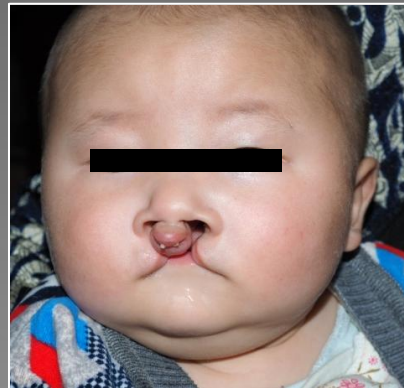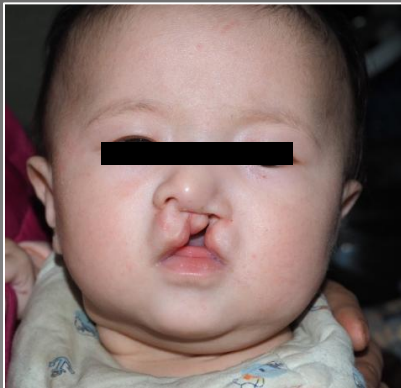18/3 -24/3/2018

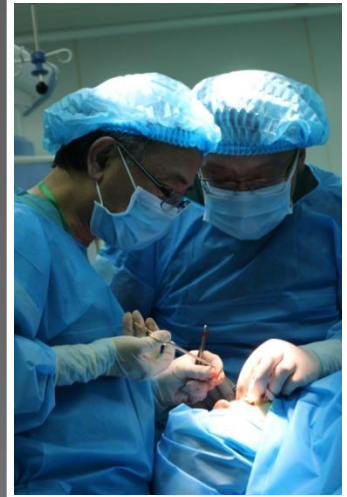
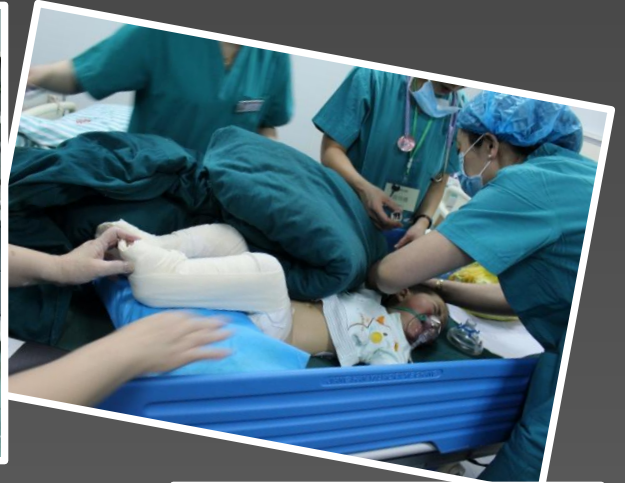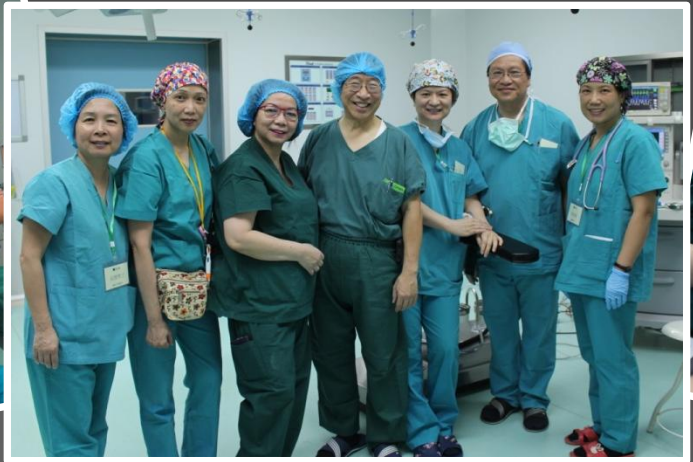www.his-foundation.org
HISFound@aol.com



兔唇患者 Harelip patients

裂顎患者 Cleft palate patients





手術隊小檔案
 隊員:28人
 隊員來自:美國、香港及澳洲
 骨科手術病人:6人
 骨科病人年齡:2-7歲
 唇顎裂手術病人:30人
 唇顎裂病人年齡:5月至31歲

HIS File:
 Team members 28
 Came from US, Hong Kong, and Australia
 Orthopedic patients 6,
 age range 2 to 7 years
 Harelip & cleft palate patients 30, age range 5 months to 31 years

