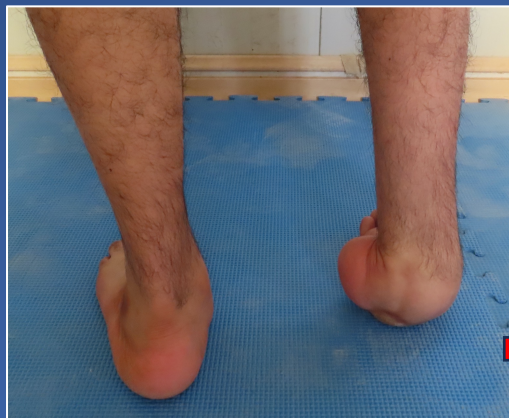
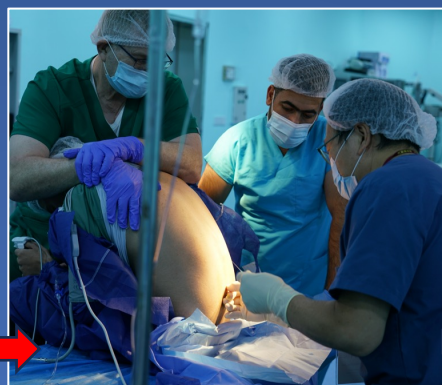
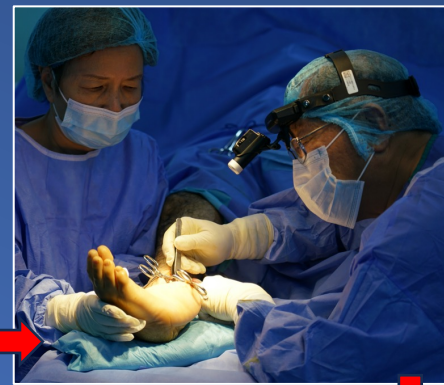

39歲雅茲迪難民，幼年患小兒麻痺引致右足變形，走路困難。 A 39-year-old Yazidi refugee. He had poliomyelitis in childhood leading to deformity of right foot with difficulty in walking.

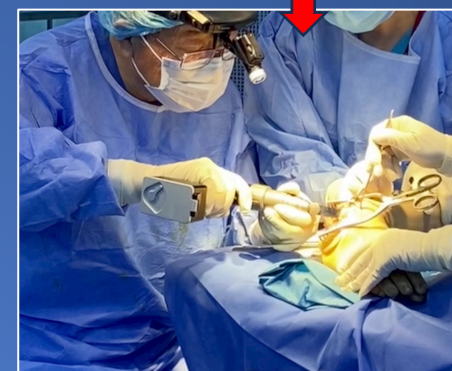


腰麻 Spinal anesthesia

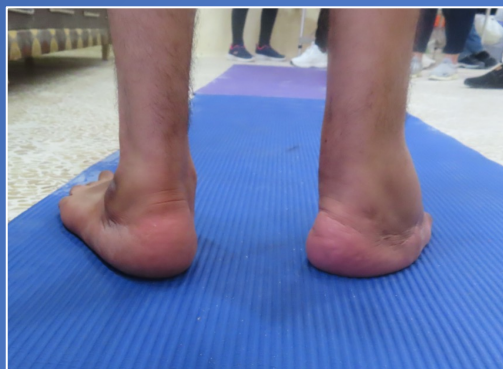

手術中  
Surgery in progress

## 轉化 Transformed



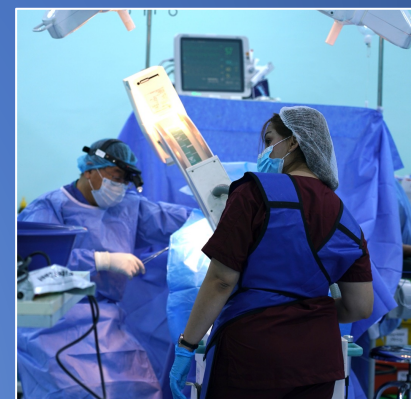截骨  
Osteotomy



手術後一年，右足已經矯正，步姿大致正常。 One year after surgery, the right foot is corrected. Gait close to normal.



手術後打了石膏  
After surgery in cast



拍X光 Taking x-ray

[www.his-foundation.org](http://www.his-foundation.org)  
[HISFound@aol.com](mailto:HISFound@aol.com)

