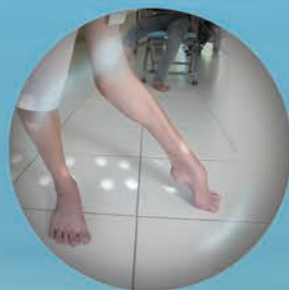

讓我走動

天鄰骨科見證

A Testimony of
HIS Foundation Orthopaedic
Services

Let Me Move



天鄰基金會
HIS FOUNDATION

編輯：劉漢杰醫生 Editor: James Lau, MD

以這書獻給我們的主耶穌，祂是我們的創造者和救主。這書亦是獻予我們工作不懈的義工和同工們，衷心感謝他們對病人的愛心照顧。

This book is dedicated to our Lord Jesus Christ who is our Creator and Savior. This book is also dedicated to our tireless volunteers and workers. Their passionate care for our patients is deeply appreciated.

改善患者的活動能力，
就是為他充權，
讓他發揮更大潛能，
並更充分地享受上主
所賜生活的美好。

劉漢杰醫生

*Improvement of the mobility of a
handicapped person is to empower him.
It allows him to maximize his potentials.
It also enables him to enjoy life
endowed by God more fully.*

James Lau, MD

目錄 Contents

P1	獻給	Dedication
P2	活動	Mobility
P3	目錄	Contents
P4-5	序	Preface
P6-22	頸部及上肢篇	Neck & Upper Limb Section
P23-41	髖關節及大腿篇	Hip & Thigh Section
P42-73	膝關節及小腿篇	Knee & Leg Section
P74-136	踝關節及腳部篇	Foot & Ankle Section
P137-182	多個肢體部位篇	Multiple Body Parts Section
P183-191	歷年骨科出隊紀錄	Record of Orthopaedic Missions
P192-219	輪椅篇	Wheelchair Section
P220	輪椅捐贈紀錄	Wheelchair Donations Record
P221-291	手術隊員見證篇	Surgical Team Members Testimonies Section
P292-338	手術隊員剪影篇 河南、雲南、青海、四川、 越南、馬達加斯加、 庫爾德斯坦	Surgical Team Members Photos Section Henan, Yunnan, Qinghai, Sichuan, Vietnam, Madagascar, Kurdistan
P339-347	病人感言篇	Patients' Words of Appreciation Section
P348-351	後記	Epilogue

序

神創造人最初的美意，是讓人可以自由移動身體的不同部位，又可以走動。這樣，人可以充份發展他的潛能，也能夠享受生活的美好。

可惜，因為疾病和創傷的緣故，人的身體活動能力受阻，很多人不能隨意走動。我作為骨科醫生的一個責任，就是要讓病人恢復活動的能力。

在參加中國醫療事奉的初期，見到一位患小兒麻痺後遺症的女孩子，她下肢癱瘓，左側髖關節攣縮，不能站立，走路時有如狗一般，用四肢爬行，而且因為左下肢無力，只能拖着來走，就如一條跛腿的狗。我看後非常心痛，因為從未想到在現今醫學發達的世界，竟然有人殘疾到如斯情況。我內心起願，一定要盡力為這孩子治療，讓她可以站起來走路。

不少肢體活動有困難，或不良於行的病人，能夠通過手術治療而得到改善。我們親自見證到數以百計癱瘓的、殘疾的及癱腿的患者，能再次活動，重新行走，令他們生活的質素大大的改善，並且重拾生命的火花。

但是，不是每一位行動困難的病者，都有機會得到手術治療，或願意接受手術，所以，在骨科手術之外，要另尋途徑去幫助他們，輪椅捐贈成為一個有效的方案。

過去二十多年，美國及香港天鄰基金會，在骨科手術和輪椅捐贈方面，都做了大量的工作，令許多病人的活動能力大大提升，甚至恢復正常。本見證集收集

了許多真實的個案，及隊員的見證，讓大家更清楚了解這些事工。願神的名得到當得的榮耀！

劉漢杰醫生
美國天鄰基金會主席



Preface

In God's original design for humans, individuals can freely move different body parts and travel from place to place. This way, we can achieve our potential and fully enjoy life.

However, due to diseases and trauma, the mobility of the human body may become compromised. When this happens, people cannot move or travel so freely. My duty as an orthopaedic surgeon is to restore mobility to patients.

One time during the early year of medical services to China, I met a girl who suffered from post-poliomyelitis deformities. Her legs were paralyzed, and her left hip was contracted. She was not able to stand. She had to walk with all 4 limbs, like a dog. Since her left leg was very weak, she had to drag her leg along like a lame dog. I was in shock. I could not imagine in face of innovation and advancement of medicine, there was still patient so disabled. I decided that I would try my very best to treat her so that she can stand up and walk again.

Many patients with limited mobility show improvement after surgery. We witnessed hundreds of patients who were paralyzed, disabled, or lame begin to move again or walk once more. Their quality of living improved dramatically, and this change rekindled their hope in life.

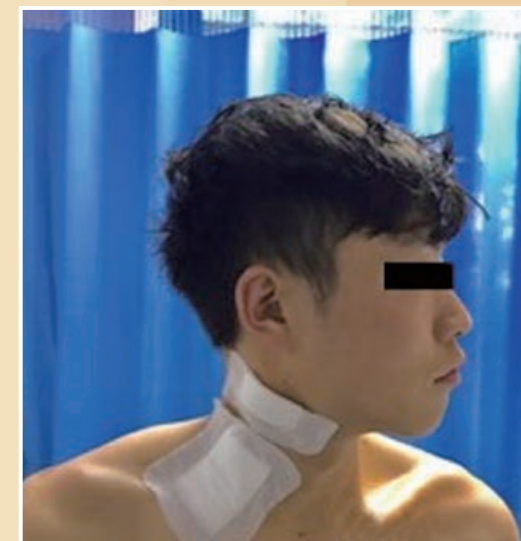
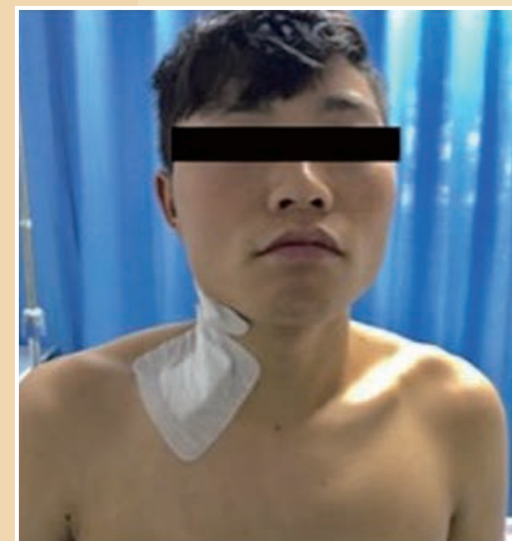
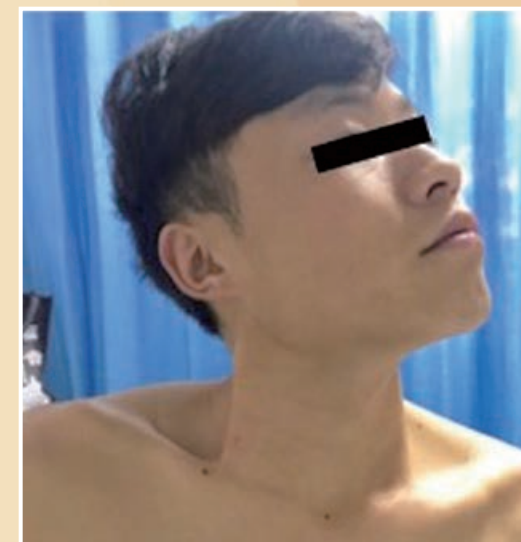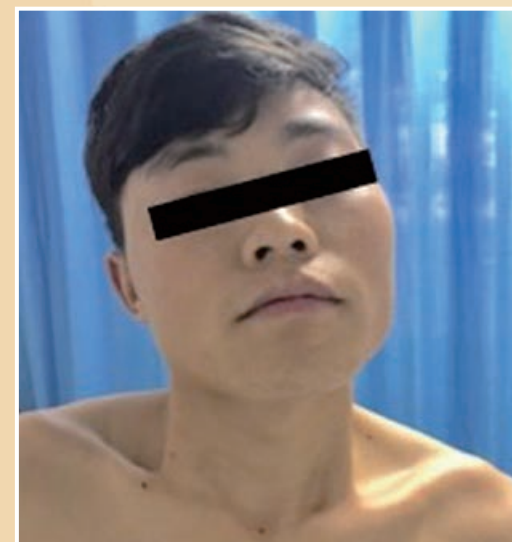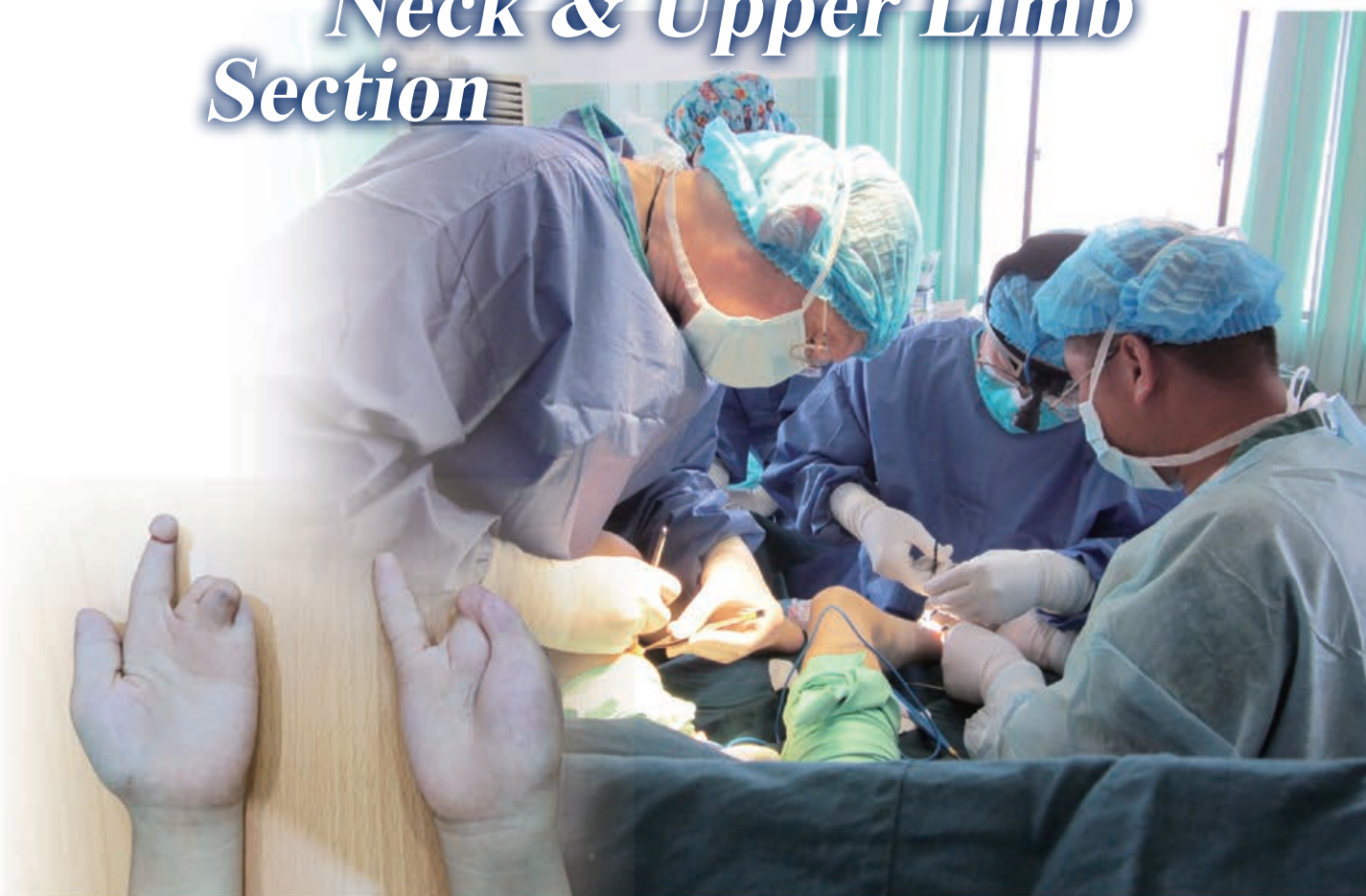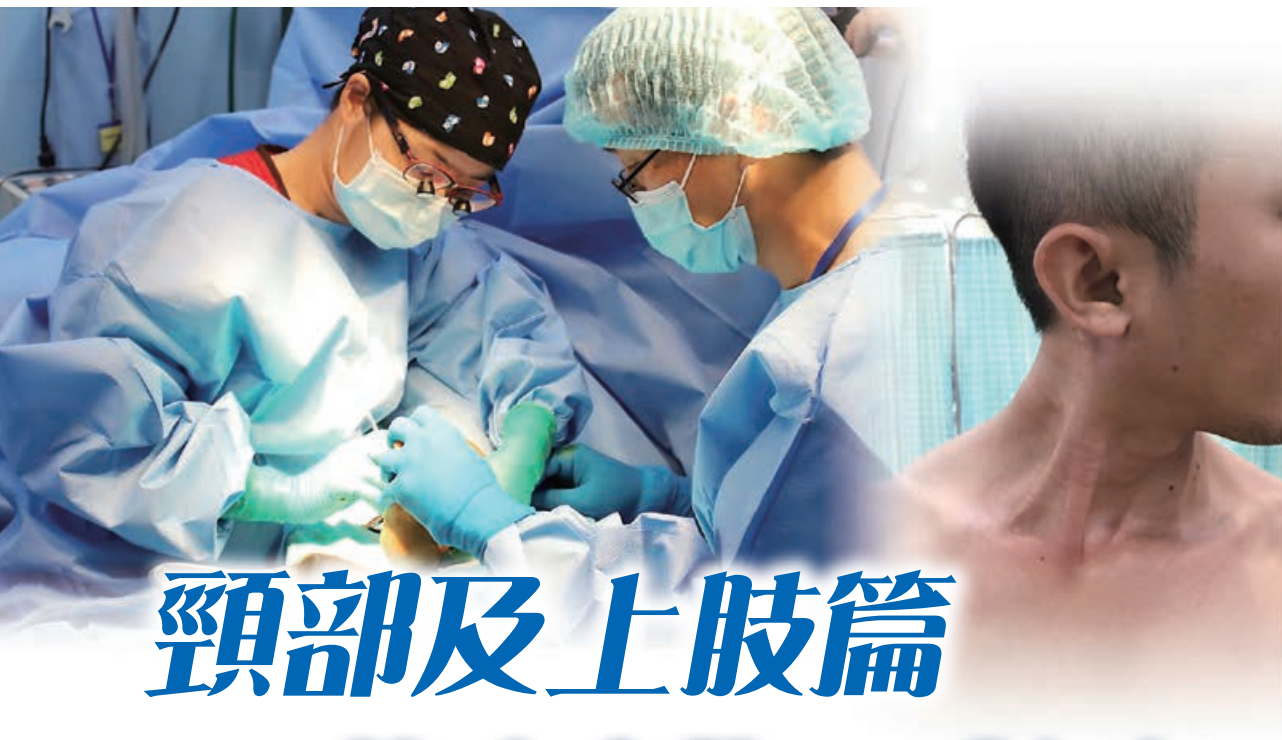However, not everyone who faces difficulties in walking has the opportunity for surgery. And some people may not want to have surgery. Therefore, a management method alternative to surgery is needed. Fortunately, wheelchair donation is an effective means to improve mobility.

For more than two decades, the HIS Foundation in the United States and Hong Kong has compiled an impressive record in providing orthopaedic surgeries and wheelchair donations. Many patients have regained mobility, and some have resumed normal life. So that readers can have a better understanding of these ministries, this book offers a collection of many real-life examples along with witnesses from our team members. May God's name be rightfully glorified!

James Lau, MD
Chairman, Board of Directors
HIS Foundation (USA)

頸部及上肢篇

Neck & Upper Limb Section



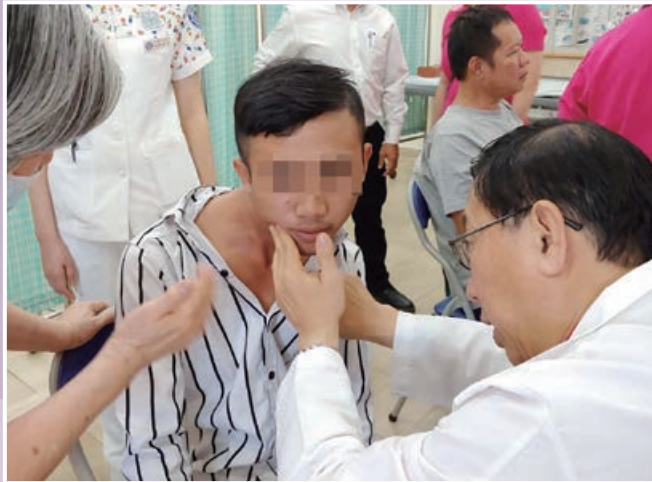先天肌肉性斜頸

Congenital Muscular Torticollis

四川瀘洲一位先天性斜頸病人，手術前（上圖）兩肩一高一低，頸部左旋轉有限。術後兩肩是同一高度，旋轉亦進步了。

A Sichuan patient with congenital muscular torticollis. Before the surgery (upper photos), the shoulders were uneven and the rotation of the neck to the left was limited. After surgery, the shoulders are even and rotation much improved.

N 001



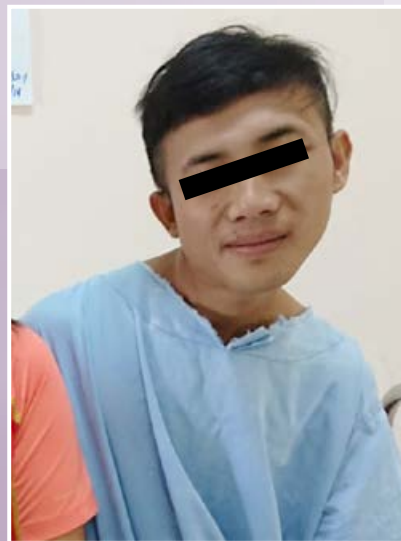先天肌肉性斜頸 Congenital Muscular Torticollis

一位越南先天性斜頸病人接受檢查。

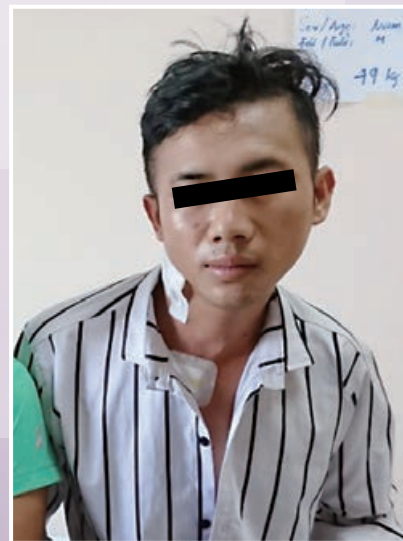A Vietnamese patient with congenital torticollis was being examined.

比較手術前和手術後之圖片，可以見到雙肩部不對稱之傾斜已經改善，雙眼的傾斜亦有進步。

Comparing the photos before and after surgery, the asymmetric tilting of the shoulders were partially corrected. The abnormal tilting of the eyes also improved.

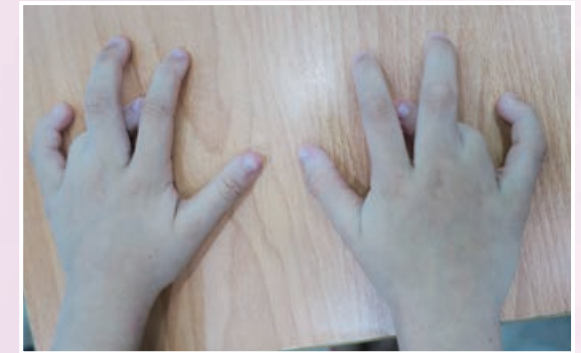
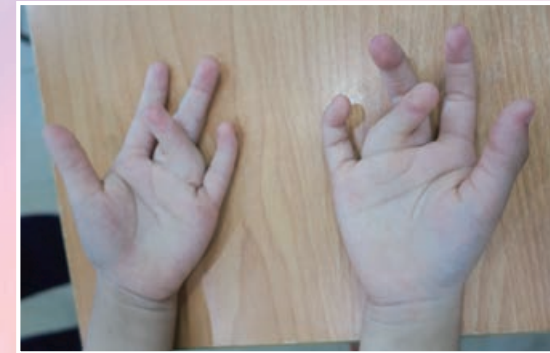

手術前 Before Surgery



手術後 After Surgery

N 002



先天性手指骨變形


Congenital Anomaly of Finger Phalanges

X 光顯示手指骨先天性變形。

X-ray shows anomalies in the finger bones.

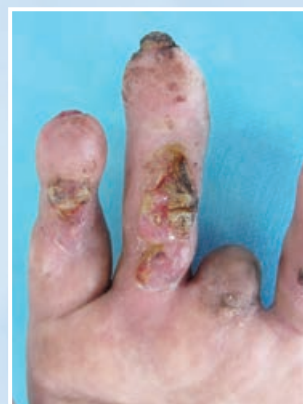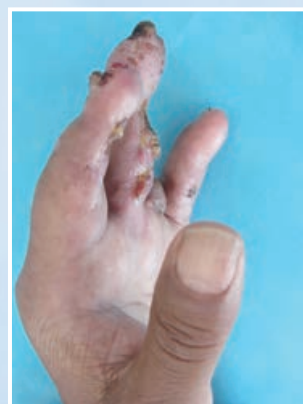
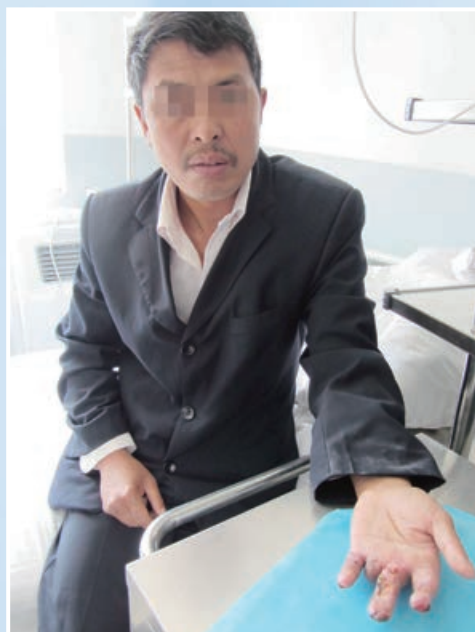一位越南女孩患有先天性手指骨畸形，導致雙側環指向外。右側手指經過截骨手術後已獲矯正。

A Vietnamese girl had congenital deformity of the finger bones leading to deviation of ring fingers. The right finger is corrected after osteotomy.



右手手指手術後位置已獲矯正。 After surgery on the right ring finger.

UL 001

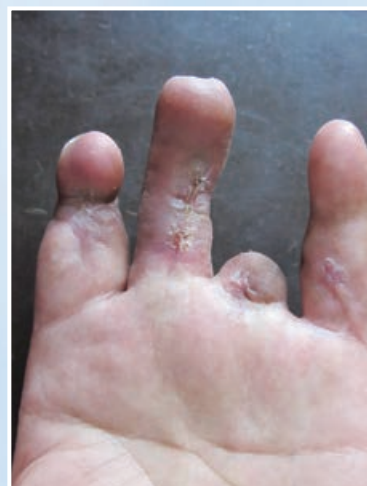

手指創傷後感染

Post-traumatic Fingers Infection

一位 40 歲的工人，一年多前，因為嚴重工傷引致手指截斷，有兩隻手指受到感染，傷口長久不能癒合，經過多次清創手術後，傷口逐漸癒合。

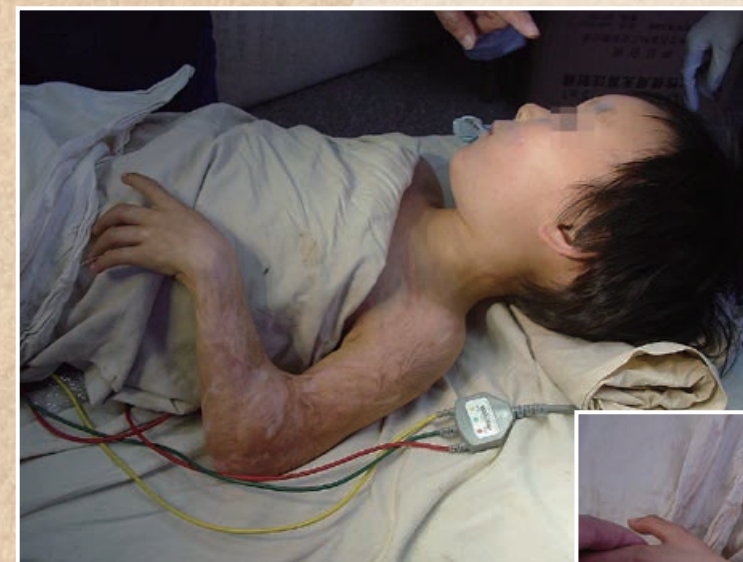A 40-year-old worker had an industrial accident over a year ago. It led to amputation of fingers. Two finger wounds remained infected and open. After multiple debridement, the wounds gradually healed.



手術後兩個月，病人帶著喜悅的心情回來覆診，因為傷口都已經癒合了。

Two months after surgeries, patient returned for follow up. He had a happy smile on his face because the finger wounds finally healed.

UL 002

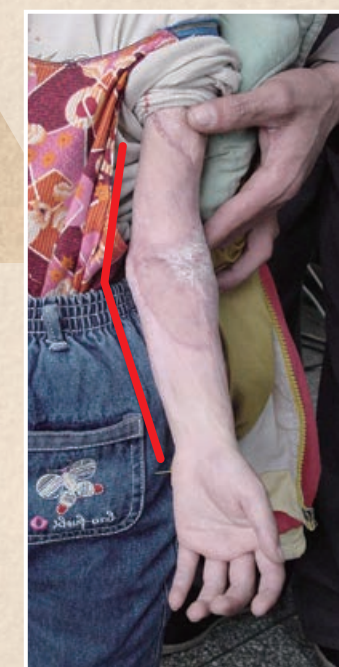
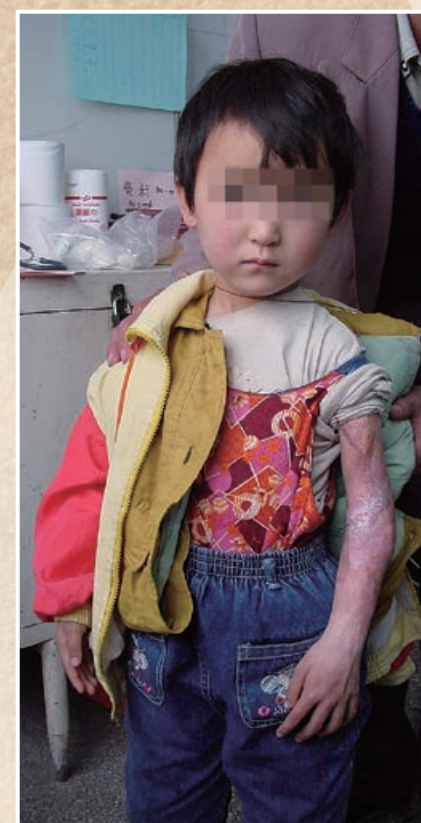
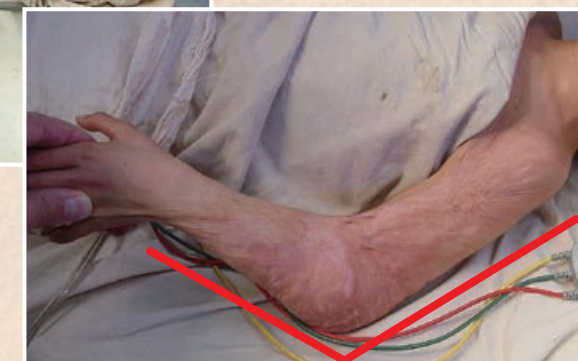燒傷疤痕、左肘關節攣縮

Burn Scars, Contracture Left Elbow

手術前左肘只能夠伸展約 100 度。

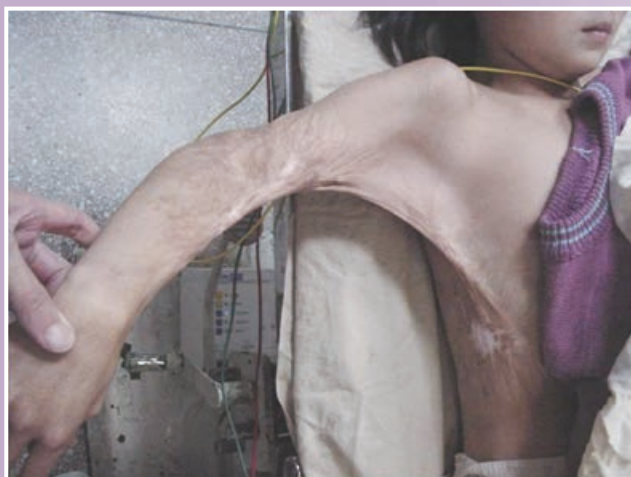Before surgery the left elbow could extend to about 100 degrees



手術後三個月，左肘可伸展至 165 度。

Three months after surgery, the left elbow could extend to 165 degrees.

UL 003

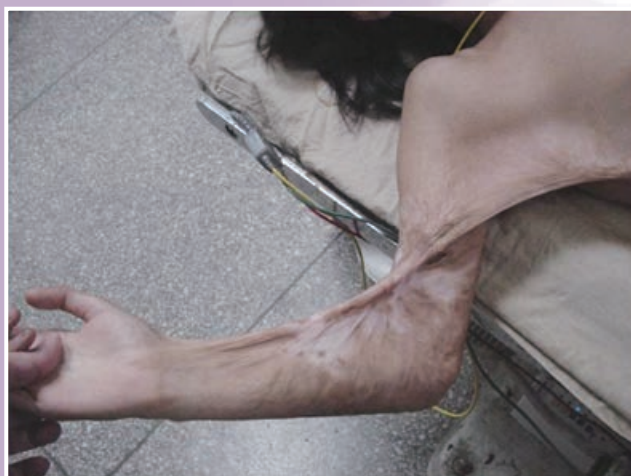

燒傷疤痕、 右肩及右肘關節攣縮

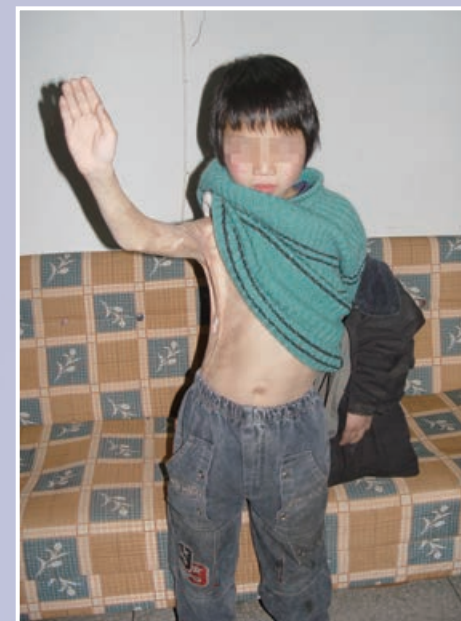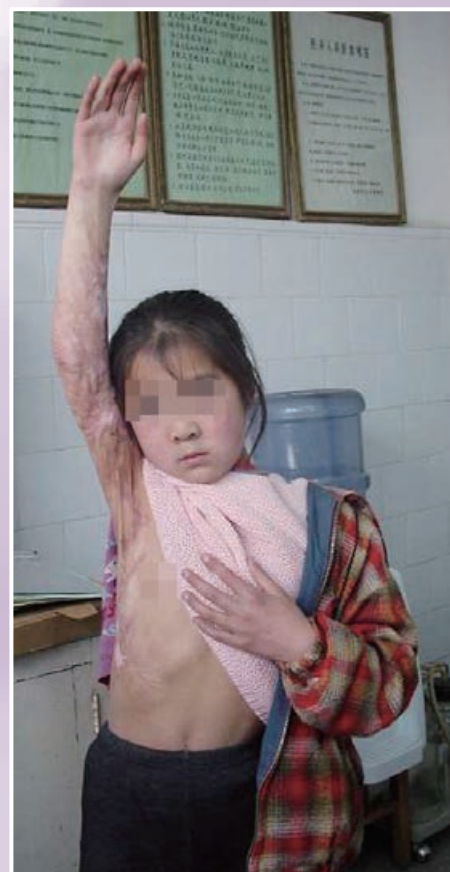Burn Scars,
Contracture Right
Shoulder &
Right Elbow

燒傷女童肩膀及肘部
不能伸展。

Burn scar
prevent extension of
shoulder and elbow.



手術後回復正常活動。
Regain normal
movement after release
of burn scars.



燒傷疤痕、右肩攣縮

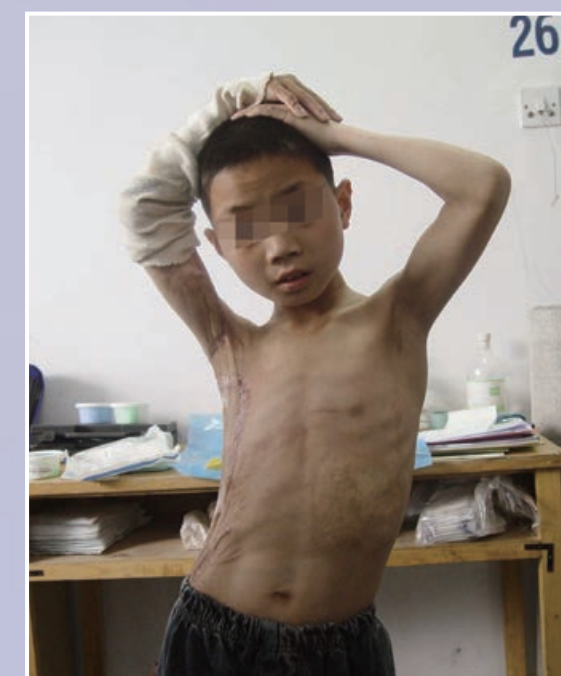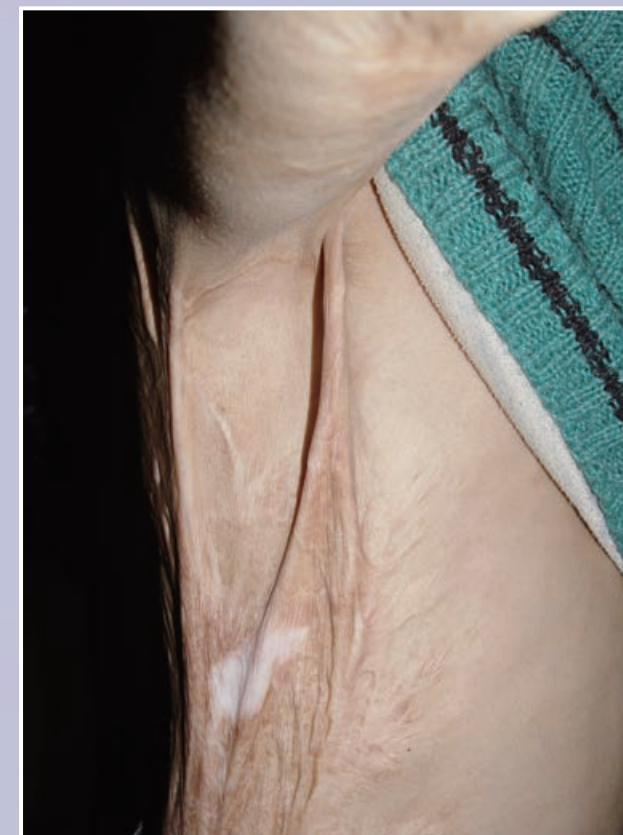Burn Scars,
Contracture Right
Shoulder

孩子燒傷後，疤痕令他不能高舉
右肩膀。

After burn, the scars prevent
the child from raising the
right shoulder.

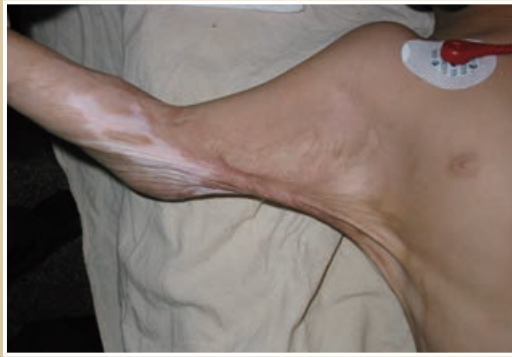手術把疤痕放鬆，右肩膀活動能力
增強，可以舉得更高。

After surgical release of the
scars, the range of movement
of the shoulder improved.
Patient can raise the right
shoulder higher.



UL 004

UL 005



燒傷疤痕、右肩攣縮

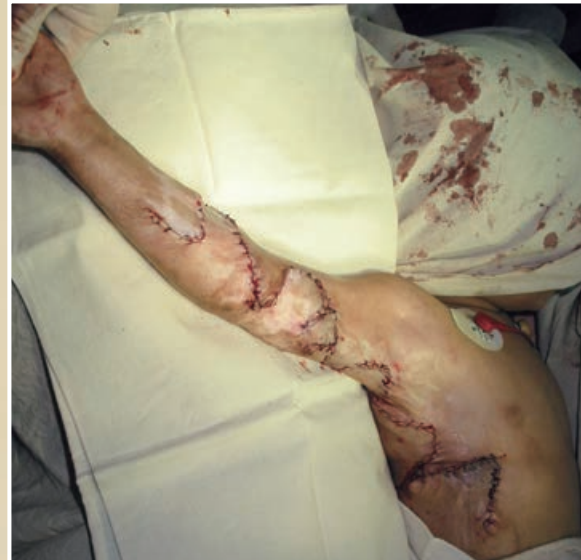Burn Scars,
Contracture Right Shoulder

手術開始前所拍照片。

Photograph taken before the start of operation.

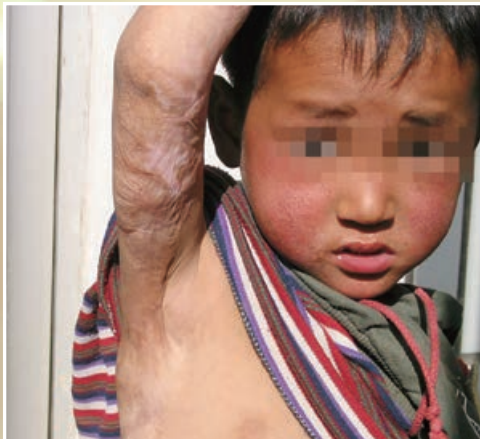一位河南的小童，燒傷後疤痕令右側肩膀及手肘不能自由活動。

A child from Henan. Burn scars limit movement of the right shoulder and elbow.



手術完成後所拍照片

Photograph taken after the operation.



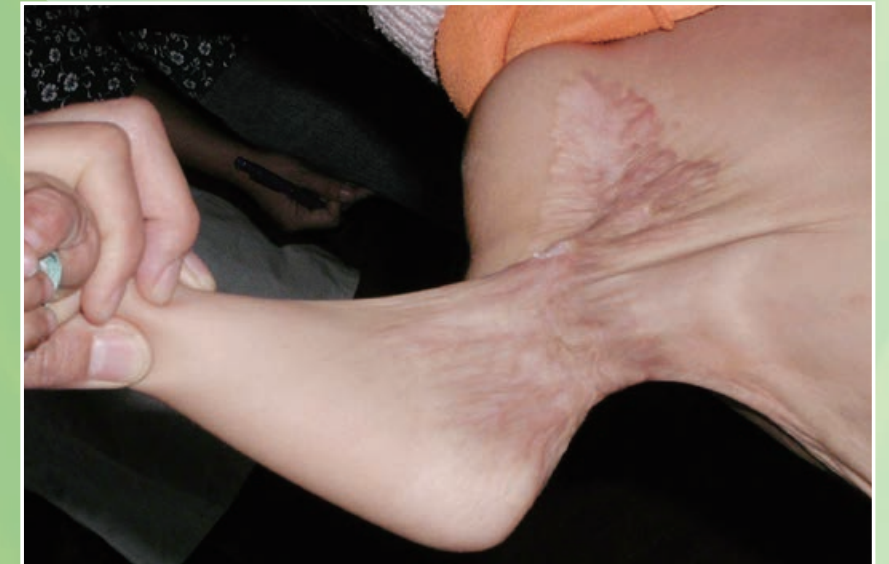一年後覆診，肩膀及手肘活動能力大大改善。

One year follow up photographs showing great improvement in the movement of the shoulder and the elbow.

UL 006

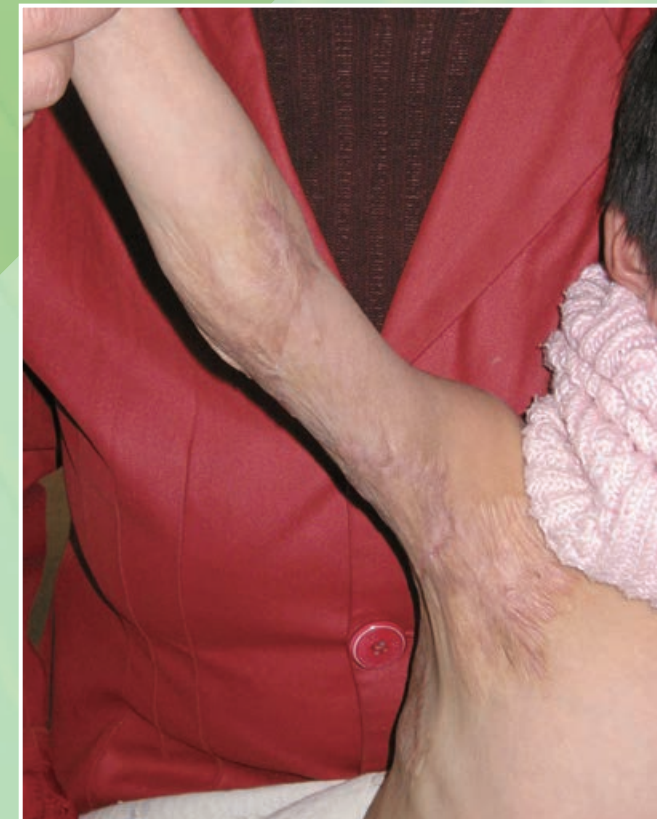燒傷疤痕、右肩及右肘關節攣縮

Burn Scars, Contracture Right Shoulder &
Right Elbow



燒傷後之疤痕嚴重影響右上肢的活動。

Severe burn scars prevent normal movement of right upper limb.



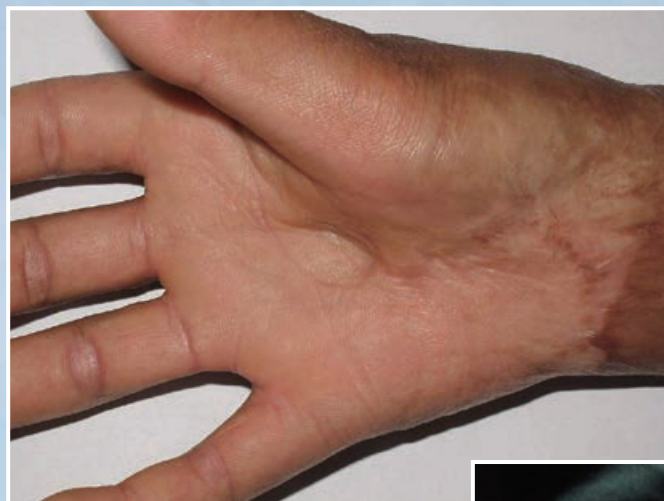疤痕用手術鬆解後，上肢恢復正常活動。

The movement of the right upper limb was restored to normal after release of burn scars.

UL 007

右手掌燒傷疤痕

Burn Scars Right Palm

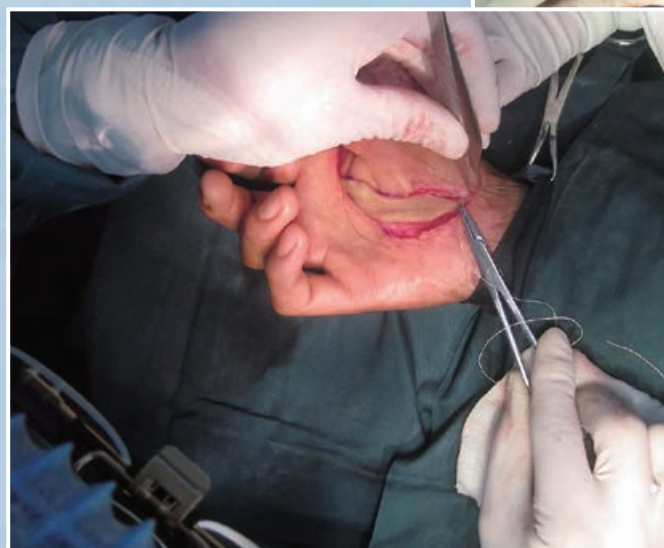
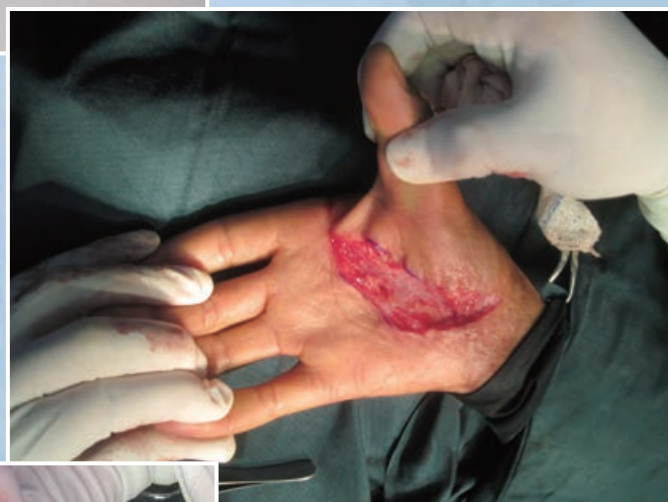
25 歲男子燒傷後手掌疤痕，令手掌不能完全張開。

25-year-old male with contracture of right hand after burn. Patient was unable to fully open the palm.

疤痕放鬆後手掌能够張開。

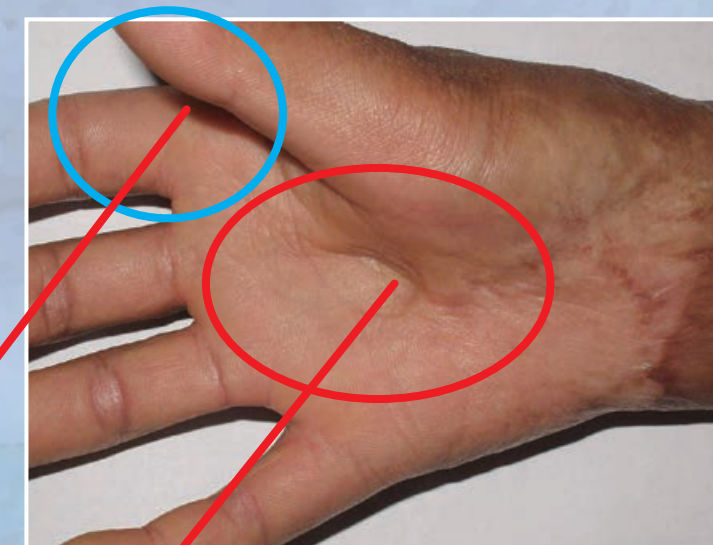
The palm could be opened after release of scar.



植上新皮。

Transplant of new skin.

手術前
Before Surgery



大姆指張得更開。
The thumb can open more widely.

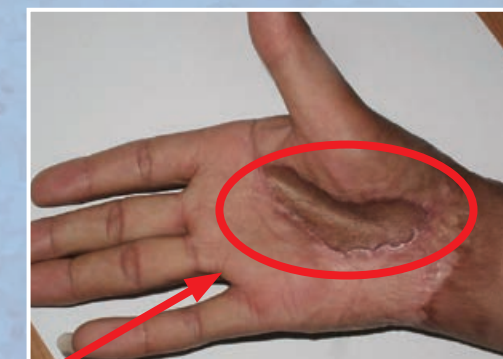

手術後，手掌可以打開，大姆指活動能力增強。

After surgery, the palm can be opened widely. Movement of the thumb increased.

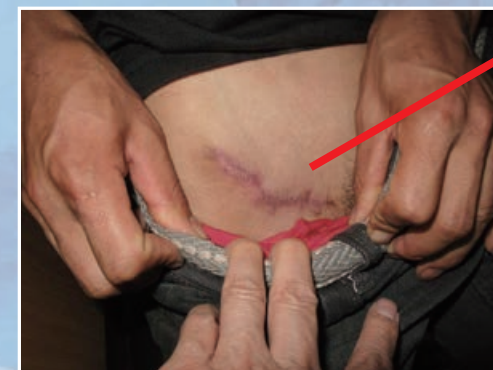手掌可以張得更開。

The palm can be opened more widely.



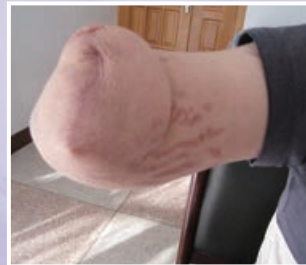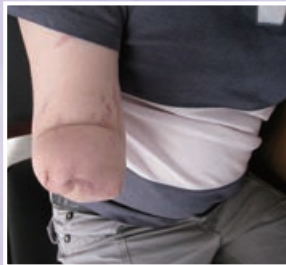手術後
After Surgery

右腹股溝取皮的部位已經痊癒。
The right groin was the donor site for the skin graft. It was well healed.



UL 008

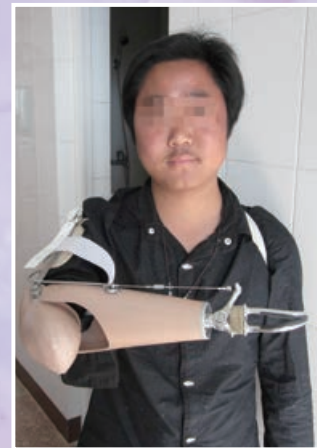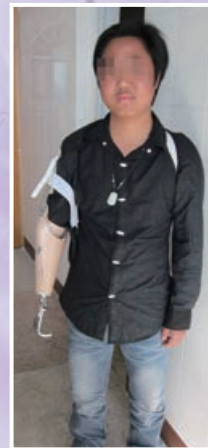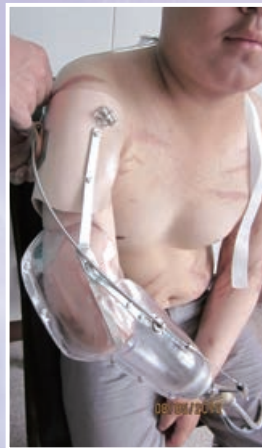創傷後右前臂截肢 Post-traumatic Below Elbow Amputation



大部分前臂失去，令裝配可活動的義肢困難。
A short amputation stump is a challenge for a functional prosthesis.

為病人專門造的義肢，利用肩膀肌肉控制義肢活動。

A custom-made prosthesis. Patient controls the movement of the prosthesis with his shoulder muscles.



一位在大理的農民因為意外失去右側前臂，天鄰為他做了義肢，讓他可以重拾部份失去的功能，令自理和工作更容易。

A farmer in Dali lost his right forearm from an accident. He was fitted with a prosthesis so that he can regain some lost functions. This made daily living and working easier.



在家幹活時義肢幫助很大。

The prosthesis is very helpful working at home.

UL 009

先天性左前臂截肢

Congenital Below Elbow Amputation



一位 20 歲的雅茲迪女士，患有先天性肘下截肢，因為肘關節餘下的骨骼很少，不能裝配有功能的義肢，但病人強烈要求安裝一件外觀好的假肢，因為她在適婚年齡，殘疾人士很難找到結婚對象。

A 20-year-old Yazidi lady with congenital below elbow amputation. Due to the paucity of bone stock, it was not possible to fit a functional prosthesis. However, patient strongly requested a cosmetic prosthesis. It was because she was at a marriage age and handicapped people had difficulty finding mates.



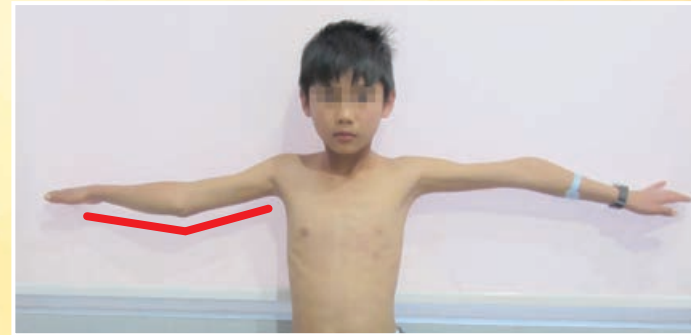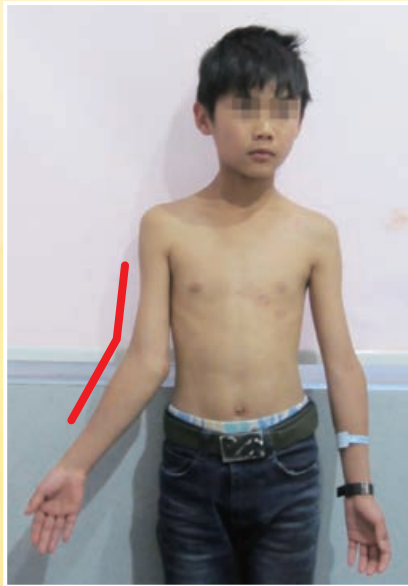病人對假肢的外觀和顏色很滿意。

Patient was very please with the appearance and color of the prosthesis.

UL 010

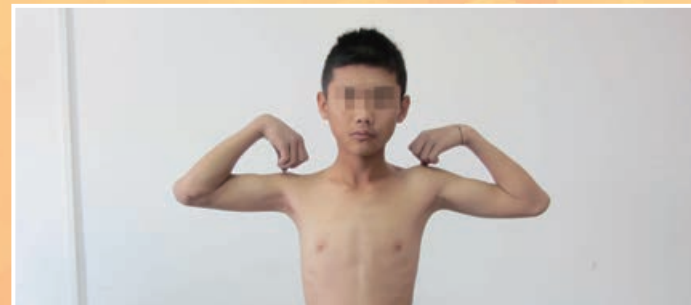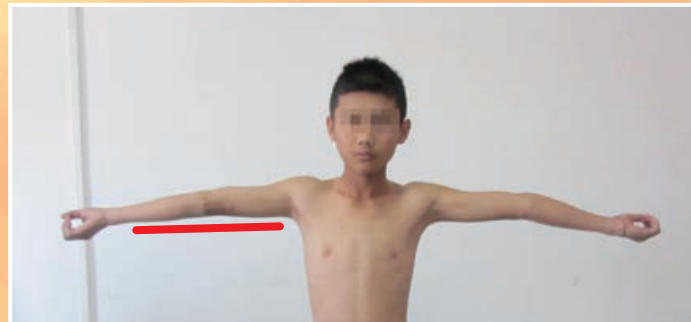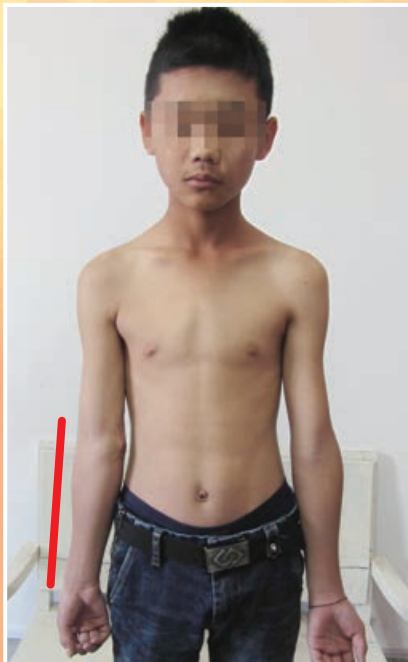創傷後右側關節肘外翻

Post-Traumatic Right cubitus valgus



病人右側肱骨髁上骨折後，出現外翻和不能完全伸展的情況。

After supracondylar fracture of right humerus, the elbow showed valgus deformity and limited extension.



手術後，右側肘關節已經恢復正常位置和活動。

After surgery, the alignment and movement of right elbow was restored.

UL 011

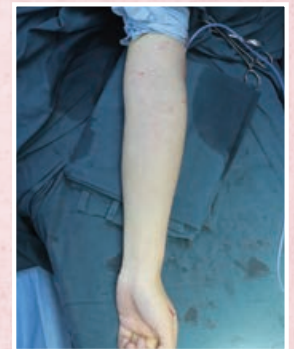

創傷後左側肘關節內翻

Post-traumatic Left Cubitus Varus

19 歲在四川瀘州的大學女生，因肱骨骨折引致左側肘關節內翻，截骨手術後肘部位置恢復正常。

A 19-year-old college student from Luzhou, Sichuan developed cubitus varus after fracture humerus. The alignment was restored to normal after osteotomy.



手術相片顯示畸形已經矯正。

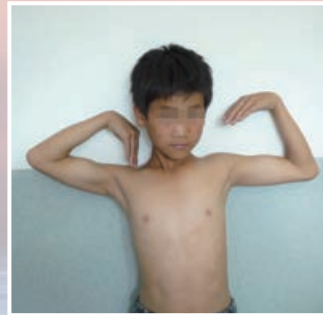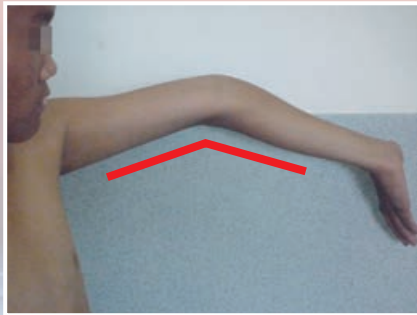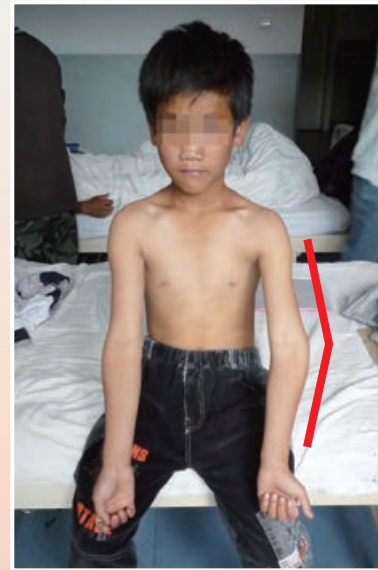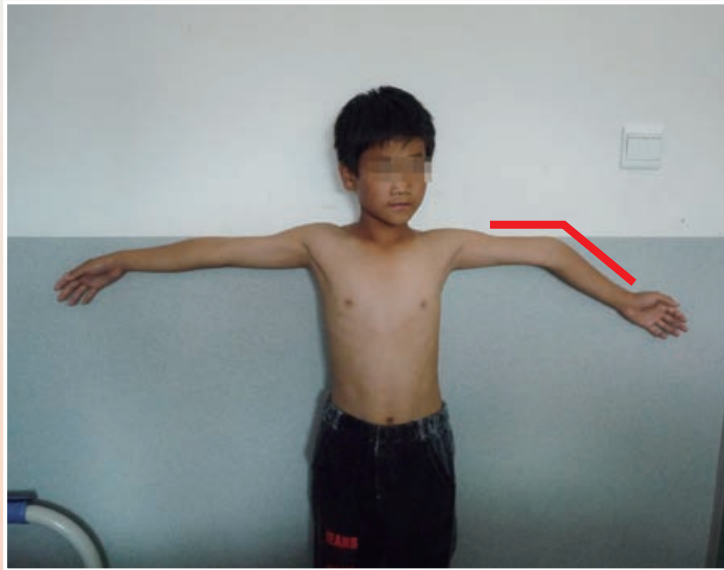Intraoperative photo showing normal alignment of the elbow.



兩年後患者寄來近照，她現在是一位舞蹈老師，她的左肘位置及功能都正常。

2 years later, patient mailed us her photos. She is a dancing teacher. Her left elbow has normal alignment and function.

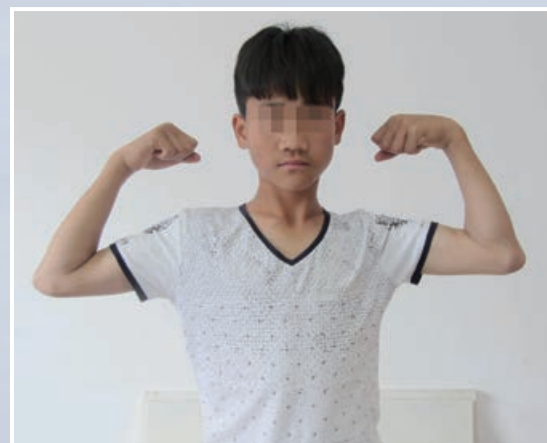UL 012



左側肘關節內翻及後翻
Left Cubitus Varus and
Recurvatum

男童左側肱骨骨折後變形，出現內翻及後翻。經過截骨手術後，畸形已經矯正了。

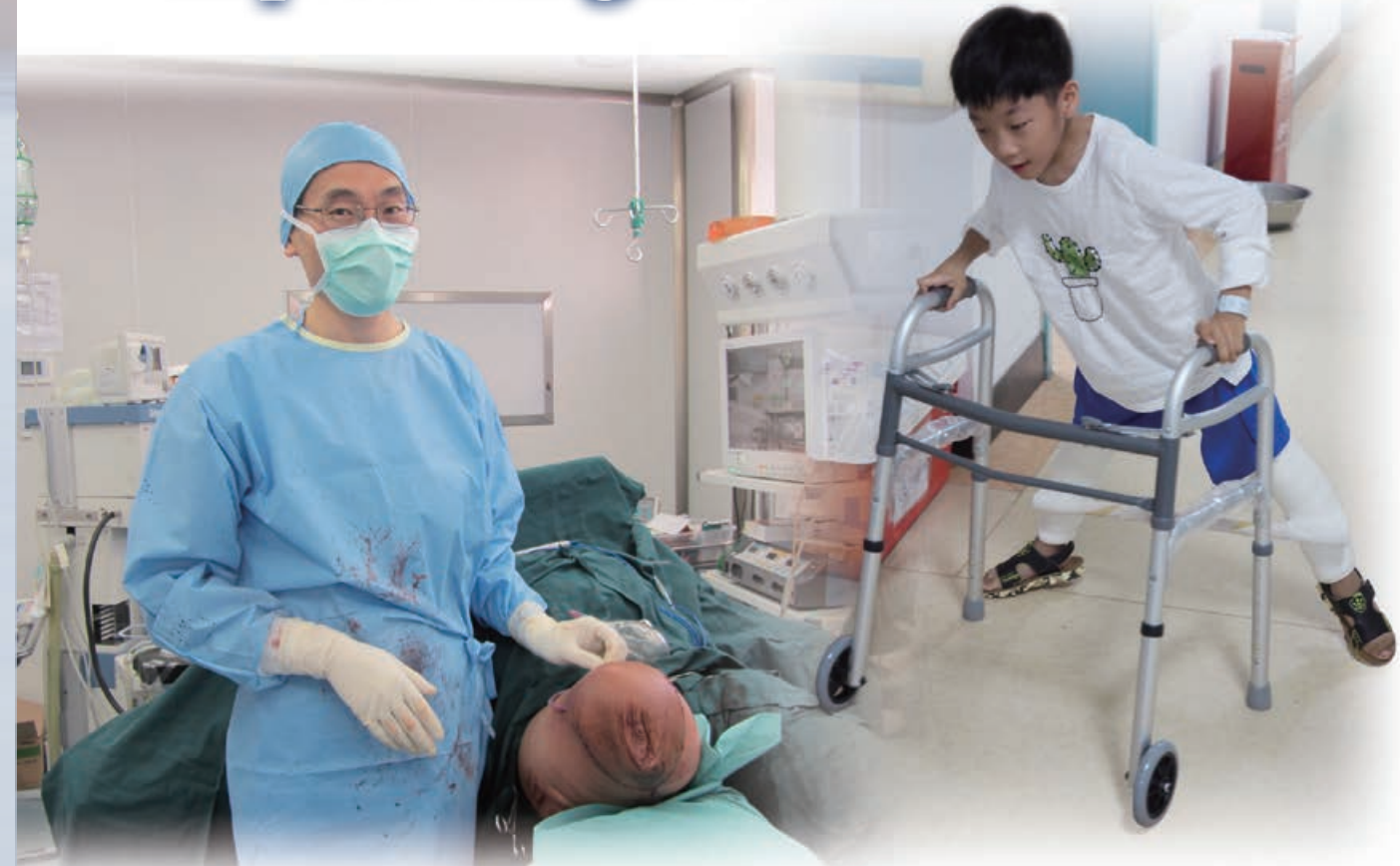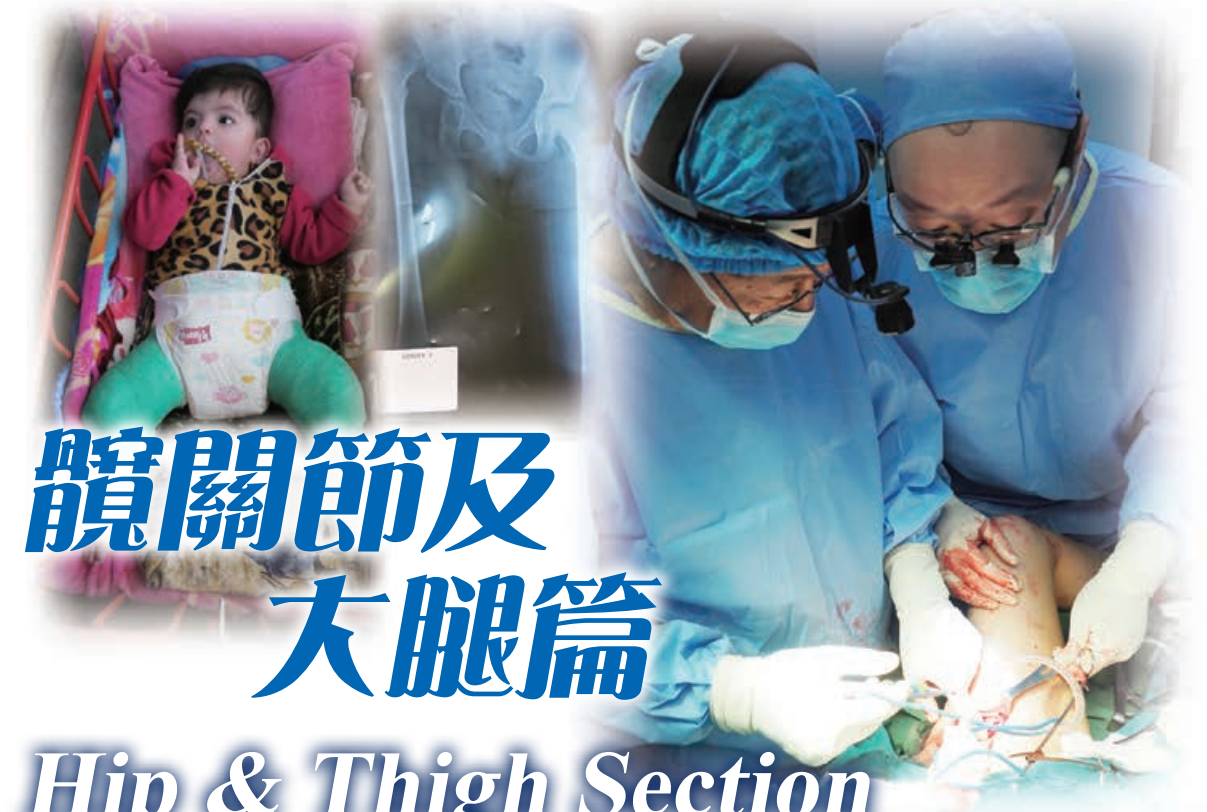A boy developed left cubitus varus and recurvatum deformity after elbow fracture. The deformities were corrected after osteotomy.

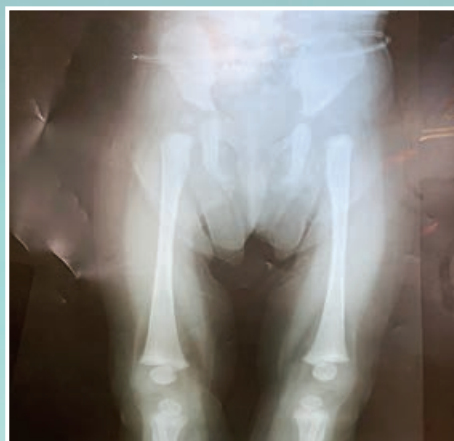

UL 013

髖關節及 大腿篇

Hip & Thigh Section





先天性左髖關節脫臼

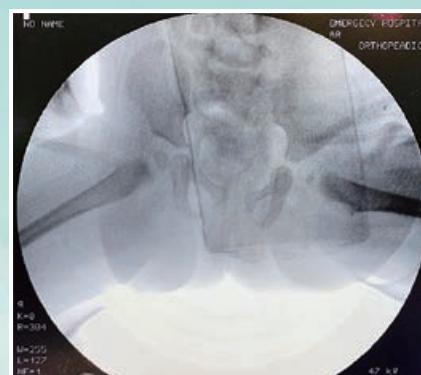Congenital Dislocation of Left Hip

一位八個月大的女嬰，患有先天性左側髖關節脫臼。X光顯示關節位置異常。

An 8-month-old female with congenital dislocation of the left hip. X-ray showed abnormal alignment of the hip.

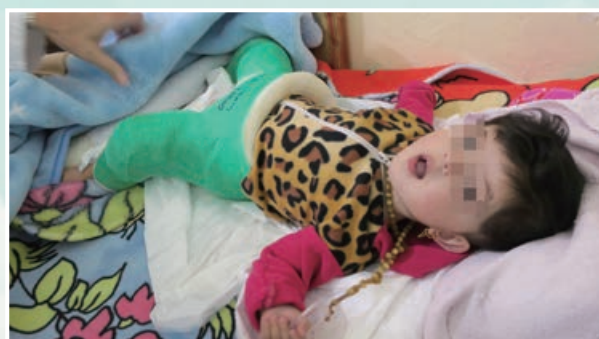在手術室關節復位後的X光透視顯示位置正常。

X-ray showed normal alignment of the left hip after close reduction in the operation room.



關節復位後用石膏固定兩個月。

The hip was immobilized with plaster for two months after close reduction.



兩個月後，髖關節穩定，位置正常。為避免再次脫臼，配上了支具，幾個月後，關節穩固，便停止使用支具。

A few months later, the hip joint was stable. The brace was discontinued.

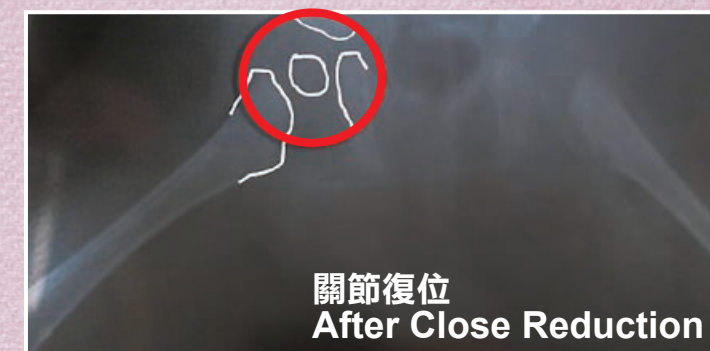

先天性右髖關節脫臼

Congenital Dislocation of Right Hip



髖關節脫臼
Dislocation of Right hip



關節復位
After Close Reduction



先天性髖關節脫臼在雅茲迪人中非常普遍，這4個月大的女嬰診斷有右髖關節脫臼，復位後配上支具。

Congenital dislocation of hip is very common among the Yizidis. This 4-month-old baby girl was diagnosed to have dislocation of the right hip. After closed reduction, the baby was fitted with a brace.

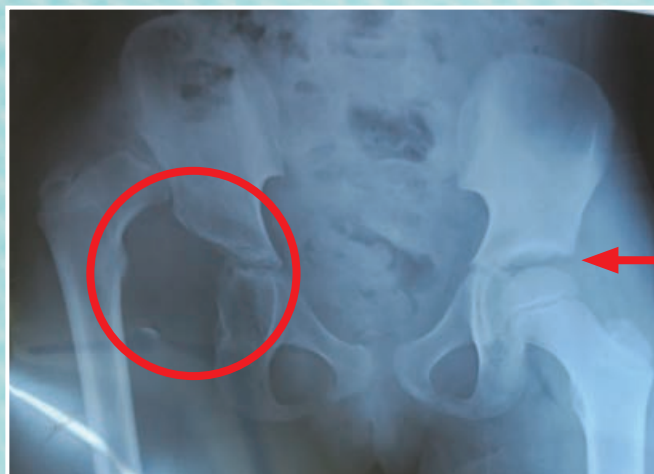H 001

H 002

先天性右髖關節脫臼

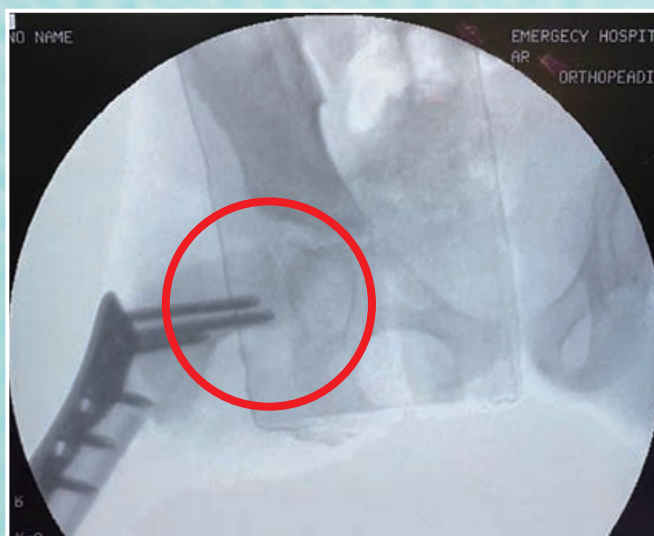Congenital Dislocation of Right Hip

股骨位置太高
The femur is dislocated superiorly



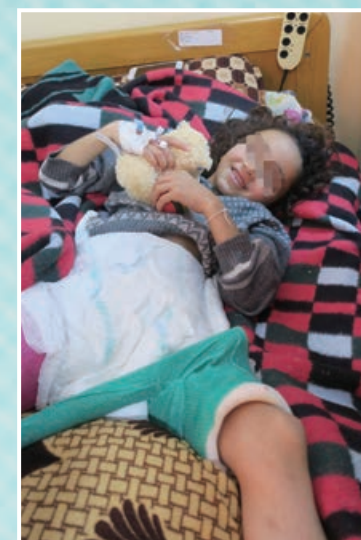正常髖關節位置
Normal alignment of the hip

股骨恢復正常位置
The femur is reduced to its normal position



一位 6 歲的雅茲迪女童，右側髖關節脫臼，走路一拐一拐的。經過復位及截骨手術後，髖關節回復正常位置，髖關節活動正常，走路正常，

A 6-year-old Yazidi girl with congenital dislocation of the right hip. She walked with a limp. After open reduction and osteotomy, the hip was reduced. The alignment and movement of the hip is normal. The gait is normal.



手術後髖關節位置用石膏固定（左圖）兩個月，然後配上支具（下圖）。手術後 9 個月，患者的右側髖關節穩固，她能夠輕鬆地蹲下，表示髖關節及膝關節活動能力良好，她走路姿勢正常。

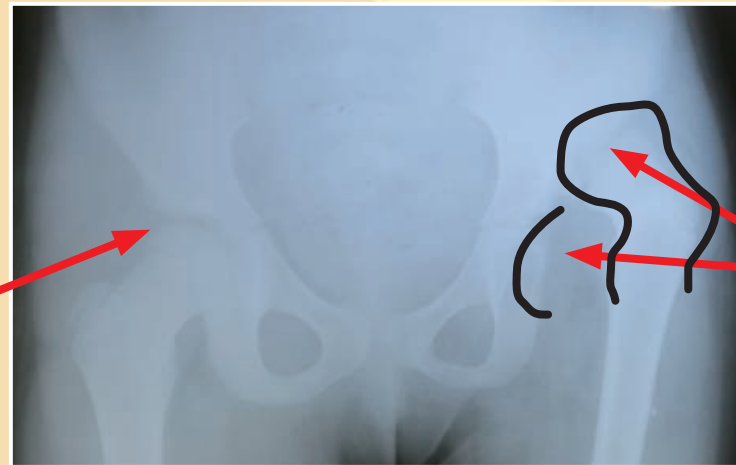After surgery, the right hip was immobilized with a hip spica (left). Two months later, patient was fitted with a hip abduction brace (below). 9 months after the operation. Patient's right hip was stable. She was able to squat down fully meaning that the range of movement of the hips and knees were good. Her gait was normal.



H 003

先天性左髖關節脫臼 Congenital Dislocation of Left Hip

髖關節正常
位置
Normal
position of
hip

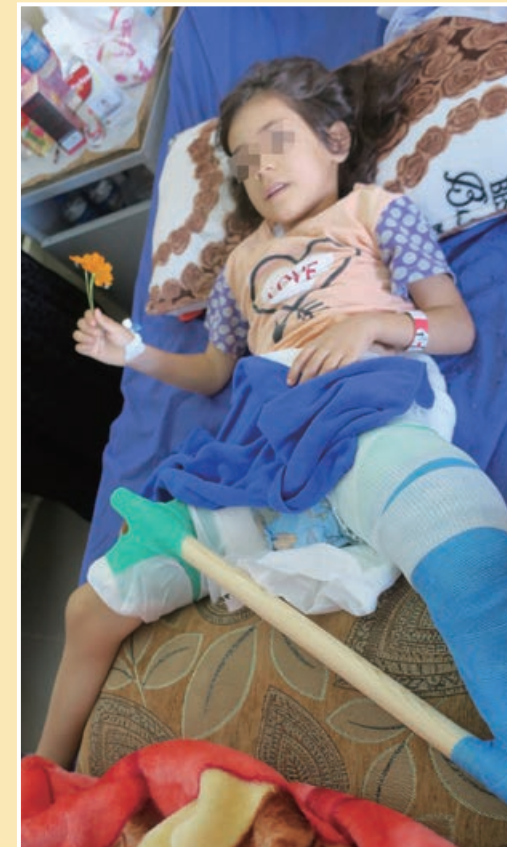

髖關節脫臼
Dislocation
of hip



髖關節復位
Reduction
of hip

一位 7 歲的雅茲迪女童，患先天性左側髖關節脫臼，接受了復位及截骨手術，髖關節位置正常。
A 7-year-old Yazidi girl with congenital dislocation of the left hip. After open reduction and osteotomy, the hip joint was reduced to normal alignment.



手術後打上石膏以固定髖關節位置。
After surgery, a hip spica cast was used to maintain the alignment of the hip.

手術後兩個月，配上支具。髖關節活動仍未正常，需要接受物理治療。

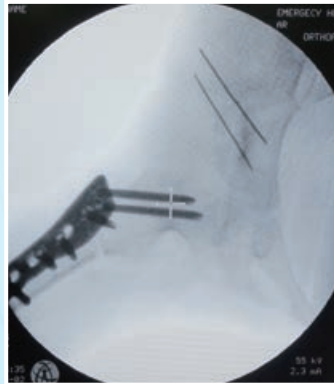
Patient was fitted a brace two months after surgery. The movement of the left hip was not yet normal, thus further physical therapy was needed.



H 004

先天性雙側髖關節脫臼

Congenital Dislocation of Both Hips



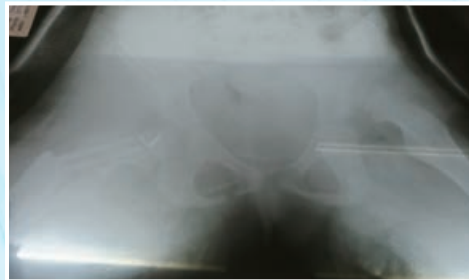手術中所拍 X 光，右髖關節已經復位。

Intraoperative x-ray showed reduction of right hip.

股骨正常位置。
Normal position of femur.



股骨脫位。
Dislocated femur.



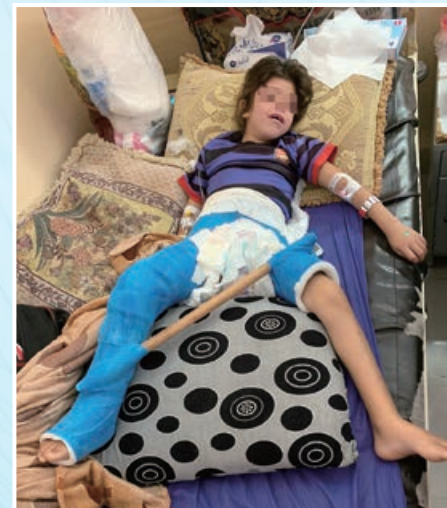手術後打了石膏的 X 光檢查，右髖關節位置正常。

Postoperative x-ray in cast showed normal alignment of right hip.



兩個月後，石膏拆除後，配上支具。病人在等候左側髖關節手術。

2 months later, the hip spica was removed. Patient was fitted with hip brace. She was waiting for surgery on the left hip.



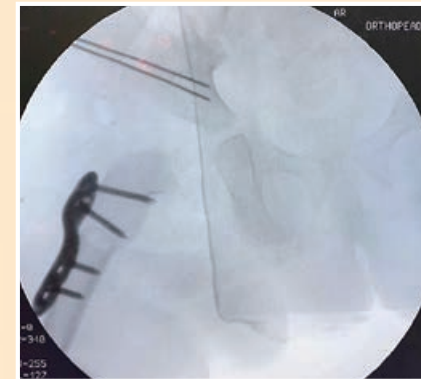
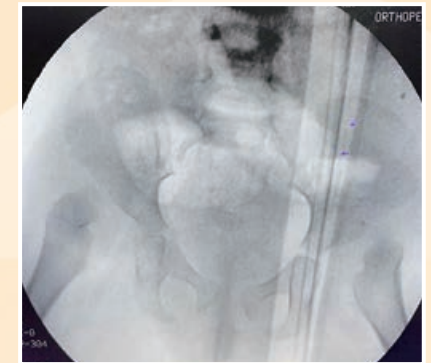
手術後打了石膏。
Hip spica after surgery.

先天性雙側髖關節脫臼

Congenital Dislocation of Both Hips

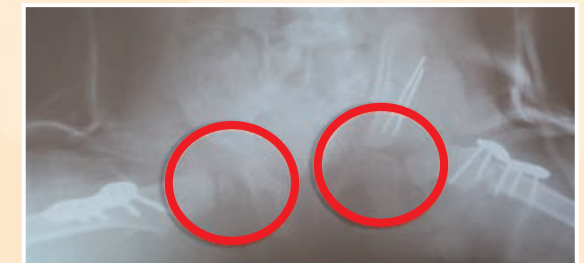
一位兩歲的雅茲迪女童，患有兩側先天性髖關節脫臼。

A 2-year-old Yazidi girl with bilateral congenital dislocation of hips.



第一次手術，右側髖關節復位。

The right hip was reduced after the first operation.




第二次手術，左側髖關節復位。

The left hip was reduced after the second operation.



手術後用石膏固定。
Hip spica cast after surgery.



石膏拆除後，配上支具。

Hip brace applied after removal of hip spica.

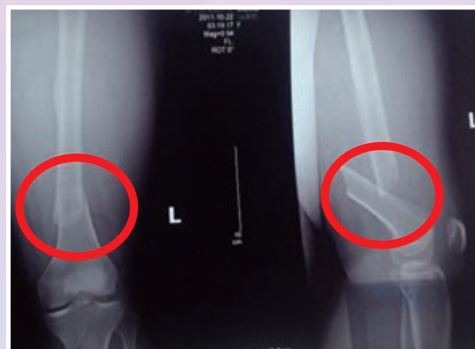H 005

H 006



左側股骨骨折不連合

Non-union Fracture
Shaft of Left Femur



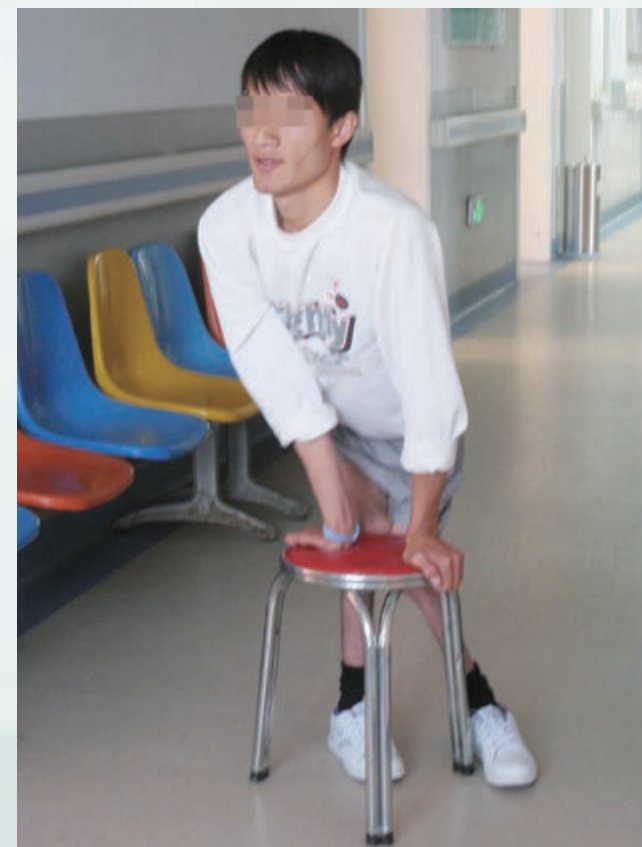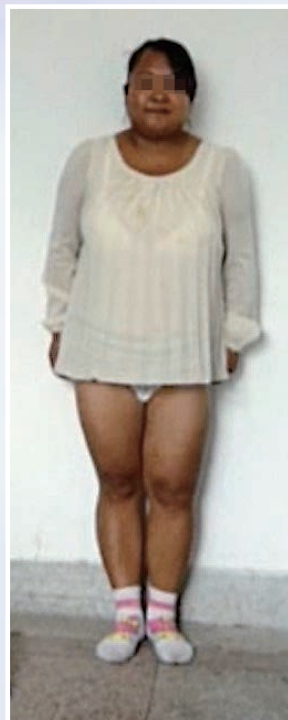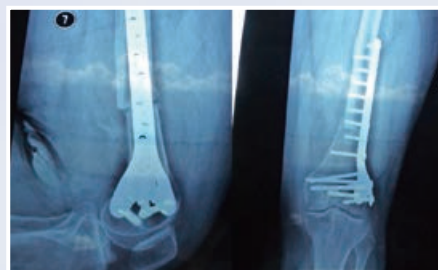
兩年前因為交通意外，一位 24 歲大理女士及他的丈夫都受了傷並且有骨折，家中只能負擔一個人的手術費，所以丈夫接受了手術。女士的股骨骨折一直未癒合，病人亦不能走路。

天鄰為患者做了內固定及植骨手術後，骨頭癒合得很順利，兩個多月後可以走路。

Two years ago, the 24-year-old lady and her husband were injured in a travel accident. Although both had fractures, the family only have enough money to pay for one surgery. So, the wife never had any operation and the fracture remained unhealed.

After internal fixation and bone graft surgery by HIS Foundation, the fracture healed smoothly. The patient was able to walk independently.

手術後 X 光片，顯示骨折用金屬板作內固定。
Postoperative x-ray showing the fracture was fixed by a metal plate.

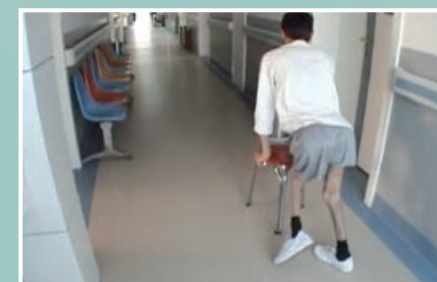
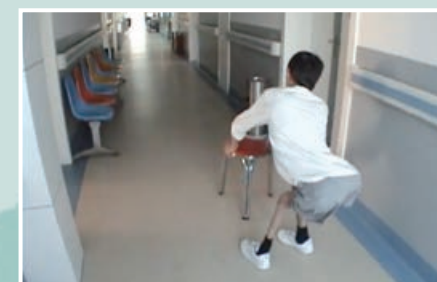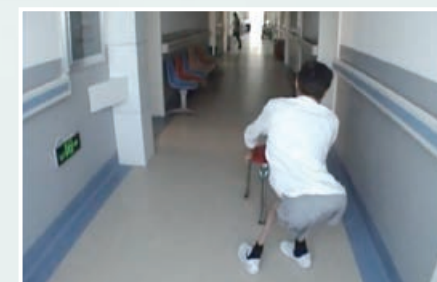

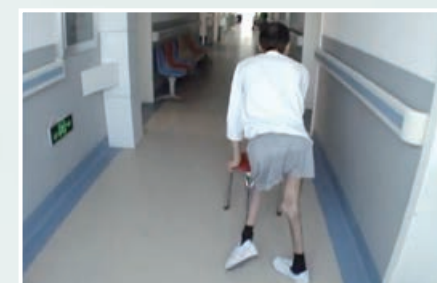
兒麻後遺、雙側髖關節攣縮

Post-poliomyelitis Deformity
Bilateral Hip Contracture

一位 19 歲的大理男子，因幼年患小兒麻痺，令下肢萎縮無力，雙側髖關節攣縮，不能伸直，不能站立。走路時蹲著身，用凳子支撐身體移動。

A 19-year-old man from Dali. He had poliomyelitis in early childhood leading to weakness and atrophy of both lower limbs. His hips had contracture and he was unable to stand upright. On walking, he had to lean forward and used a stool to support the body.



H 007

H 008



病人手術後可以站立，走路時用一支拐杖，能夠上、落梯階自如，生活可以自理。

After surgery patient is able to stand upright. He uses a crutch for walking and is able to go up and down stairs. He is independent in his daily living.

病人與天鄰義工合照。

Patient had photo with HIS Foundation volunteer.



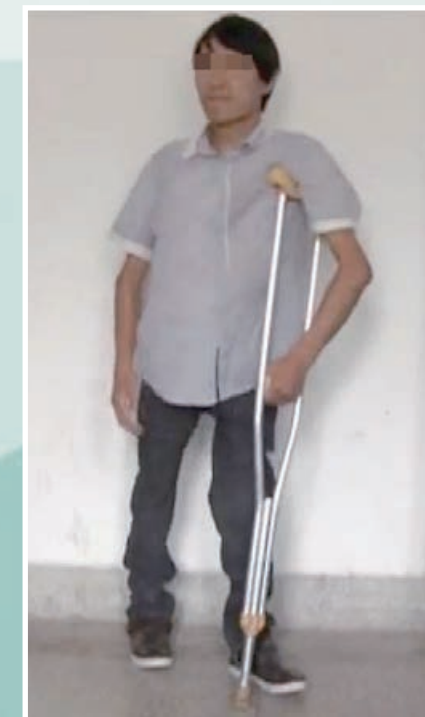手術後兩年，病人結了婚。

Two years after surgery, patient got married.



病人敘述：「手術以前，情況很不好。走路要靠凳子。凳子挪一下，身體就挪一下。生活基本不能自理。手術以後，現在可以直站而走，可以像正常人一樣，自己想去那裡，就去那裡，生活上得到很大的改善。是天鄰基金會給了我第二次的生命，讓我重燃生命的希望。」

Testimony by patient: "Before surgery, my condition was not good. I had to rely on a stool for walking. On each step, I moved the stool forward and followed with my body. I was unable to take care of myself. After surgery, I can walk upright. I can go wherever I want. There is a great improvement in my daily living. HIS Foundation gave me a second life and rekindled my hope in life."



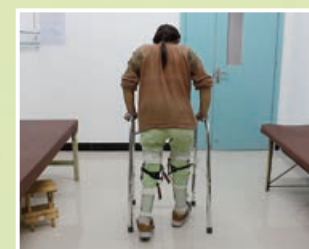
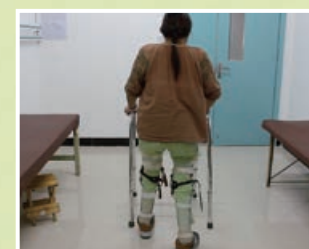
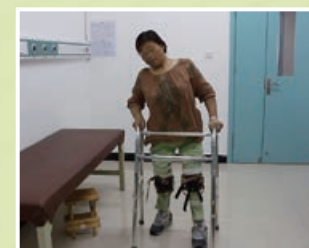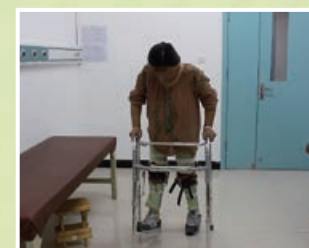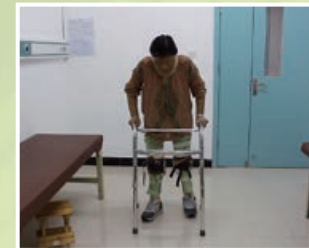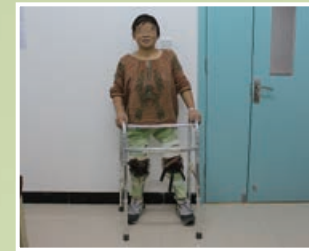H 008

小兒麻痺後遺症、雙側髖關節攣縮

Post-poliomyelitis Deformity Bilateral Hip Contracture

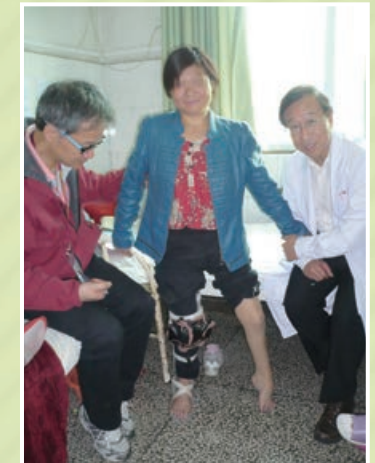一位 42 歲河南女士，因幼年患小兒麻痺症，令下肢癱瘓，雙髖關節攣縮，不能伸直，不能站立。病人有兩種前進的方法。第一，蹲下，用手捉著雙足，慢慢擺動身體向前移動（下圖）。第二，另一方法是坐在小板凳上，然後把下肢放在前面，蹲下，把小板凳送向前，坐上去，然後重複同樣動作（左圖）。

A 42-year-old lady from Henan. She had childhood poliomyelitis leading to paralysis of both lower limbs and contracture of hips. The hip joints could not be extended and thus she was unable to stand. There were two ways she could move the body forward. The first way, she squatted down. Use the hands to stabilize the feet and slowly swing her body from side to side in order to move forward (photos below). The second way was to sit on a small stool. Then use the hands to bring the legs forward. Then squatted down. Took the stool and moved it forward. Then sat on the stool and repeated the steps. (photos left side)



經過鬆解手術後，病人可以伸直髖關節，再配上長支具以支撐膝部，病人就可以用助行器步行。

After surgical releases, patient can extend her hips. Bilateral long leg calipers are used to stabilize the knees. Patient is then able to walk with a walking frame.



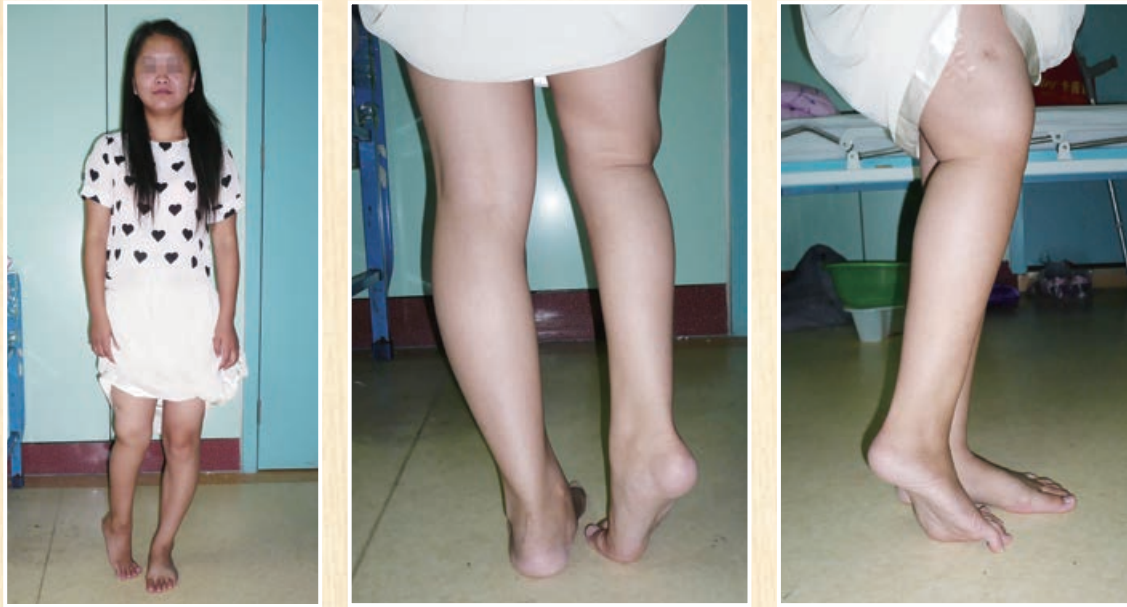病人見證：

你們提供的服務，如果不是我自己置身其中，別人跟我說，我是不會相信的，我不相信你們可以無私服務到這程度。當我來了之後，你們切切實實做的，有三年之久，令我對身邊的人，很多的事情，都放開很多。當我想到你們之後，覺得很多事都不那麼重要，重要的是學會與人為善。當一個人心中有這麼多不開心，但遇到了你們，心裡都會有感恩。我做手術的時候，我的兒子也在這裡，他現在 22 歲，他見到你們的服務之後，改變了很多，他對家人和身邊的人，所有的事，都非常的好。

Testimony by Patient:

If I had not experienced your services personally, I would never believe that it was so good, so selfless. For three years, what HIS Foundation did on me had transformed me. I now let go a lot of things. After I pondered upon your services, I realize that many things are no longer important. The most important thing is to be helpful and friendly to others. Even though I have been very unhappy, once I met you, I became very grateful. My son was here when I had surgery. He is now 22 years old. After observing the services provided, he changed a lot. He is very kind to the family and to people around him.

H 009



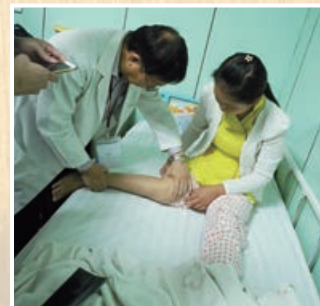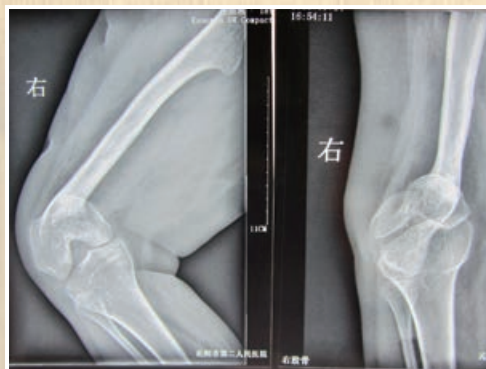右側股骨遠端骨折，連接不良、股骨內旋

Malunion of Fracture Right Distal Femur Internal Rotation of Right Femur

一位 19 歲的河南女子，幼時意外引致右股骨遠端骨折，復合時連接不良，令股骨內旋了，此外，因為生長骨骺受損，骨頭生長慢了很多，令下肢短了。

A 19-year-old lady from Henan. She had accident in childhood leading to fracture right distal femur. The bone healed with excessive internal rotation. The growth plate was damaged leading to shortening of the lower limb.

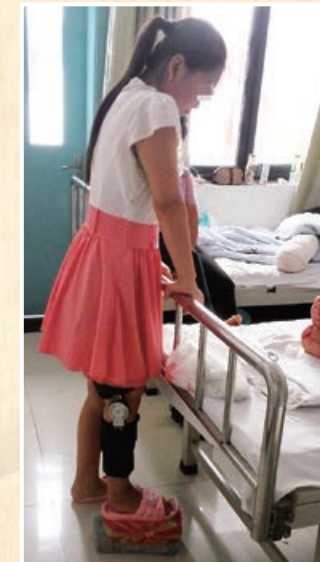手術前 X 光片顯示股骨遠端變形。
X-ray taken before surgery showed deformity of the distal femur.



手術前檢查。
Preoperative examination.

病人手術後打了石膏，與醫療隊隊員合照。

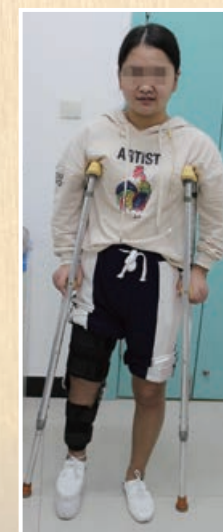
Patient was given a long leg cast after surgery. She had a photo taken with surgery team members.




病人作康復運動。
Patient was doing rehabilitation exercises.

病人接受了兩個手術，把股骨的內旋矯正，植上骨頭以幫助生長，日後配上支具以保護新生長好的股骨。為了矯正右腿太短的問題，鞋底加高了。康復初期，病人用一雙拐杖走路，後來就完全不用拐杖和支具了。

Patient had two operations. The malalignment of the femur was corrected. Bone graft was used to enhance healing. She was later fitted with a brace to protect the newly healed femur. A shoe raise was used to compensate for the limb shortening. In early rehabilitation period patient walked with a pair of crutches, later she is able to walk without any crutches and brace.



2017

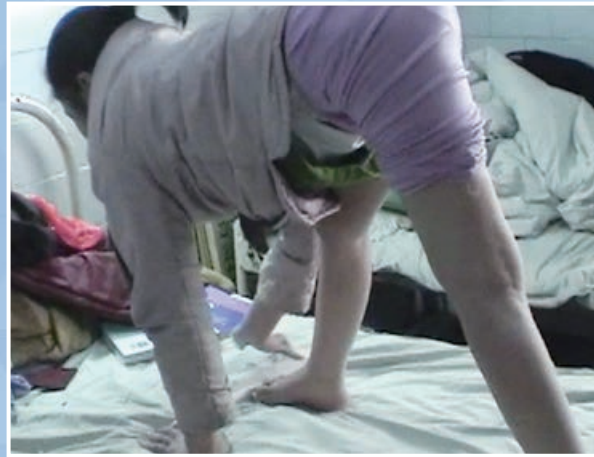

2018



加高了的鞋底。
Shoe raise.

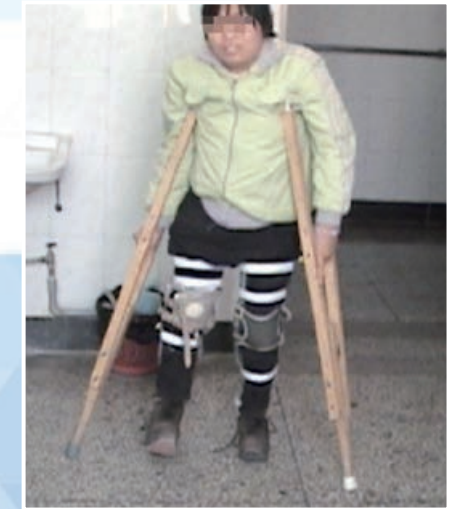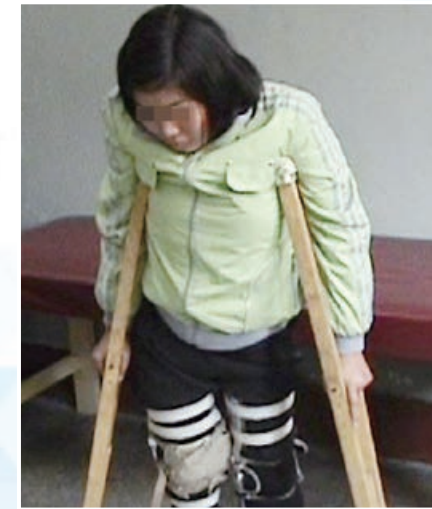H 010



小兒麻痺後遺症、右側髖關節攣縮 Post-poliomyelitis Deformity Right Hip Contracture

一位 17 河南少女，幼時患有小兒麻痺症，引致下肢無力，右側髖關節攣縮，不能站立，不能走路，只可以爬行。

A 17-year-old lady from Henan. She suffered from poliomyelitis during childhood leading to weakness in the lower limbs and contracture of the right hip. She was not able to stand or walk. She could only crawl.



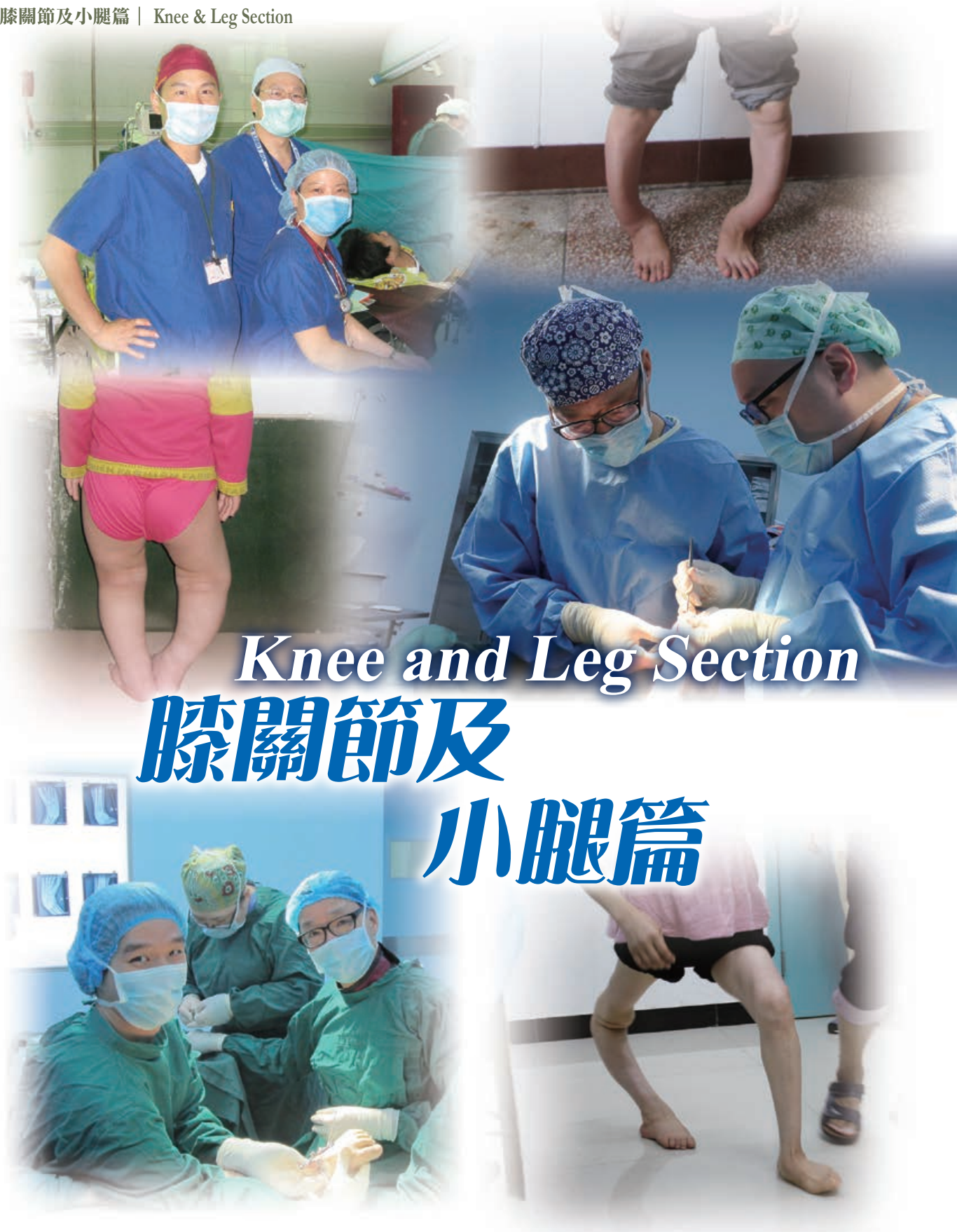手術把髖關節放鬆後，病者配上支具，拿著拐杖，可以站起來並且慢慢走步。

After surgical release of the right hip, patient was fitted with bilateral long leg braces. With crutches, patient was able to stand and walk slowly.



手術後 15 年，天鄰醫療隊隊員探訪病人，她依舊靠著支具和拐杖，能够走動。
HIS Foundation team members visited patient 15 years after surgery. Patient is able to stand and walk with crutches.

H 011



Knee and Leg Section 膝關節及 小腿篇

雙側 O 型腿 Bilateral Genu Varus



手術前 Before Surgery



手術後 After Surgery

一位河南的女童患有雙側 O 型腿，脛骨截骨手術後，下肢位置回復正常。

A girl in Henan was suffering from bilateral genu varus deformity. The alignment of the lower limbs is restored to normal after bilateral tibial osteotomy.

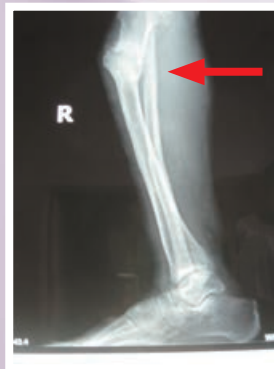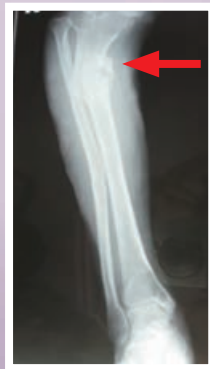K 001

神經纖維瘤 右脛骨骨折接合不全及變形

Fibrous Dysplasia Fracture Nonunion Right Tibia

一位 39 歲雲南永平縣男士，患神經纖維瘤，令右脛骨骨折，並且不能癒合，右脛骨漸漸變形及內翻，因此右小腿短了，腳跟不能著地，走路困難。

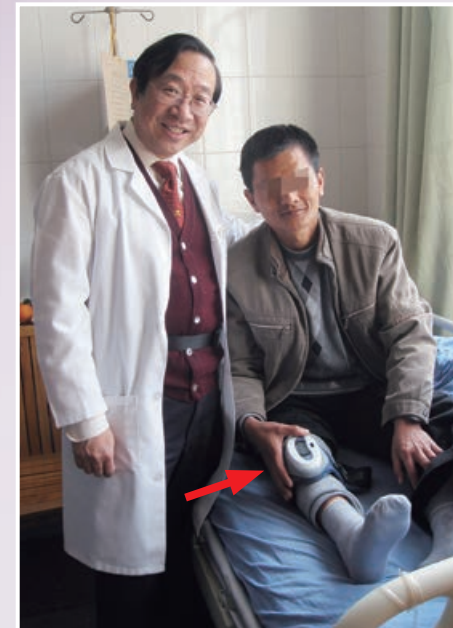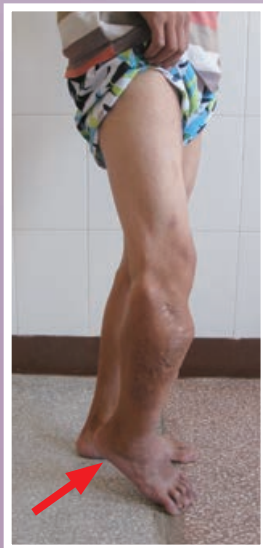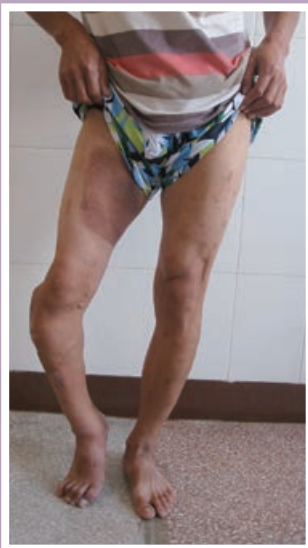A 39-year-old man from Yong Ping County, Yunnan. He had fibrous dysplasia leading to fracture non-union of right tibia. The right leg was gradually deformed and shortened. The right leg became shorter, and the heel could not touch the ground. Walking was difficult.



右脛骨骨折，未能癒合。
Fracture non-union of right tibia.

右側小腿變形、內翻，右腳跟不能著地。

Right leg was deformed into varus. The right heel could not reach the ground.



手術後為了幫助骨頭癒合，配上骨骼增生器。

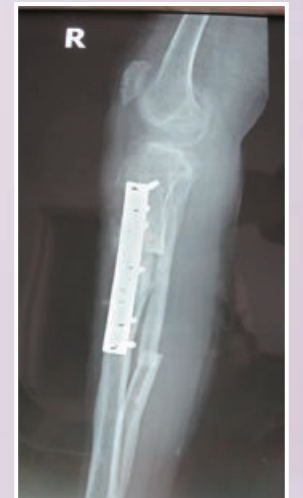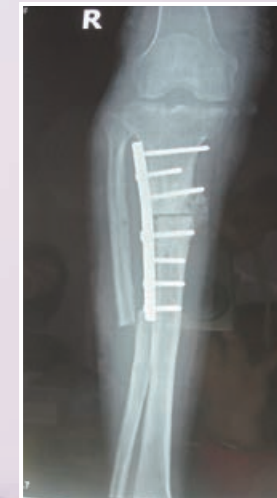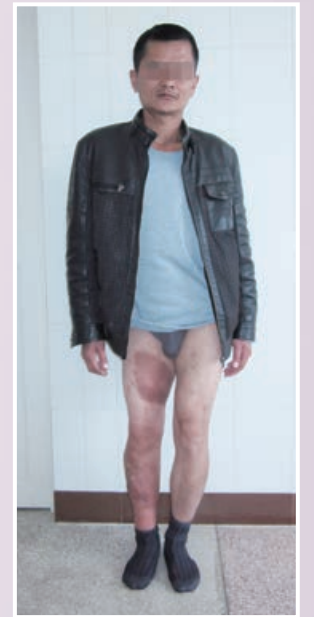
In order to enhance bony healing, a bone stimulator was used after surgery.

做了截骨及植骨手術後的 X 光片。

X-ray after osteotomy and bone graft procedure.

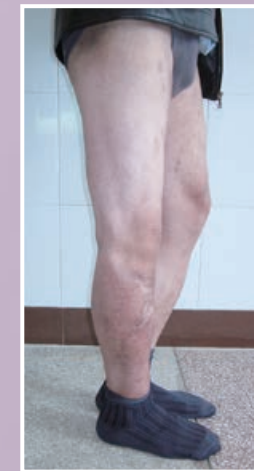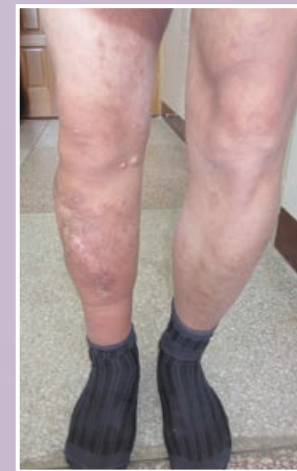因為瘤腫的影響，骨頭生長比較慢，但癒合後下肢恢復正常位置。

Patient's bone healed slowly due to the effect of the tumor. After healing, the alignment of the lower limb was restored.



內翻已經矯正，腳跟可以平放在地上，但右小腿短了一點，可以把鞋底加厚來補償。

The deformity of the right leg was corrected. The right heel can reach the floor. The mild shortening of the right leg can be compensated with a shoe lift.



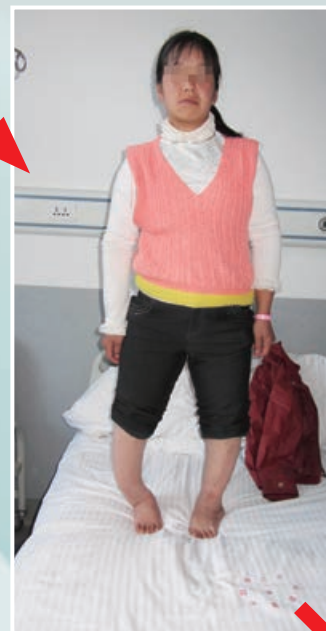K 002

O 型腿

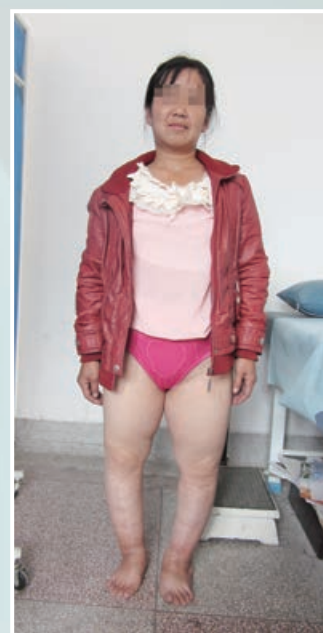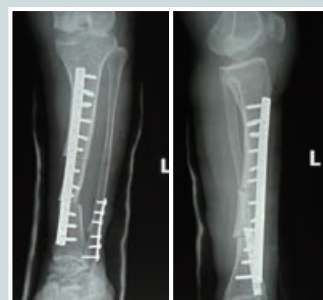Bilateral Genu Varum

一位在雲南的村婦，自幼雙側小腿內翻變形，走路時雙膝關節疼痛。

A female peasant from Yunnan. She developed bilateral bowlegs since childhood. She complained of bilateral knee pain on walking.



左小腿手術矯正後。
After surgery on the left leg.

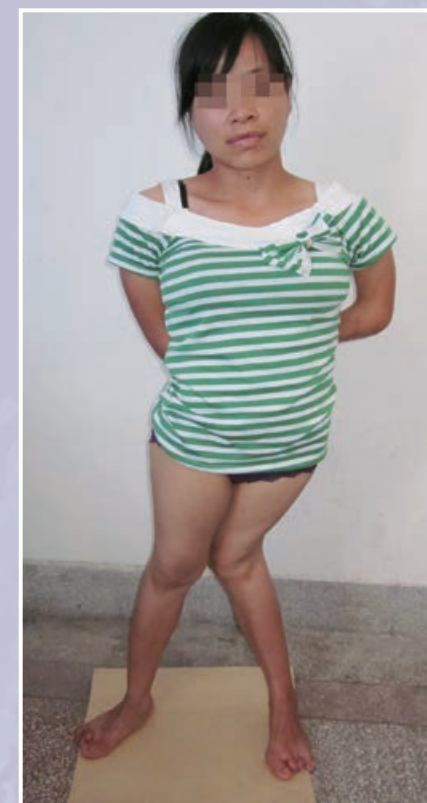

右小腿手術矯正後。
After surgery on the right leg.

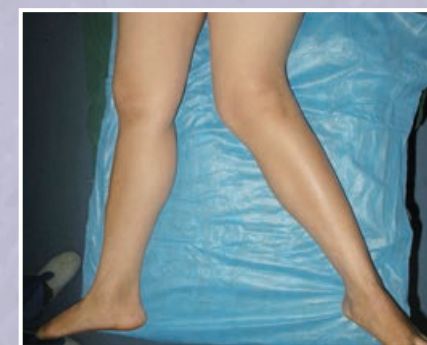
患者分階段進行了左側脛骨及右側脛骨截骨手術，小腿內翻大為改善，膝關節疼痛亦消除了。

Patient had left tibial osteotomy followed later by right tibial osteotomy. The bowlegs deformity was largely improved with relief of knee pain.

K 003



手術前 Before Surgery

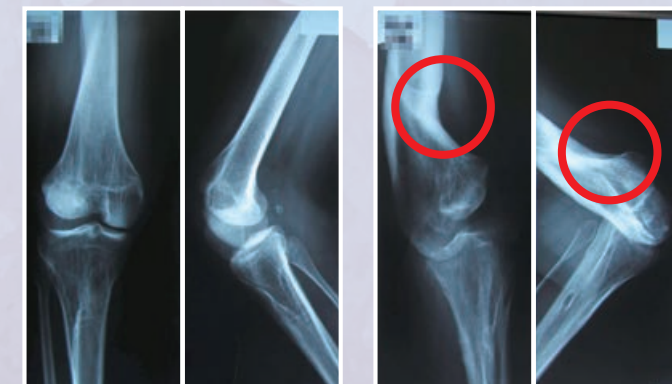

30 多歲大理女病人，左側股骨先天性變形，引致左膝關節外翻及疼痛。

A Dali female patient in her thirties. She had congenital dysplasia of the left femur leading to genu valgum and pain.

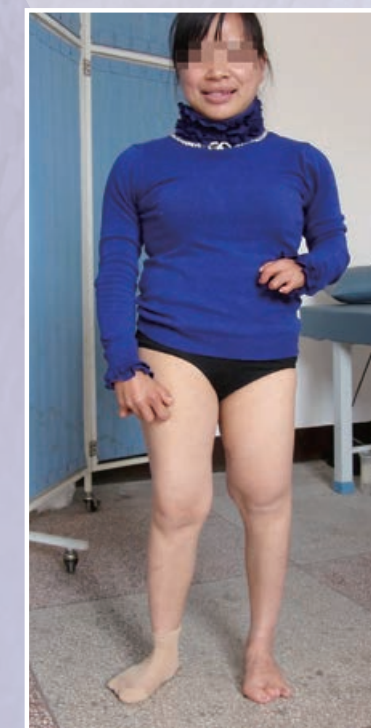左股骨變形、左膝外翻

Left femur dysplasia
Left genu valgum



正常的右側股骨。
Normal right femur.

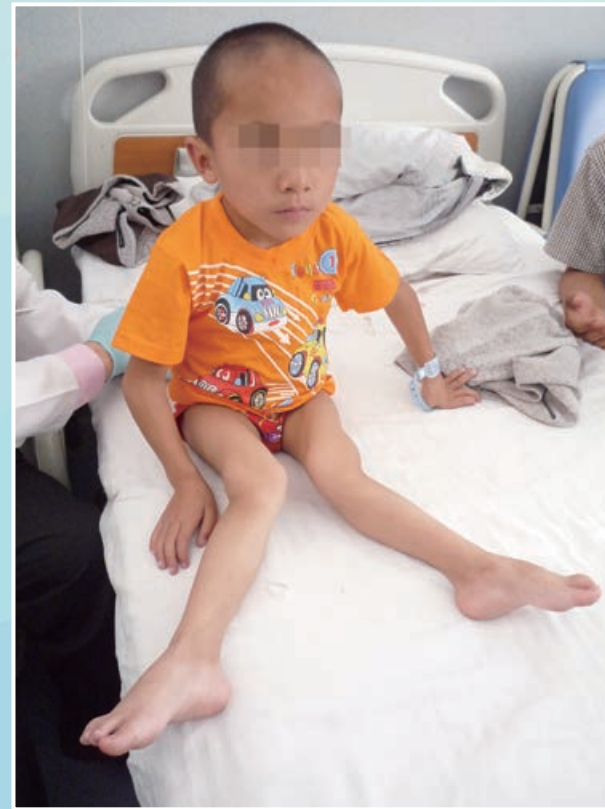左側股骨變形。
Dysplastic left femur.



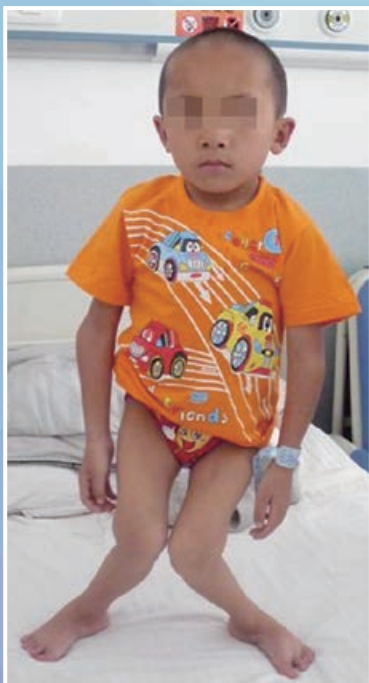左股骨截骨手術後，下肢位置恢復正常，左膝疼痛已消除。

The alignment of the left knee was restored to normal after osteotomy of femur and knee pain subsided.

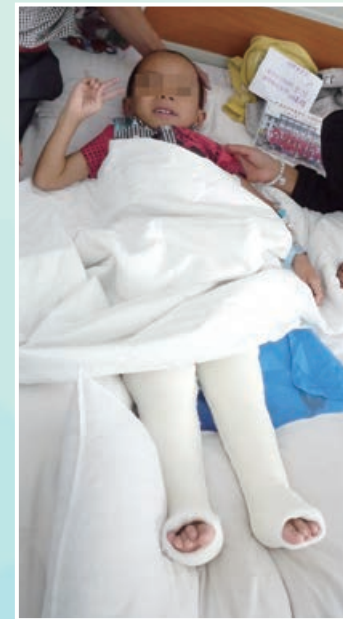K 004



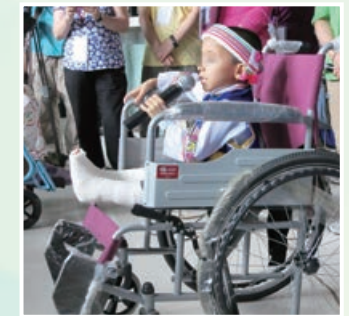雙側膝關節外翻 Bilateral Genu Valgum



9 歲大理小數民族的男孩子，身材矮小，患雙側膝關節嚴重外翻，負重時雙膝疼痛，走路困難。
A 9-year-old boy from a minority group. He was short in stature and had severe knock knee deformities. Walking was difficult and associated with knee pain.


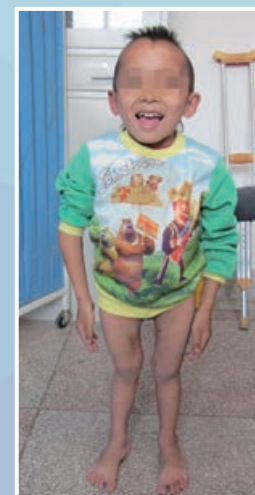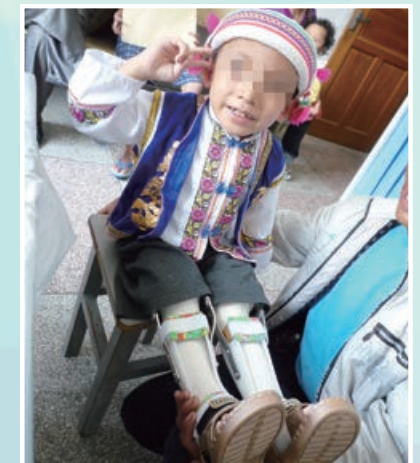


截骨手術後打了石膏。
Long leg casts were applied after osteotomy surgery.



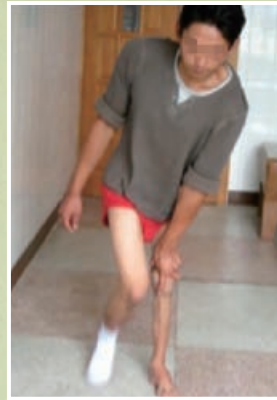病人在告別儀式上致謝詞。
Patient gave words of appreciation at farewell.

手術後兩個月，拆了石膏，配上支具。
Two months after surgery, the casts were removed and fitted with bilateral long leg braces.



手術後一年，下肢已經矯正，走路正常，膝關節疼痛消除。
One year after surgery, the lower limbs were well corrected. The gait was normal, and the knee pain subsided.

K 005

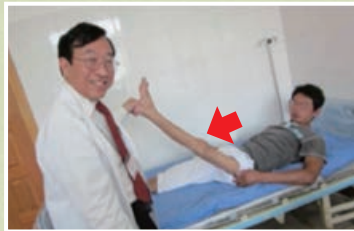

兒麻後遺症 左側膝關節攣縮

Post-poliomyelitis Left Knee Contracture

一位 23 歲大理男子，因幼時患小兒麻痺症，令左下肢萎縮無力，左膝關節攣縮，不能伸直，負重時必須用手支撐大腿。

A 23-year-old man from Dali. He suffered from poliomyelitis when he was a child. It led to left lower limb weakness, wasting, and flexion contracture of the knee. He had to support the left thigh on weight bearing when he walked.




手術前左膝是屈曲的，截骨手術後可以完全伸直。

The left knee flexion contracture was fully corrected after osteotomy surgery.

病人說：「手術前要用一隻手按着大腿走路，拿東西都不大方便，因為只有一隻手。手術後不需要用手按着大腿走路，可以兩隻手拿東西。以前走的路長了，手和腿都酸起來，手術後，能走挺遠的。」

Patient said, "In the past, I had to use my hand to push against the thigh when I walked. It was very difficult to hold objects. After surgery, it is not necessary to push against the thigh. I can use both hands to hold objects. Before surgery, my left hand and thigh soon became sore when I walked. Now, I can walk for very long distance."



K 006



2017 年夏，已康復病人與劉漢杰醫生合照。

Summer of 2017. Patient had photo with Dr. James Lau.



手術後覆診時拍的舊照片。

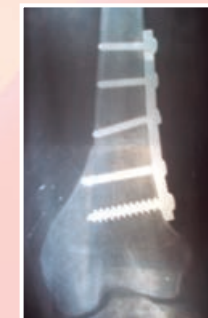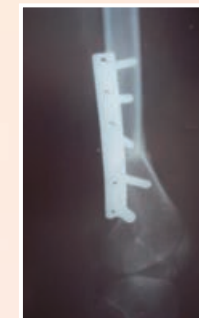Old photo taken on follow up after surgery.

兒麻後遺、右側膝關節攣縮

Post-poliomyelitis Deformity Flexion Contracture Right Knee

2017 年的仲夏，已近黃昏，剛到病房，準備檢查手術後的病人。一位穿著入時的女士迎面走來，原來她已經等了幾個小時。她特意從上海到沁陽，為的是表示衷心的感謝。原來 12 年前她是我的病人，她在河南另一所醫院，接受了手術。當時她因為小兒麻痺，令右側膝關節攣縮，不能完全伸直，走路時要用手按着大腿，才能負重。手術後右膝回復正常位置，走路基本上與正常人沒有分別。生活上得到很大幫助，亦因此可以搬到上海工作。

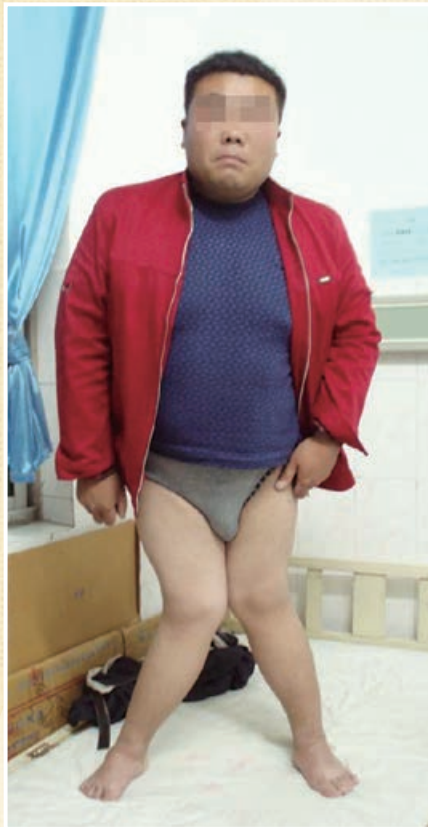It was close to evening on one hot summer day in 2017. I just arrived at the ward, trying to get ready for the evening round. A lady in fashionable dress walked straight to me. She came from Shanghai and had been waiting for several hours. The reason for her visit was to express her appreciation for our help. I found out that she was one of my surgery patients 12 years ago in another hospital in Henan. At that time, she developed flexion contracture of the right knee due to poliomyelitis. She was unable to bear weight unless she used her hand to support the thigh. After surgery, her knee can fully extend and the gait is normal. This greatly enhances her daily living and helps her to seek employment in Shanghai.



覆診時的 X 光片，骨頭已經癒合。

X-ray taken on follow up showing good bony healing.

K 007



雙側膝關節外翻

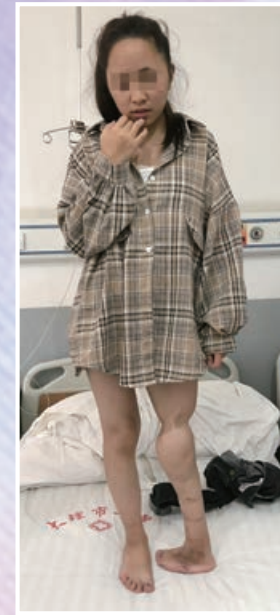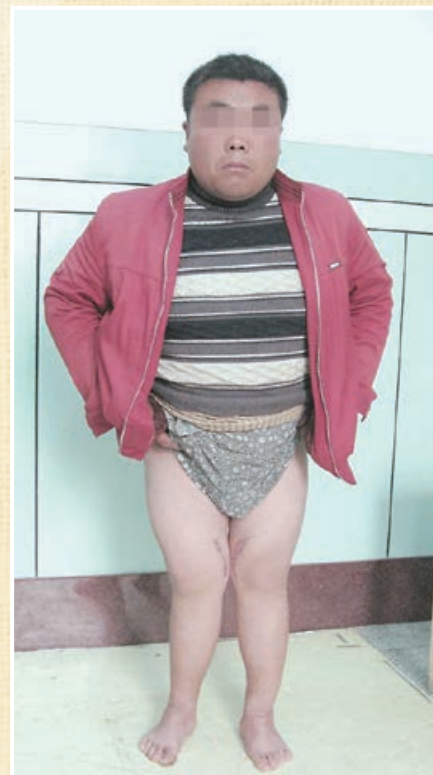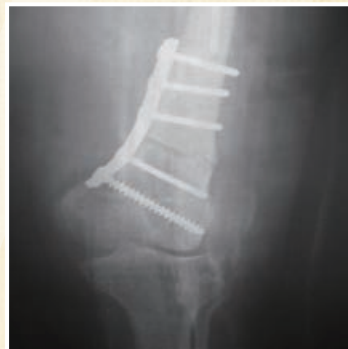Bilateral Genu Valgum

22 歲河南男子，患雙側膝關節外翻，膝關節負重時疼痛，令走路困難。

A 22-year-old man from Henan. He had bilateral knock knee (genu valgum) deformity. Walking was difficult because of knee pain.

手術分兩階段進行，首先矯正右膝因為右膝比較疼痛，康復後做左側膝部矯正。兩年後，雙下肢位置比以前改善良多，膝關節疼痛已經消除。

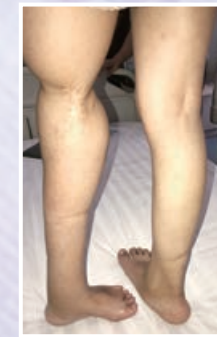Treatment was divided into two stages. The right knee was operated first because it was more painful. Later the left knee was operated. Two years later, alignment of both knees much improved and the knee pain subsided.



羊膜帶序列症、左脛骨內旋 Amniotic Band Syndrome Left Internal Tibial Torsion

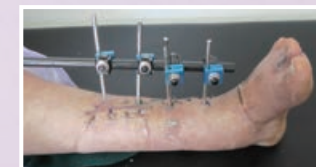一位 20 歲大理女子，患有先天性的羊膜帶序列症，引致多處肢體異常，但對她影響最大就是左側小腿內旋約 90 度，令走路困難。

A 20-year-old lady from Dali. She has congenital amniotic band syndrome that leads to multiple deformities in the body. However, what affected her most was the extreme internal rotation of her left leg making walking difficult.



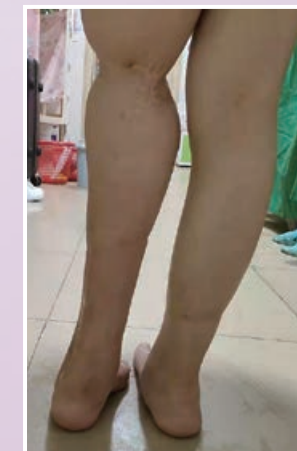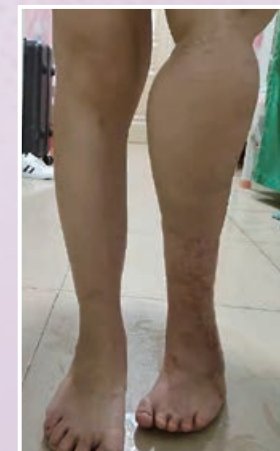病人接受截骨手術，把小腿的內旋矯正，但發現旋轉至正常位置，左腳的血液循環受不良影響，故只能接受較少的旋轉度數矯正。

De-rotation osteotomy of the left tibia was performed. Rotation to normal alignment caused compromise in circulation, therefore a partial correction was accepted.



骨頭生長很慢，所以要加做殖骨手術，差不多十個月後骨頭才生長好，左腳位置比以前大有改善。

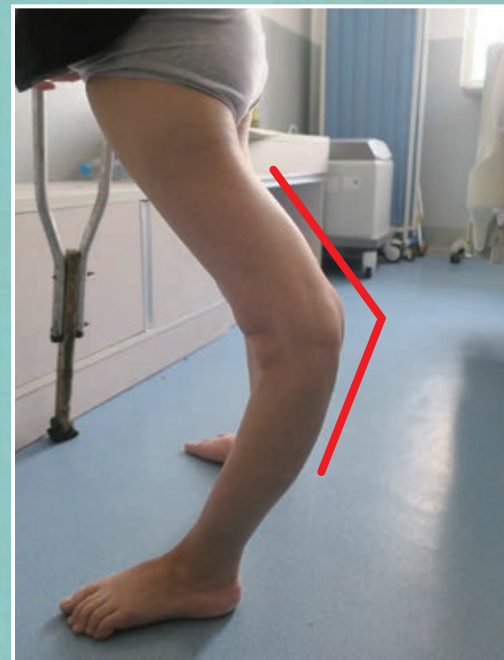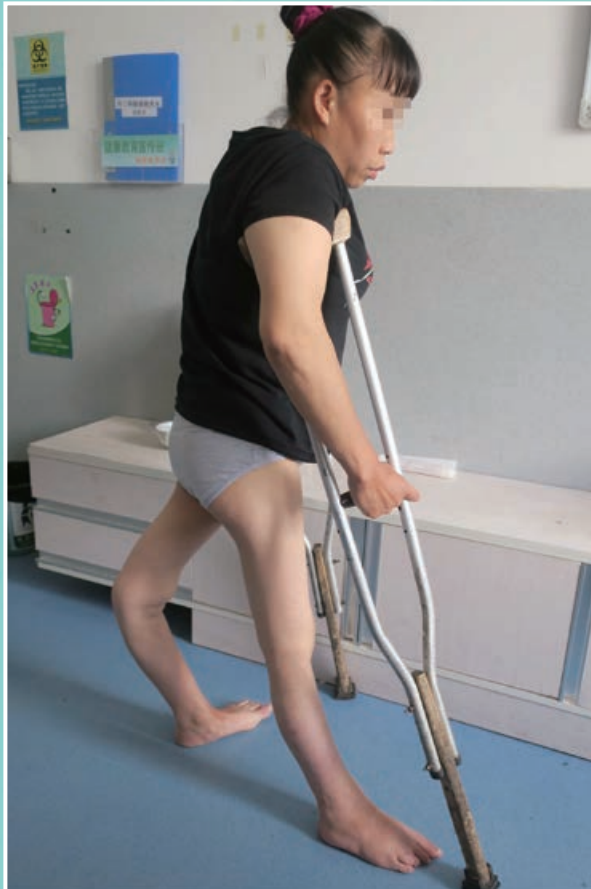The bony healing was slow; therefore, a bone graft procedure was added. It took over 10 months for bony union. Alignment of the left foot much improved.



K 008

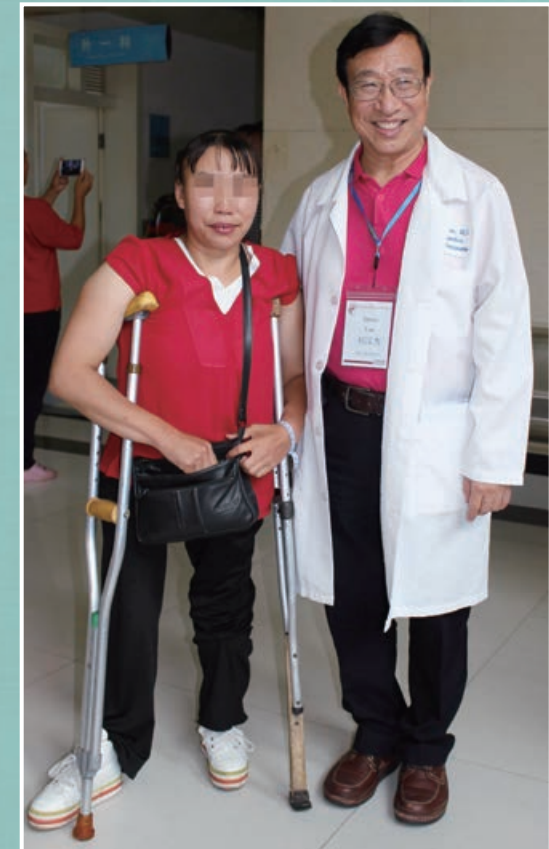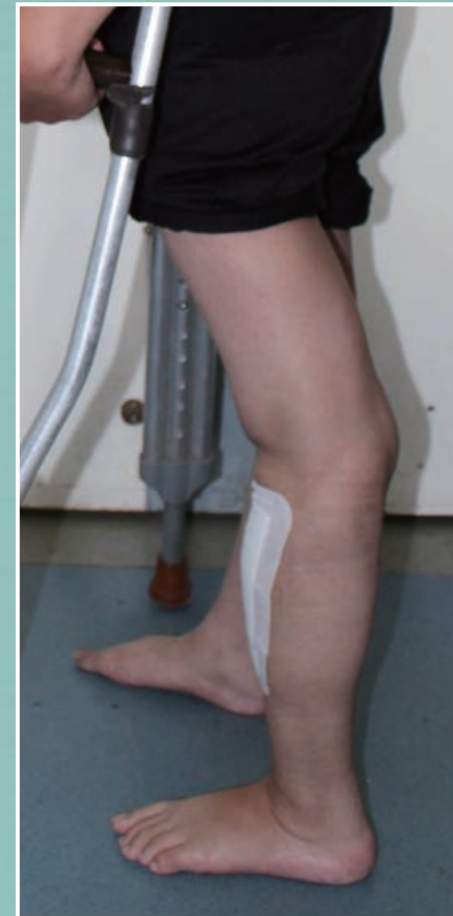K 009

兒麻後遺、左膝反屈

Post-poliomyelitis Left
Genu Recurvatum Deformity

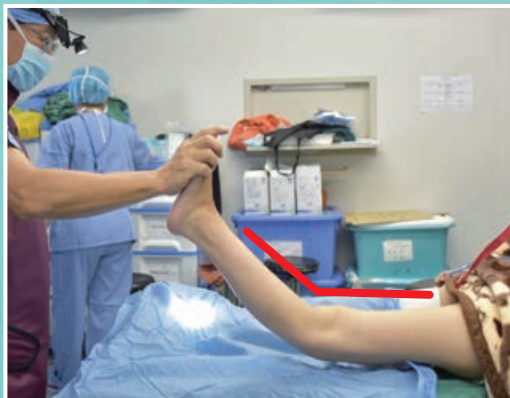47 歲患小兒麻痺後遺症河南女士，
左側膝關節嚴重反屈，走路時不穩
及疼痛。

A 47-year-old lady in Henan
with post-poliomyelitis
deformity of the left knee.
It was in severe genu
recurvatum. The knee was
unstable and painful on
walking.

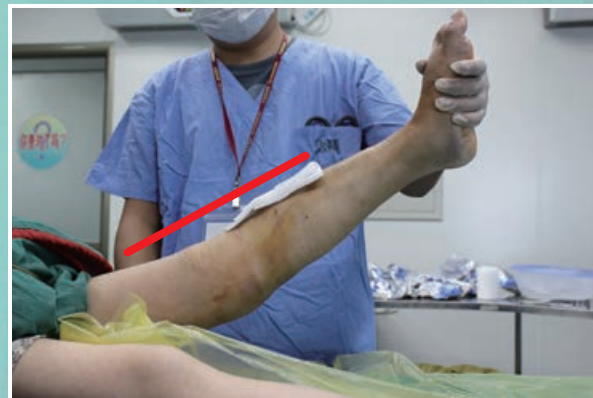

經過截骨手術後，左膝位置大有改善，疼痛消
除，而且步履穩定。

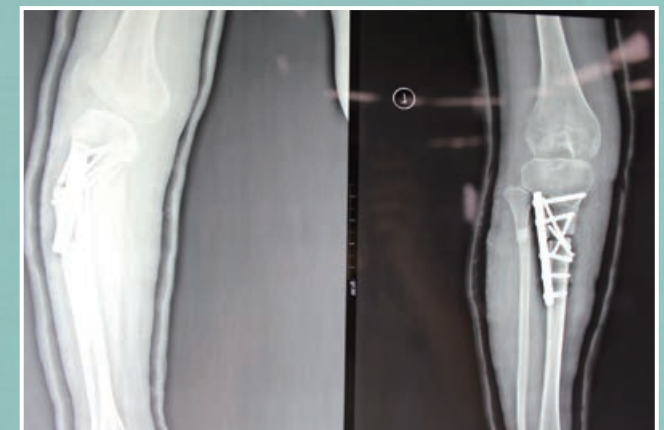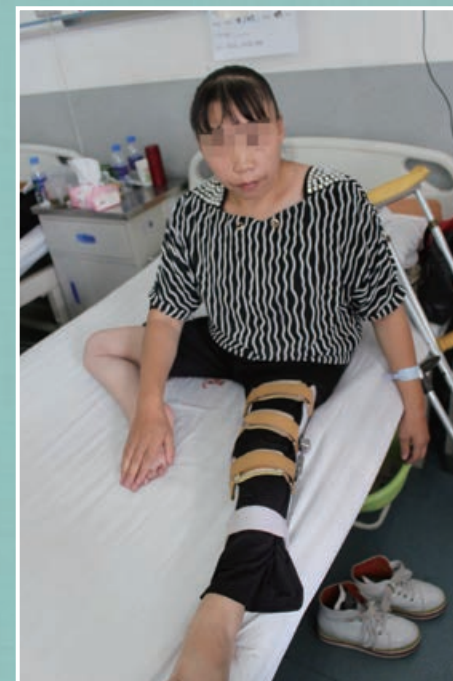After osteotomy, the left knee deformity
was largely corrected. The knee is stable
and pain free.



手術前 Before Surgery



手術後 After Surgery



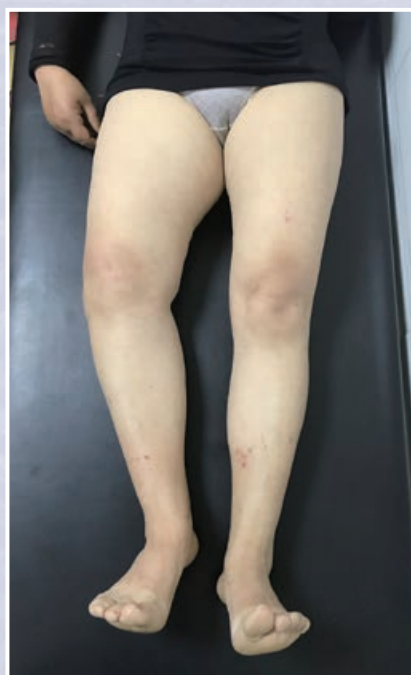
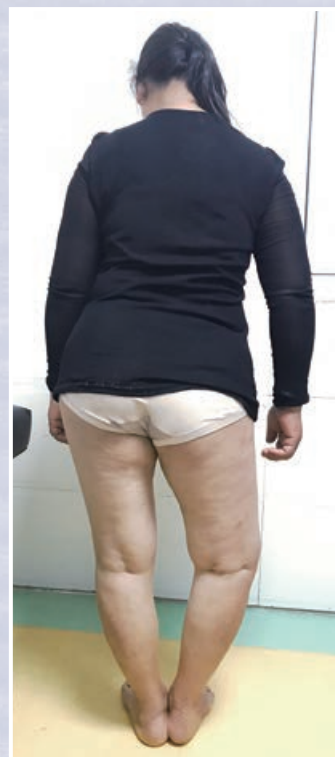
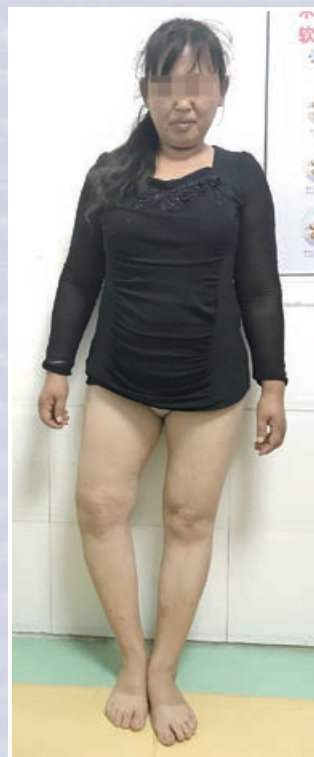K 010

右膝關節退化性關節炎、右膝內翻

Osteoarthritis of Right Knee, Right Genu Varum

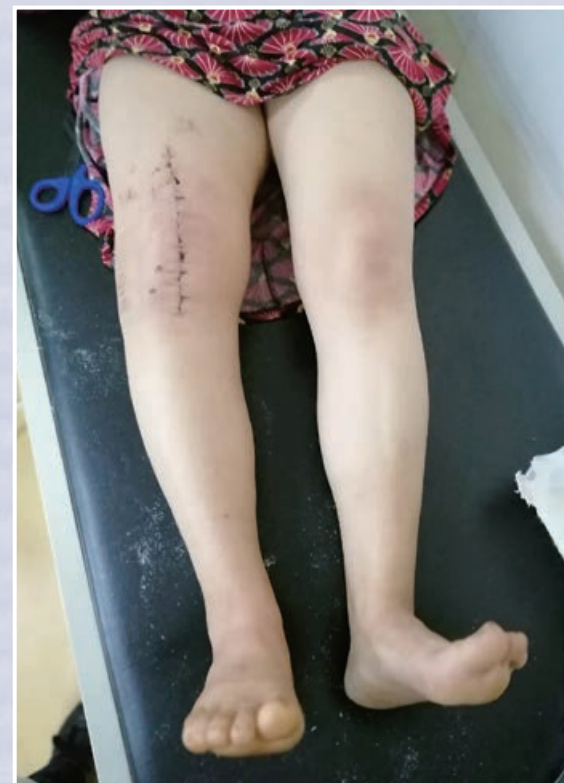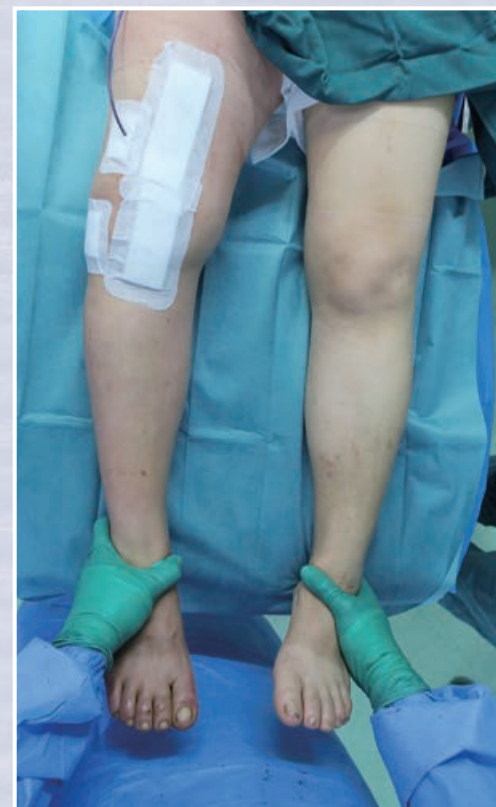一位 45 歲四川瀘州女士，患退化性關節炎，令右膝變形和走路時疼痛。

A 45-year-old lady from Luzhou, Sichuan was suffering from osteoarthritis of the right knee. It became deformed and was painful on walking.



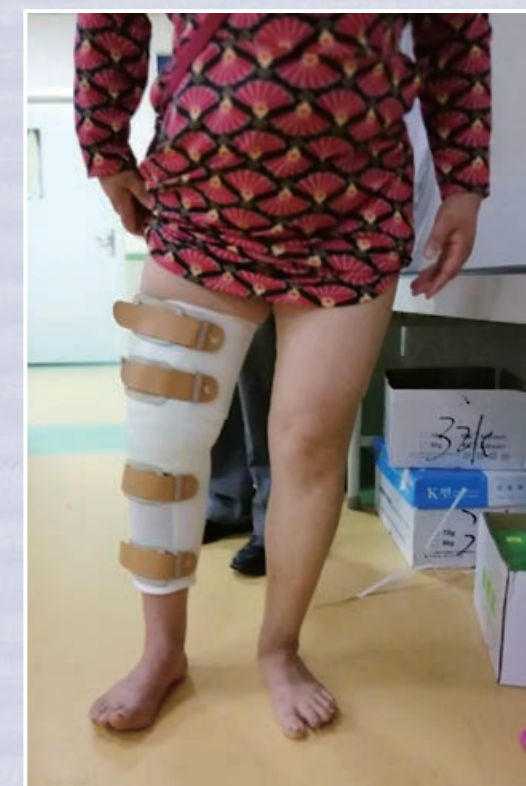右側膝關節內翻，站立或行走時，關節畸形更顯嚴重。

Right genu varum became more obvious on standing and walking.



踝上截骨手術後，右膝關節位置已獲改善。

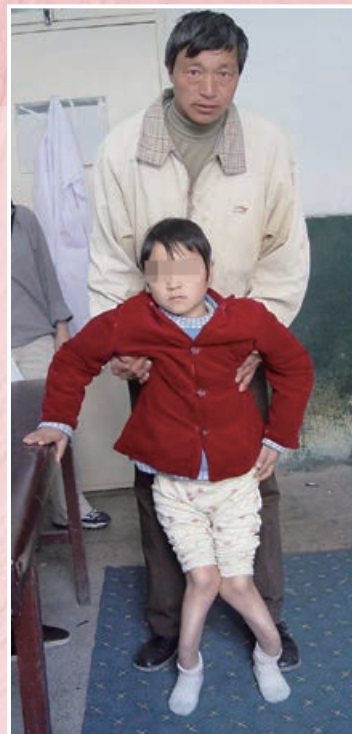Photo taken after the osteotomy of the right femur was performed. The improvement in alignment was noted.



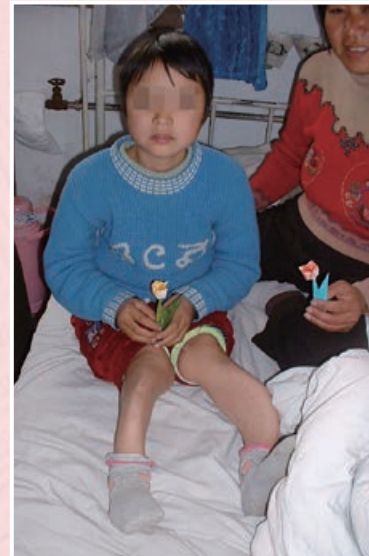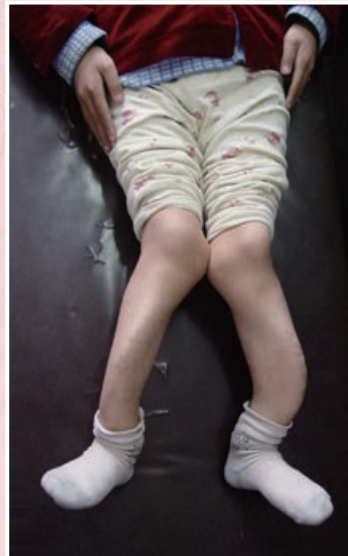手術兩個月後覆診，骨膝關節位置已經矯正，病人配上支具，開始物理治療。

Follow up two months after surgery. The alignment of the right knee improved. Patient was fitted with a brace and started physical therapy.

K 011



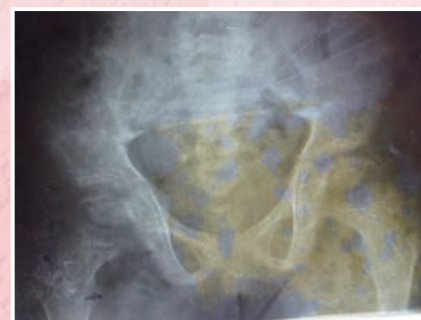
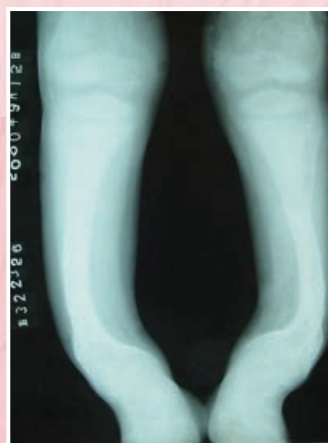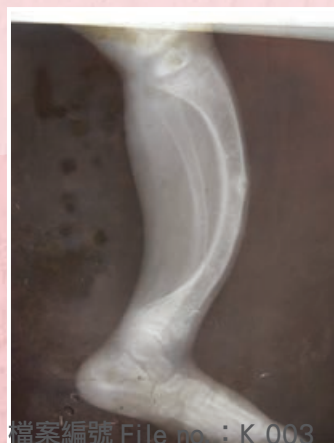2005



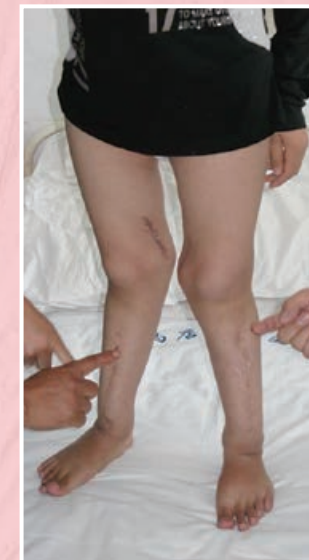骨骼發育不良、骨頭變形及彎曲、雙側膝關節外翻 Bone dysplasia, bilateral bowleg and genu valgum

一位 15 歲所河南女子，患骨骼發育不良症，骨骼嚴重變形及彎曲，雙膝外翻無力，不能站立。

A 15-year-old girl from Henan. She had bone dysplasia with severe bowlegs and knock knees. Her legs were weak, and patient was unable to stand.



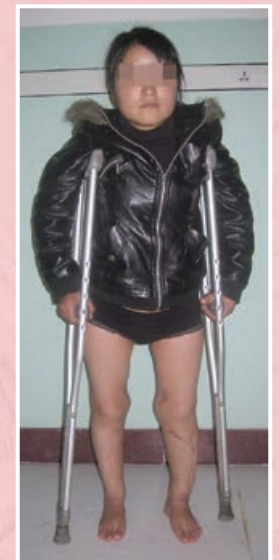2006



2008



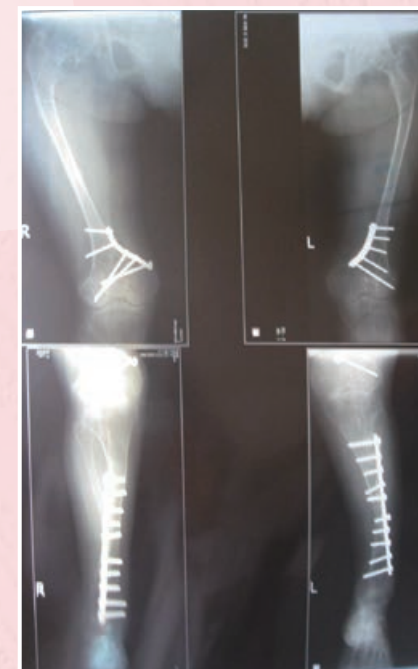2009



2010

病人接受了多次的截骨手術，把下肢慢慢矯正過來。最後位置恢復正常，病人平時只用一枝拐杖走路，但也可以不用拐杖步行短距離。

Several osteotomy procedures were performed. The lower limbs were gradually corrected. The final alignment is good. Patient usually uses one crutch for ambulating but can walk for short distance without crutches.



病人做了雙側股骨及脛骨截骨手術。

Patient had osteotomy of bilateral femur and tibia.

病人當推銷員。
Patient works as a salesperson.



K 012



兒麻後遺症 右膝反屈、左膝攣縮

Post-poliomyelitis Deformities Genu Recurvatum Right Knee Flexion Contracture Left Knee

手術前，右膝反屈越來越嚴重，而且疼痛。左膝攣縮，不能完全伸直，要用手按著大腿才能負重，走路非常困難。

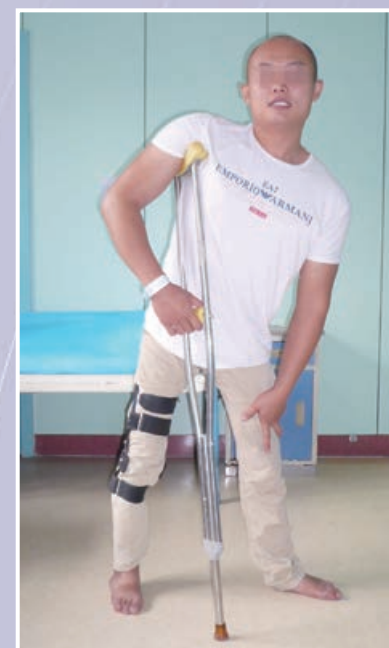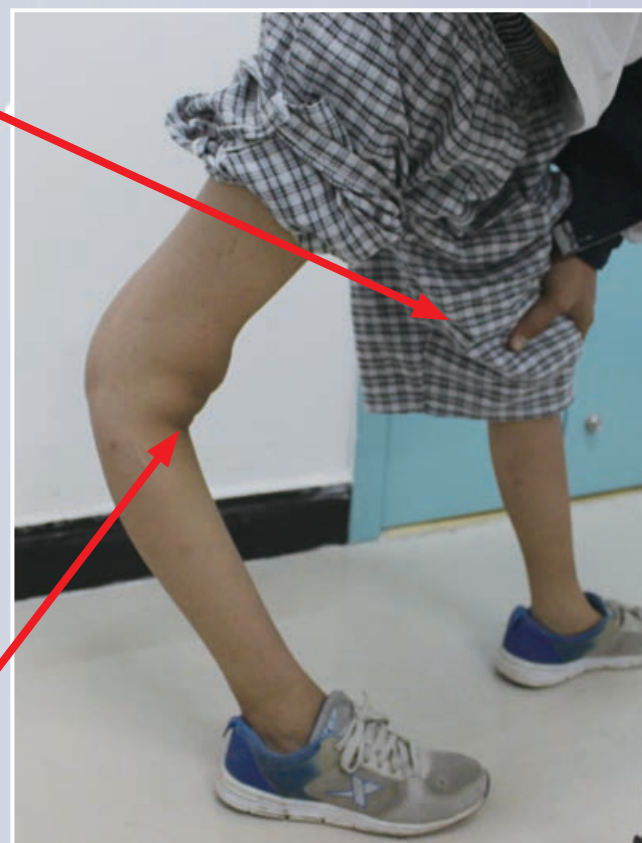Before surgery, genu recurvatum of right knee was getting worse. Left knee had flexion contracture and needed support of left hand on weight bearing. Walking was difficult and painful.

左膝屈曲，不能伸直，站立時必須用手按著大腿才能負重。

Left knee flexion contracture. Has to use left hand to support the thigh on standing.

2016 手術前 Before Surgery

右膝反屈嚴重，走路時疼痛。Right knee genu recurvatum. Painful on walking. Deformity getting worse.

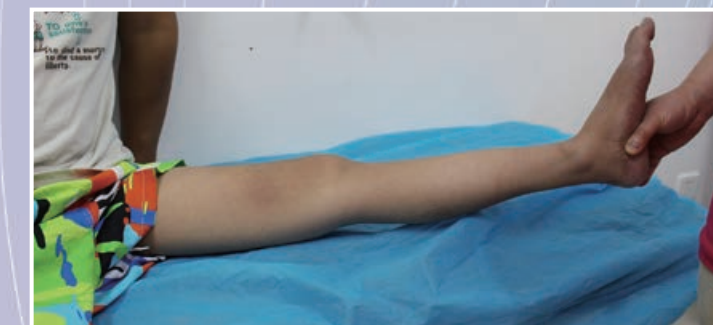

2016 右膝手術後 After Right Knee Surgery

右膝手術後，反屈已經矯正，疼痛消除，需要配戴支具，避免反屈重現。

After right knee surgery, deformity was corrected. Knee pain subsided. A brace was used to prevent recurrence of genu recurvatum.

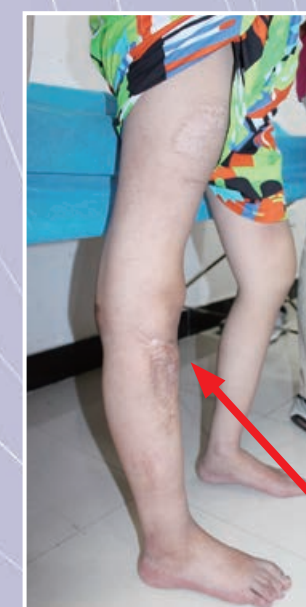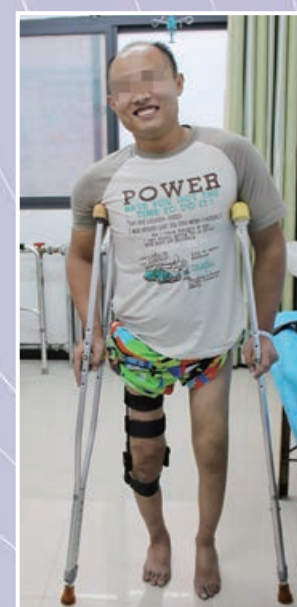2017 左膝手術後 After Left Knee Surgery



左膝手術後，屈曲已經矯正，走路時不需要用手按著大腿。

After the second surgery, left knee flexion contracture was corrected. No longer need to use the left hand to support the knee.

2017 反屈已經矯正。 Genu recurvatum corrected.

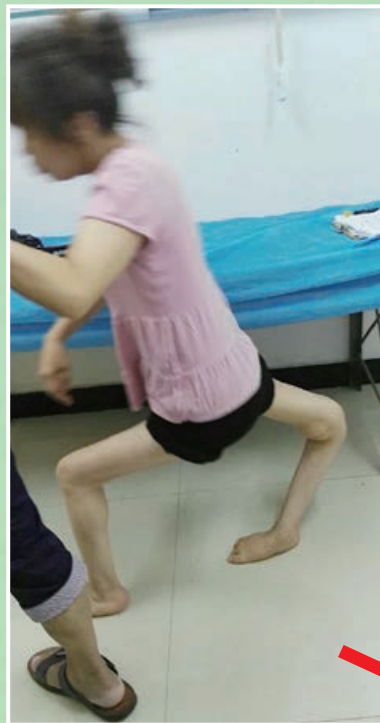

K 013

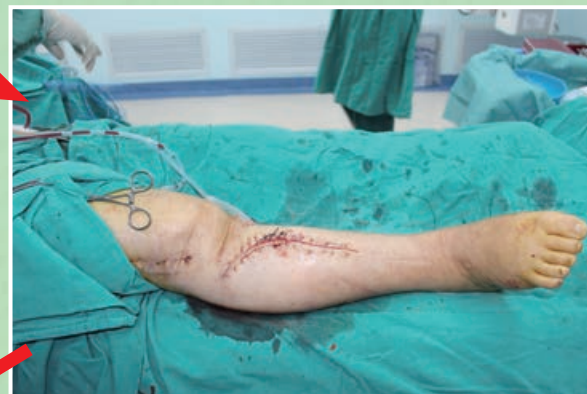兒麻後遺、右膝反曲 Post-poliomyelitis Deformity Right Genu Recurvatum

一位 54 歲河南女士，幼年患小兒麻痺症，令右下肢萎縮無力，右膝關節負重時嚴重反曲，走路非常不穩和困難。

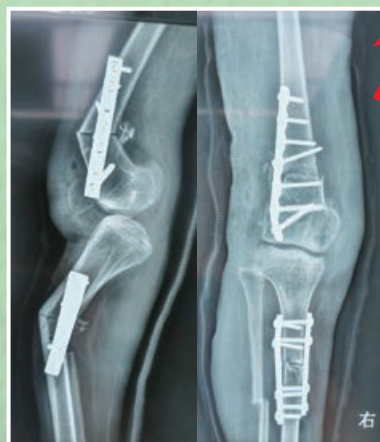A 54-year-old lady from Henan. She suffered from poliomyelitis in childhood leading to wasting and weakness in the right lower limb. On weight bearing, severe genu recurvatum developed in the right knee. Walking was unstable and difficult.



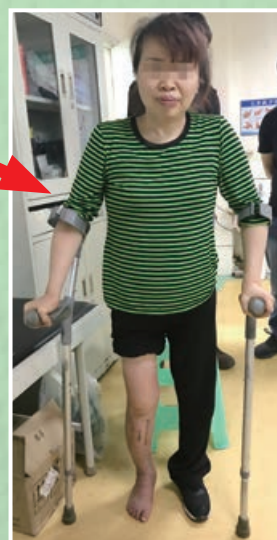手術前
Before Surgery



手術中
In Surgery

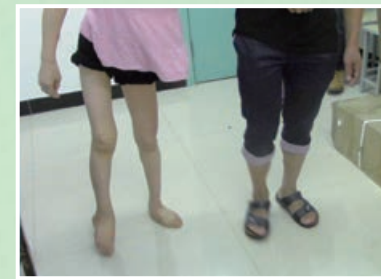

截骨手術後 X 光片
X-ray after osteotomies



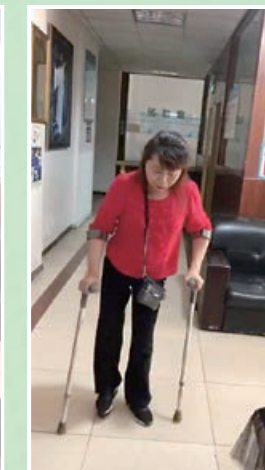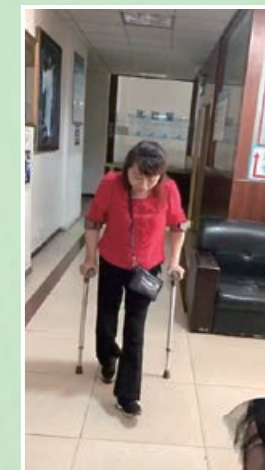
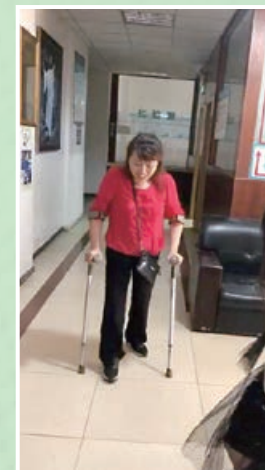手術後右腳負重時膝關節位置正常，不會反曲。

After surgery, the right knee will not go into recurvatum on weight bearing.



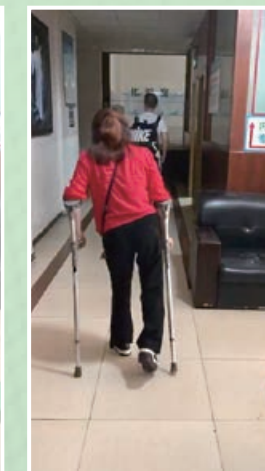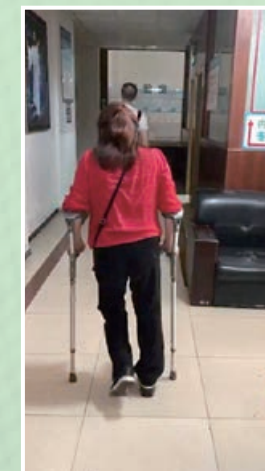手術前每次右下肢負重，膝關節就屈曲變形。

Before surgery, every time on weight bearing, the right knee went into recurvatum.

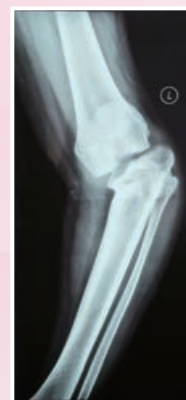
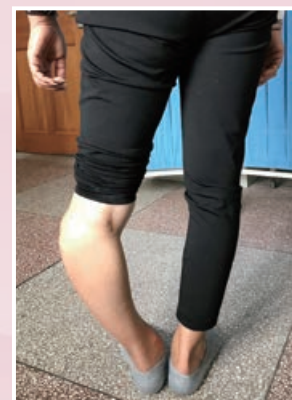
手術後，膝關節穩固，不會因負重而變形。

After surgery, the right knee becomes stable and will not go into recurvatum on weight bearing.



K 014

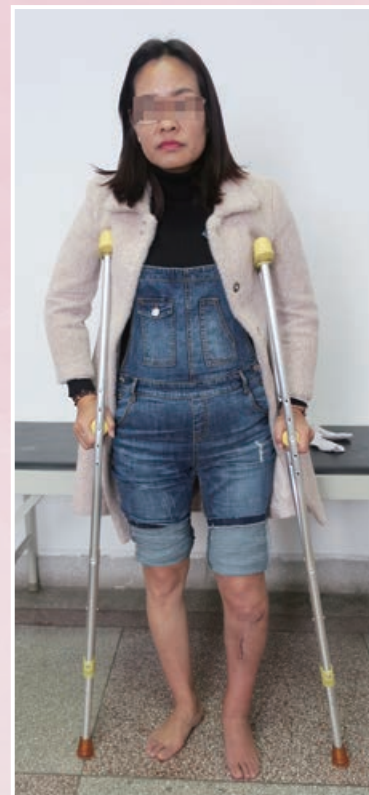
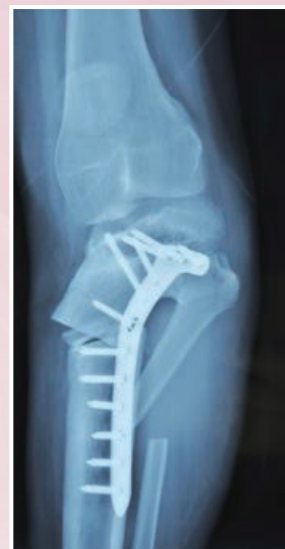
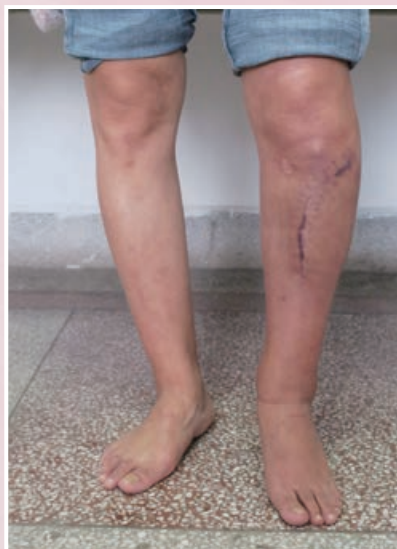創傷後左膝內翻

Post-traumatic Left Genu Varum

28 歲大理女士，左膝創傷後嚴重內翻。

A 28-year-old lady from Dali with varus deformity of the left knee after trauma.



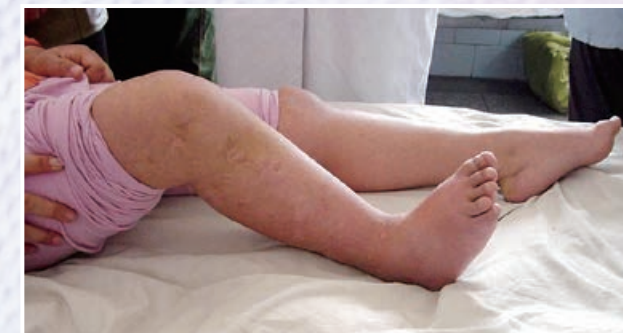手術後左膝內翻已經矯正。

Left knee deformity was corrected after surgery.

K 015

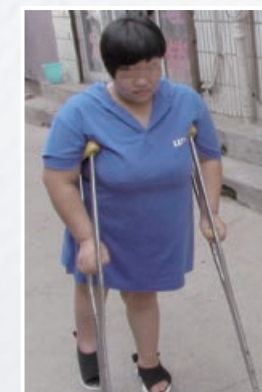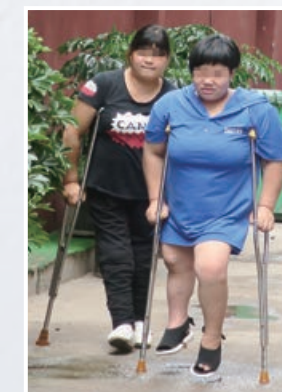
小兒麻痺後遺症、右側膝關節攣縮及內翻

Post-poliomyelitis Deformity Right knee Flexion Contracture and Genu Varus



一位 13 歲河南少女，因幼時患小兒麻痺，引致右下肢發育緩慢，肌肉癱瘓無力，右膝攣縮及內翻。她接受了截骨手術，把膝部畸形矯正過來，但下肢依然短了。

A 13-year-old girl from Henan. She suffered from poliomyelitis in early childhood. It led to retard development of the right lower limb, muscle wasting, and weakness. The right knee developed contracture and varus deformity. She had osteotomy of the right knee with the deformities corrected but the leg remained short.



15 年後，舊病人已經結婚並育有一子，她開了一間美容院。膝部位置正常，因為右腿太短，不能負重，但舊病人可以用拐杖走路。

15 years later, we visited the patient. She is married with a boy. She is the owner of a beauty salon. Her right knee alignment is good, but the lower limb is short and cannot bear weight. She, however, can ambulate with a pair of crutches.

K 016

小兒麻痺後遺症、右側膝關節攣縮

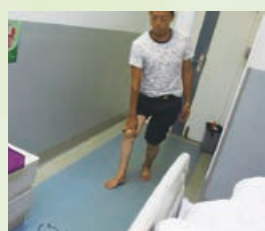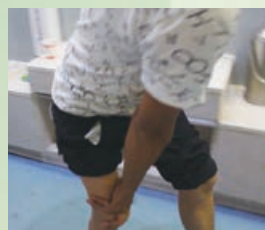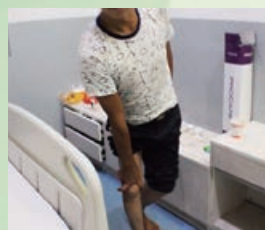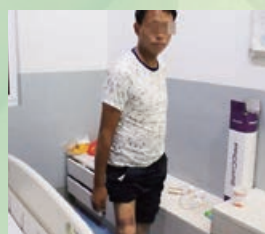Post-poliomyelitis Deformities Flexion Contracture of the Right Knee

一位 38 歲大理男子，幼年患小兒麻痺症，導致右下肢部份癱瘓，軟弱無力，生長緩慢而短小，右側膝關節攣縮，不能伸直，站立時不能負重，需要用右手支撐大腿，方可步行。右側大腿上的皮膚，因為長久受右手按着而生了深色的繭皮。

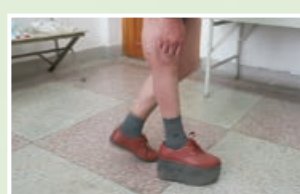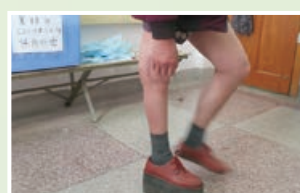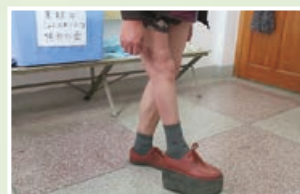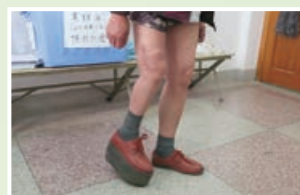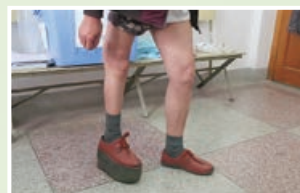病人接受了截骨及植骨手術，把屈曲的右膝關節矯正，能夠完全伸直，走路時可以負重，不再需要用手支撐。

A 38-year-old man from Dali. He had poliomyelitis in childhood leading to partial paralysis of right lower limb. Muscles are weak and atrophic. Growth was retarded leading to shortening of right leg. There was flexion contracture of the right knee. The knee could not be extended fully on standing. He had to use the right hand to support the right thigh for ambulation. Thus, leading to formation of thick callosity over the skin on the thigh.

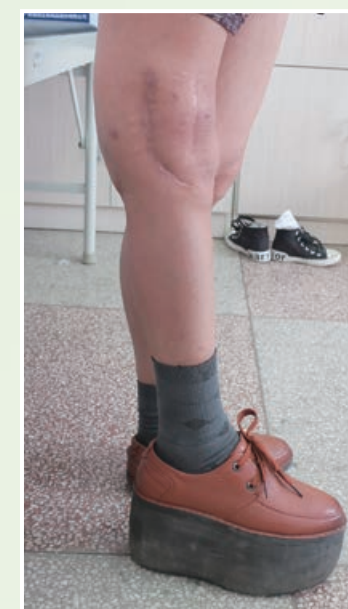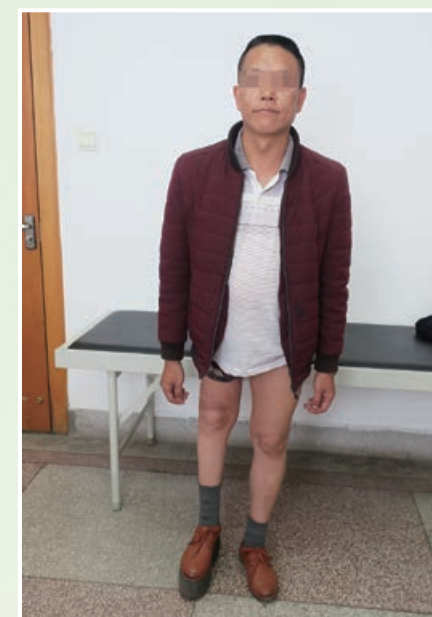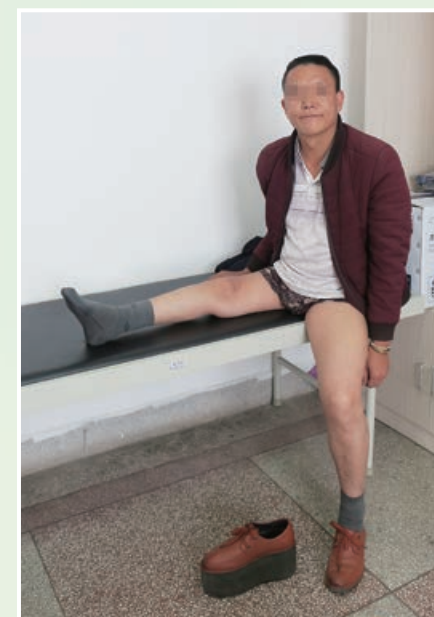After osteotomy and bone graft surgeries, the right knee was corrected. Patient was able to extend the knee fully for weight bearing. Thus, the hand-knee gait resolved.



手術前
Before Surgery



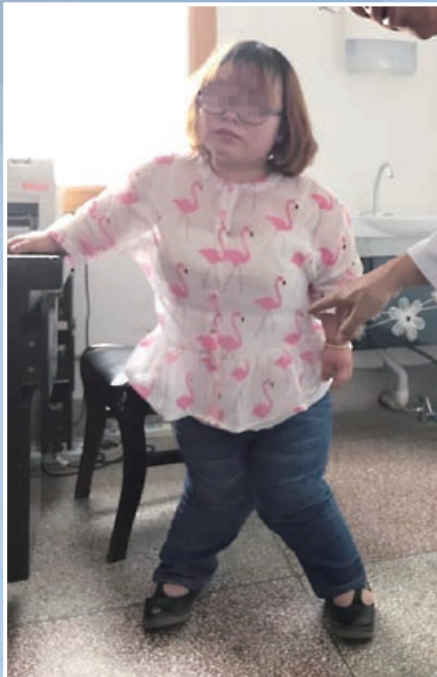手術後
After Surgery



手術後，右膝關節攣縮矯正了，右膝能夠完全伸直。右下肢因以前生長緩慢而短小，所以配上加高鞋以作補償。右側大腿上的老繭皮已經漸漸回復正常的皮膚。

After surgery, the flexion contracture of the right knee was corrected. The knee can fully extend. Right lower limb is short due to retarded growth after poliomyelitis. A shoe lift was added to compensate for the leg length discrepancy. The callosity of the right thigh gradually resolved and replaced by normal skin.

K 017



軟骨發育不全症 雙膝外翻

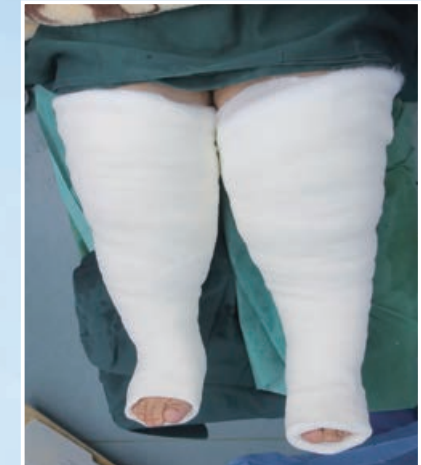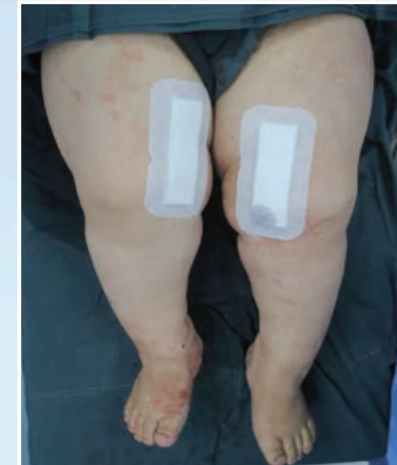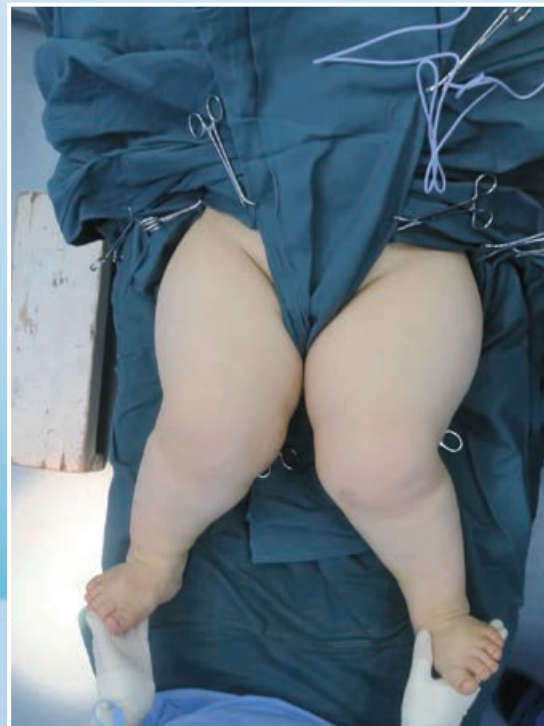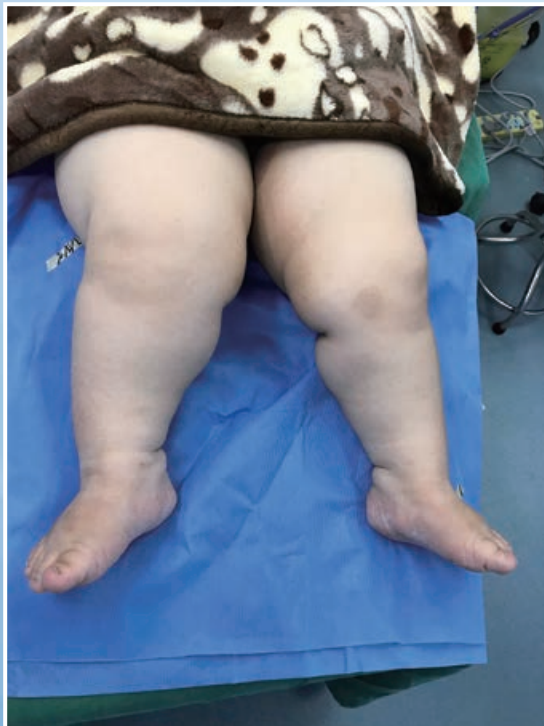Achondroplasia Bilateral Genu Valgum

26 歲女中醫，患有軟骨發育不全症，雙膝關節嚴重外翻及疼痛，行路困難。

A 26-year-old Chinese medicine doctor with achondroplasia. She had severe bilateral knock knees (genu valgum). Had bilateral knee pain and difficulty walking.

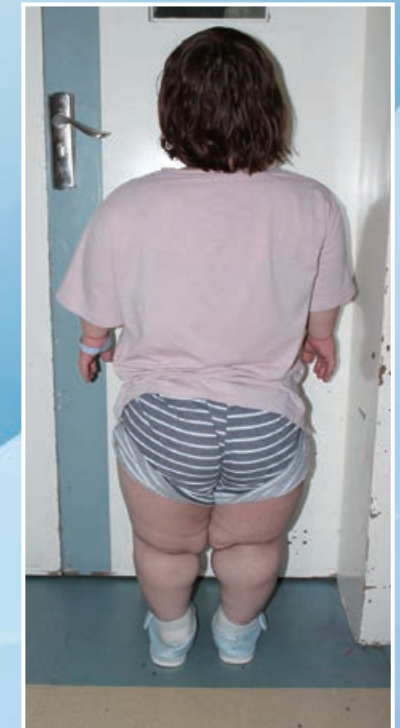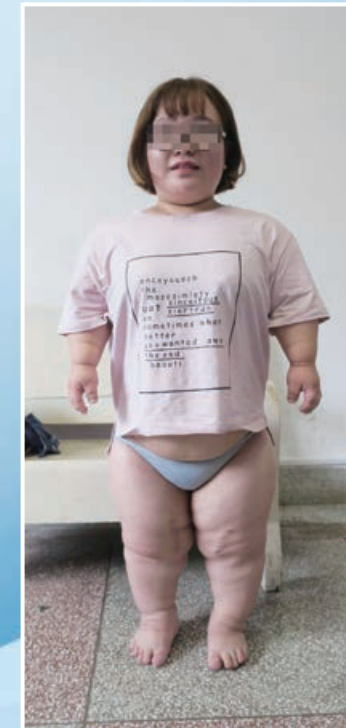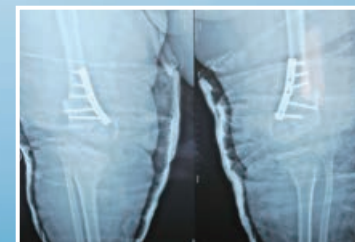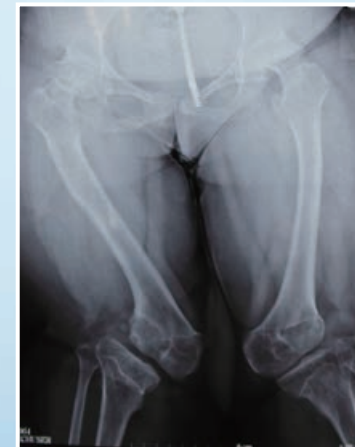手術開始前的相片，雙膝嚴重外翻。

Photographs taken before surgery showing severe valgus deformity in both knees.



手術完成後的相片，雙膝外翻已經矯正。

Photographs taken after surgery showing severe valgus deformity in both knees were corrected.



手術後一年，下肢位置正常，膝關節疼痛已經消除，走路比以前輕省。

Photographs taken one year after surgery. Alignment of lower limbs normal. Bilateral knee pain subsided. Gait much improved.

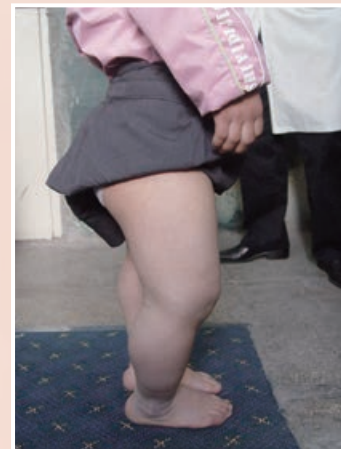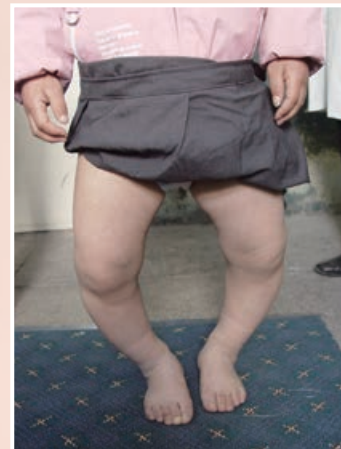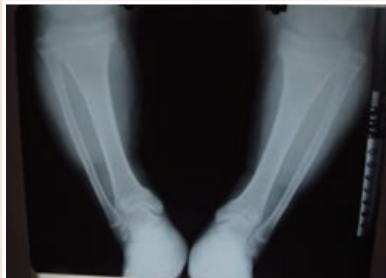
K 018

軟骨發育不全症、雙側膝關節內翻

Achondroplasia,
Bilateral Genu Varum


一位河南的高中女生，患有軟骨發育不全症，上下肢都短小，雙膝內翻及走路時疼痛。

A high school female student from Henan. She had achondroplasia which led to short upper and lower limbs and bilateral genu varum deformities. Patient also had knee pain on walk.



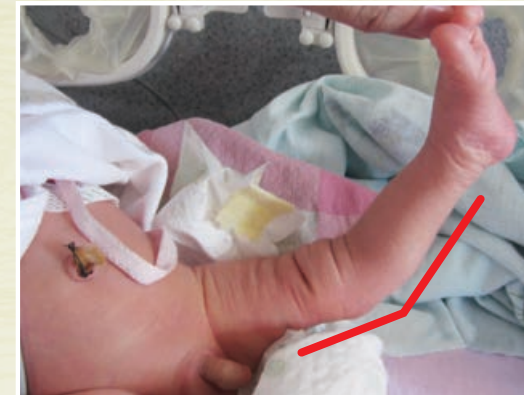她接受了雙側脛骨截骨手術，兩個下肢位置已經恢復正常，膝關節疼痛亦消除了。兩年後覆診，她帶著興奮的心情告訴我們，她已經被大專錄取讀藥劑學。

Two years and two osteotomies of the tibia later, the alignment of both lower limb is normal. The knees are pain free. She told us with a happy satisfying expression on her face that she was accepted by a pharmacy college.



先天性膝關節脫臼

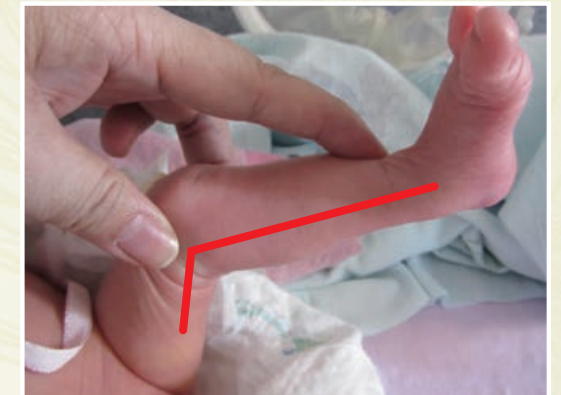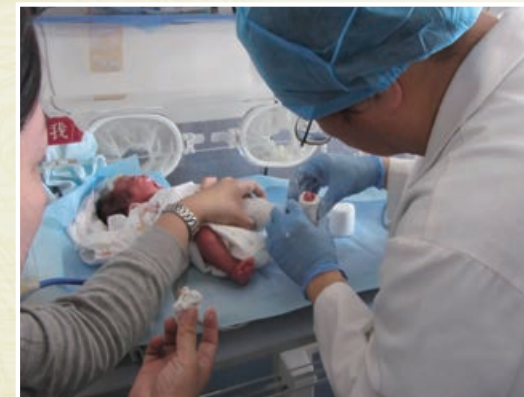Congenital Dislocation of Left Knee



初生嬰兒，出生後發現左膝關節脫臼並往前翻。

Congenital anterior dislocation of the left knee noted on a newborn.

用石膏把左膝關節固定在正常位置。
maintain the normal alignment of the knee.

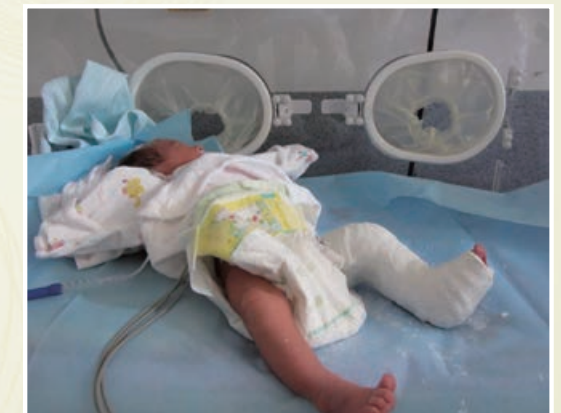

左膝關節復位後回復正常形狀。

Normal alignment of the left knee restored after close reduction.

需要用石膏固定兩個月，其間每星期更換新石膏，兩個月後膝關節恢復正常功能。

Immobilization of the knee for 2 months by plaster was needed. The cast was changed weekly. The knee restored normal function after casting.

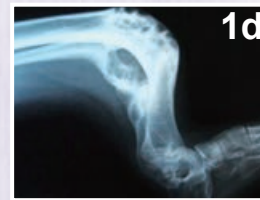
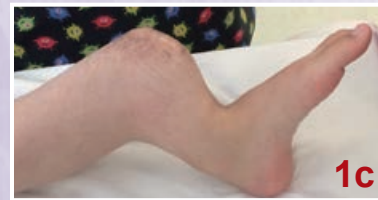
K 019

K 020

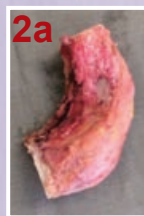左脛骨牙釉質瘤

Adamantinoma Left Tibia

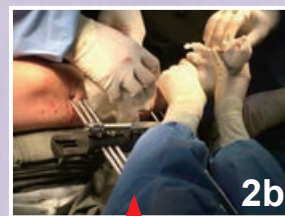


1a - 1d 17 歲女病人左小腿骨患有腫瘤，骨頭變形，走路困難，而且腫瘤亦有可能轉為惡性。

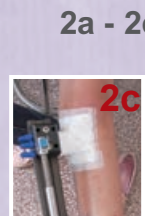17 year old lady with tumor in the leg bone. The bone is deformed and there is chance of turning into malignancy.



腫瘤
Tumor

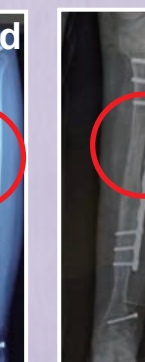
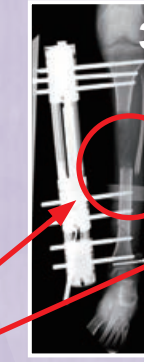
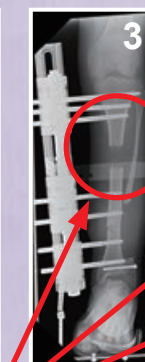
外固定支架
External
Fixator



2a - 2c 手術將腫瘤及部份小腿骨切除。因為左側小腿比較短，故在骨上安裝了外固定支架以便把小腿延長。

The tumor and a segment of the leg bone was excised. Since the left leg is much shorter, an external fixator was applied for lengthening of the leg.



骨頭已
延長並癒合
Bone lengthened
& healed

小腿骨漸漸地延長
Gradual
lengthening of
leg bone

3a - 3e 經過多個月的時間，小腿骨慢慢地被延長至正常長度。
The left leg bone was gradually lengthened to its normal length in several months.

小桃是大理的一位姑娘，當她第一次到天鄰門診時，大家都因為她左小腿的變形而感到驚訝。她出生時是正常的，但左側脛骨患上一種罕見的腫瘤，稱為脛骨牙釉質瘤，令骨頭慢慢變形，最後變成 90 度向後屈曲，引致她走路困難。

雖然生長緩慢，但這是一個惡性的腫瘤，可以擴散及導致生命危險。要徹底治好這腫瘤，需要把它完全切除，這樣患者的脛骨就會短了很多，補救的方法就是把骨頭慢慢拉長，直至達到正常的長度為止。骨頭延長手術是一個漸進式的治療方法，骨頭每天只可以拉長不超過一毫米，而且骨頭癒合的時間很長，需要幾個月，甚至一年。這種手術不可能在天鄰手術隊短短兩星期的時間內完成，後來天鄰聯絡上香港根德公爵夫人兒童骨科醫院，它們願意為病人提供手術及住院服務，費用由醫院的一個基金負責。此外，天鄰的香港義工亦樂意協助照顧小桃，於是，小桃在母親陪同下到香港就醫。

小桃的手術非常順利，腫瘤完全切除，她的脛骨慢慢被延長至正常長度，又保持了關節的活動能力，長期康復後走路姿勢正常。小桃個案的成功，是一班醫護人員、義工、病人和家屬的合作成果，亦見證了神豐富的恩典。

When Xiao To, a native of Dali, first came to our orthopaedic clinic, many were surprised by the severe deformity of her left leg. She was born normal. However, she developed a rare tumor call adamantinoma in her left tibia. It caused the bone to gradually deform. Eventually the bone was distorted 90 degree backward causing difficulties in walking.

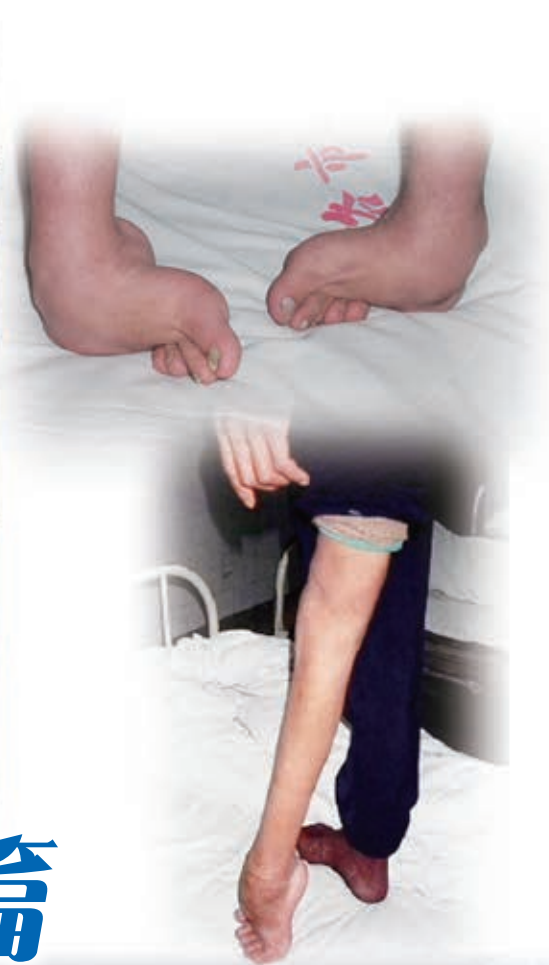Although the tumor grew slowly, it was malignant and could be fatal. A large section of the bone had to be removed. This led to significantly shortening of the left leg. In order to compensate for the shortening, the bone was lengthened. Lengthening of bone can only be done gradually. Not more than 1 mm of the bone was elongated per day. The procedure was too complicated to be done in a 2-week medical mission. Eventually we liaison with the Duchess of Kent Children Orthopaedic Hospital in Hong Kong. They were willing to accept the patient for surgery and hospitalization. The expenses were covered by a grant from the hospital so that Xiao To and her mother were able to travel to Hong Kong for treatment. HIS Foundation volunteers also assisted in taking care of Xiao To during her stay in Hong Kong.

The surgery went smoothly with complete removal of tumor. Xiao To's leg bone was gradually stretched to its normal length. The range of motion of the joints were well preserved. After a long rehabilitation, her gait is normal. The success of this case is the results of combined efforts of medical staff, volunteers, patient and family. It is also a testimony of grace by Our Lord.



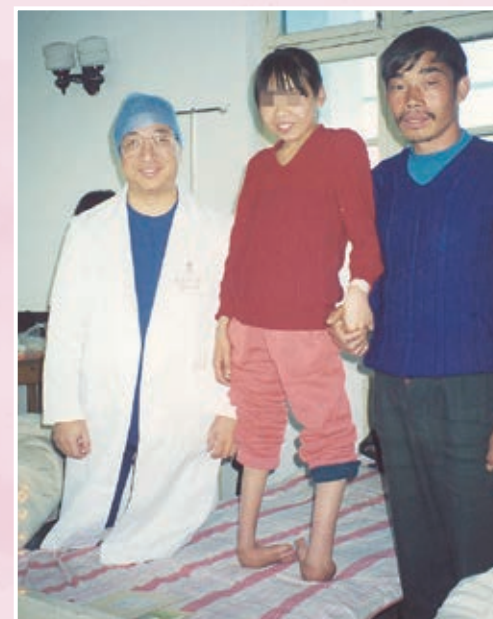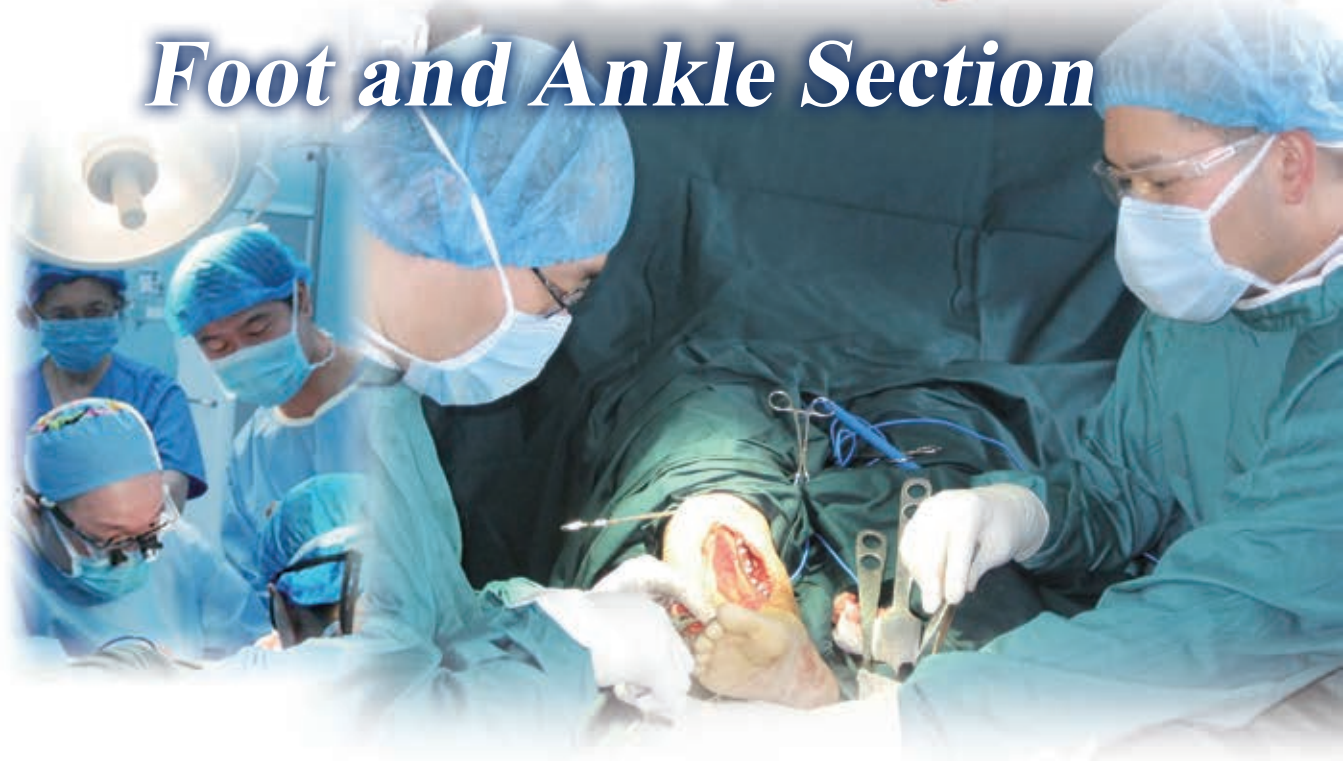4a-4c 小腿骨已延長及癒合，能正常地走路。
The left leg is lengthened and healed. Gait normal.

K 021

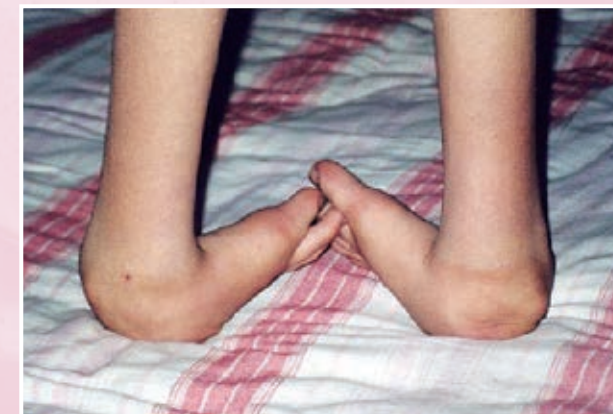

踝關節及腳部篇

Foot and Ankle Section

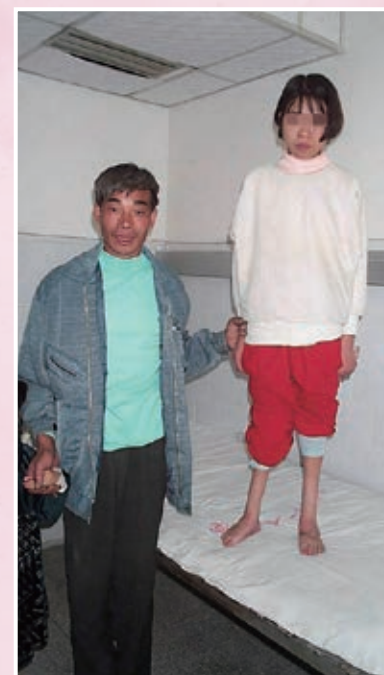

先天性雙側馬蹄內翻 Bilateral Congenital Clubfoot

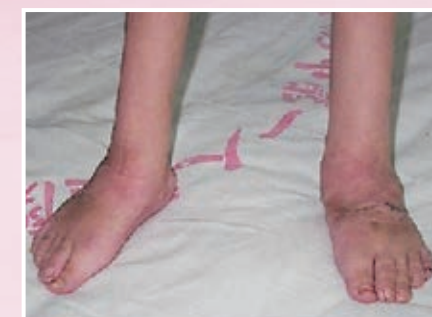

一位 12 歲河南農村少女，患先天性雙側馬蹄內翻，雙腳嚴重變形，站立時用腳背著地，穿鞋及走路十分困難。接受了雙側鬆解及三關節融合手術後，足部位置大大改善。病人的妹妹也患上先天性馬蹄內翻（參考下一位病人）。

A 12-year-old girl from rural Henan. She had bilateral congenital clubfoot. Both feet were severely deformed so that on standing patient was bearing weight on the dorsum of the feet. Wearing shoes and walking were very difficult. After soft tissue releases and triple arthrodeis surgeries, the position of both feet are much improved. Patient's younger sister also suffered from congenital clubfoot (see next patient).



手術後
After Surgery



F 001



手術後六年去探訪病人，她和妹妹走動自如。因為這次醫治的經歷，病人和家人信了主，家裡有很多基督教的裝飾。病人還唱聖詩給我們聽。

HIS Foundation team paid home visit six years after surgery. Patient and her younger sister walked very well. Due to this experience of healing, patient and all her family members became Christians. There were many decoration at home with Christian themes.



病人在唱聖詩。
Patient was singing hymn.

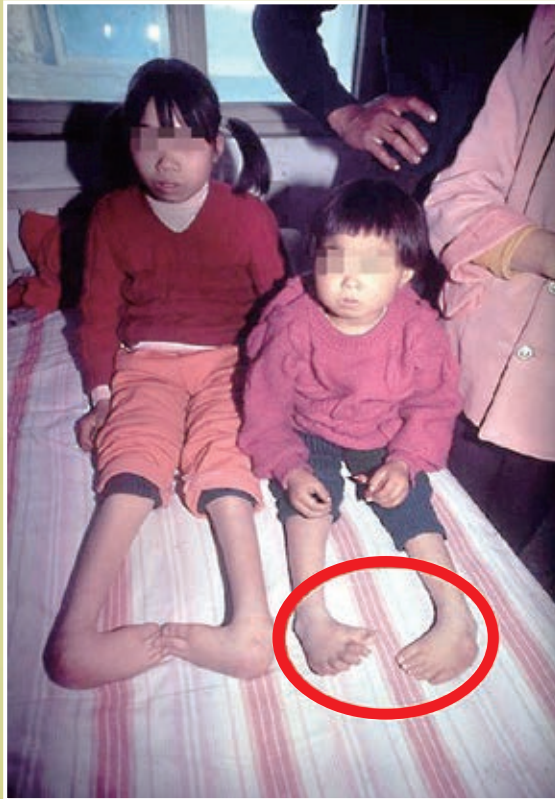

21 年後再探訪病人，她已經成家立室，並育有兩個年幼孩子。病人依然走路自如，但她喜歡穿鞋子行走，赤腳走路容易引起疼痛。

21 years later, HIS Foundation team visited patient again. She is married with two young children. She is still able to walk with little limitation. However, she prefers to wear shoes on walking, otherwise may have pain in her feet.



F 001



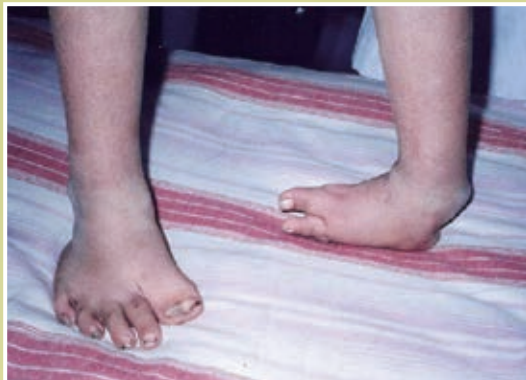先天性左側馬蹄內翻 右足多趾（大腳趾） Congenital Left Clubfoot Duplicated Right Big Toe

一位 5 歲的小女孩，出生時患有左足馬蹄內翻，右足有兩隻大腳趾。她的姊姊有先天性雙足馬蹄內翻。

A 5-year-old girl born with left clubfoot and duplicated right big toe. Her older sister had bilateral congenital clubfoot.

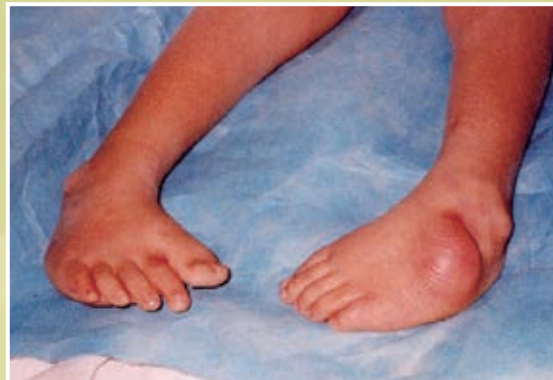站立時左脚用腳背負重。留意右側大姆趾顯示多趾畸形。

On standing, the left clubfoot was weight bearing on the dorsum. Note the duplicated right big toe.



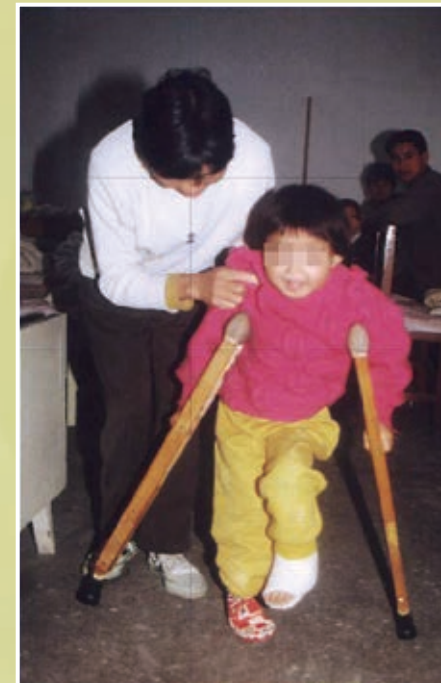手術開始前拍照。左側腳背顯示負重部位有很厚的胼胝。

Photo taken before left foot surgery. The swelling over the dorsum of the left foot was due to weight bearing.



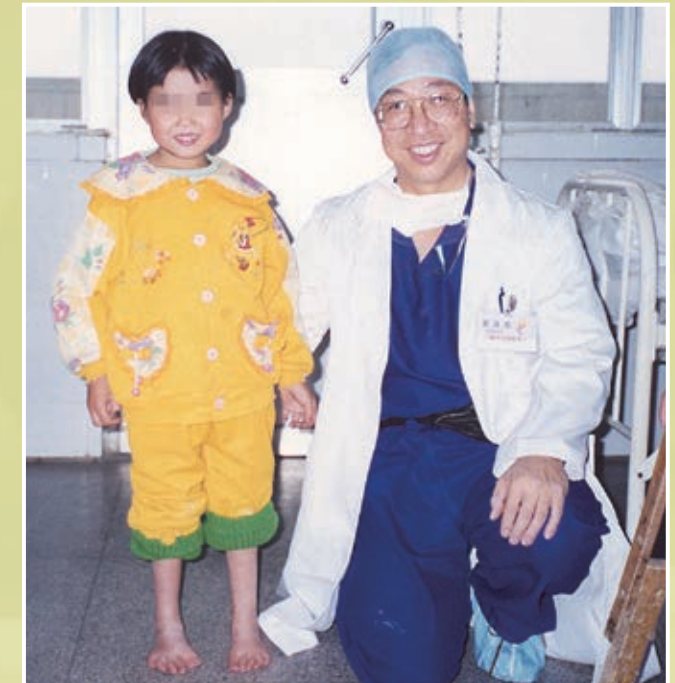孩子很可愛，手術隊員都喜歡跟她拍照。

Patient was lovely. Many surgery team members liked to have photos with her.



左腳手術後，病人在學習用拐杖走路，母親在旁鼓勵。

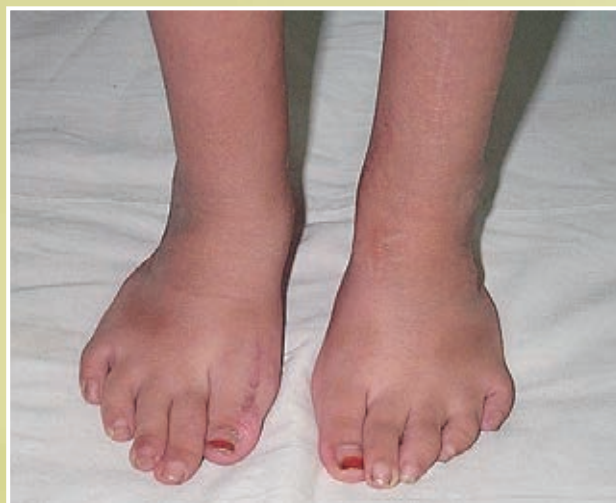Patient learning to walk with crutches after left foot surgery. The mother was encouraging her.



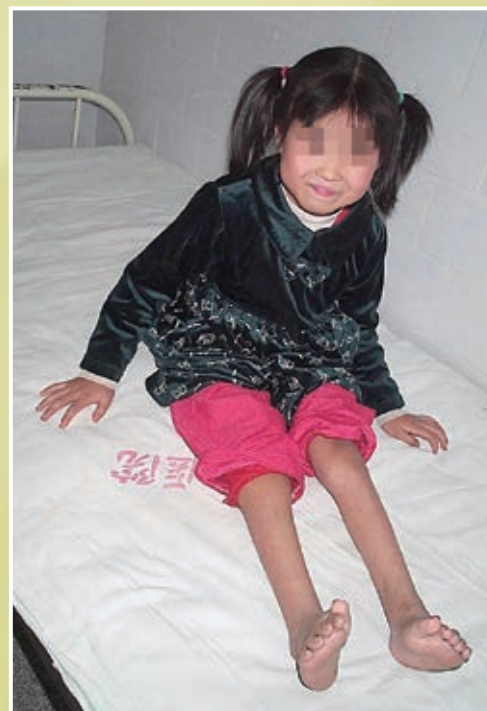左腳手術後已經矯正。第二年回來準備接受切除右足多趾手術。

The left foot was corrected after surgery. Patient returned the next year for excision of extra digit on the right foot.

F 002



雙足手術完成後外貌恢復正常。
Both feet restored normal alignment after surgeries.



手術後 21 年，患者已經成家立室，並育有兩名子女。患者走路正常。

21 years after surgery, patient is married with two kids. She is walking normally.



手術後 6 年，醫療隊隊員探訪病人，他們已經全家信主。

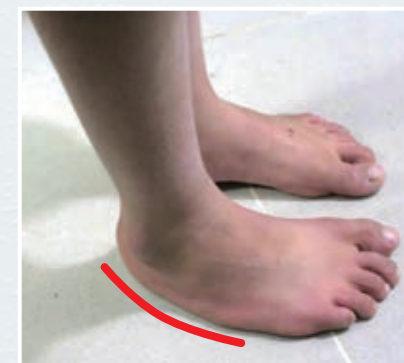Six years after surgery, medical team members visited old patients at their home. The whole family became Christians.

F 002

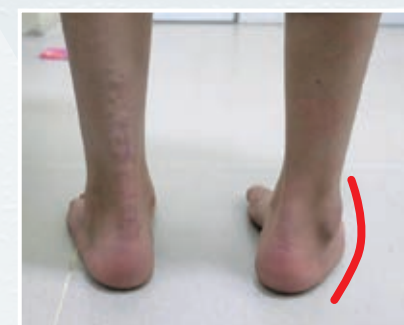

先天性右足馬蹄內翻

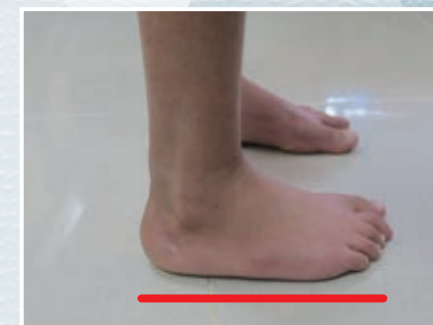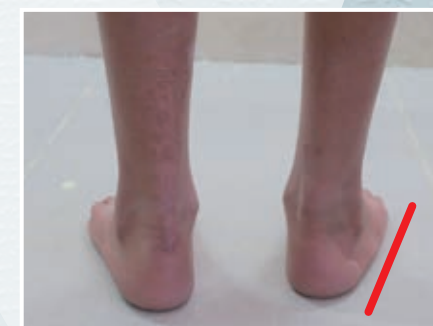Right Congenital Clubfoot



手術前 Before Surgery



手術後 After Surgery



這位八歲的庫爾德斯坦孩子，患有輕微先天性馬蹄內翻，走路時主要用腳外側負重。手術後右腳已經矯正，負重亦正常。

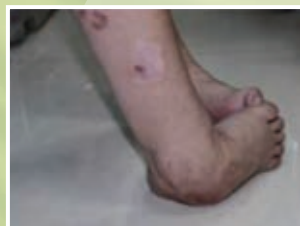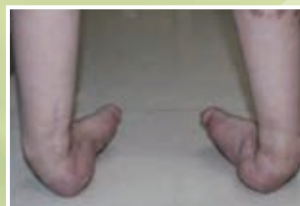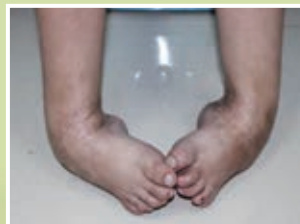An eight-year-old Kurdistan boy with mild congenital clubfoot. He was weight bearing mainly on the lateral border of the foot. The foot was fully corrected after surgery and weight bearing was normal.



F 003

脊椎裂症、雙側內翻高弓足

Myelomeningocele, Bilateral Cavovarus



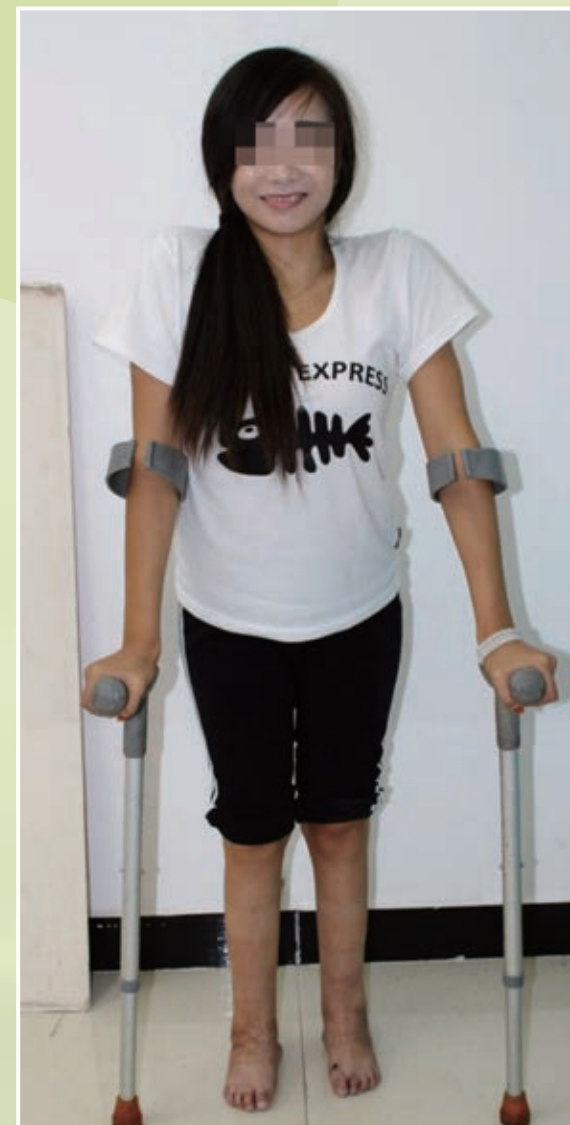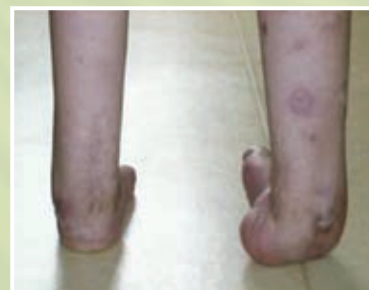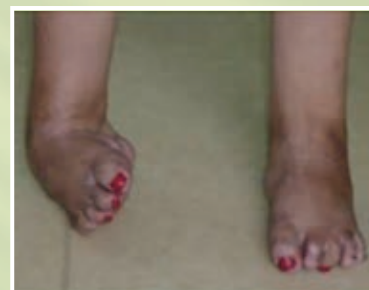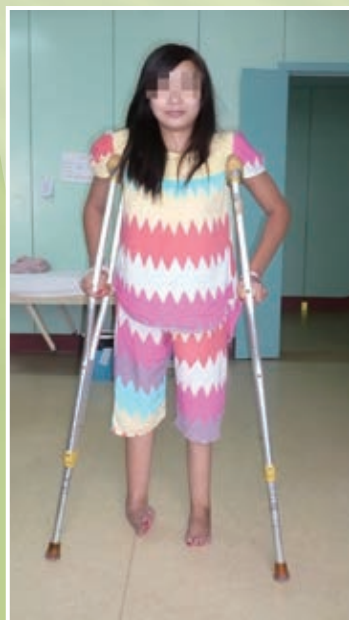19 歲患脊椎裂症女病人，雙足內翻、站立非常困難，如果不穿上鞋子，便不能走路。曾在其他地方接受手術，效果不理想。

19-year-old lady with myelomeningocele. Had severe cavovarus deformity in both feet. Unable to stand without shoes. Had surgeries done elsewhere with unsatisfactory results.

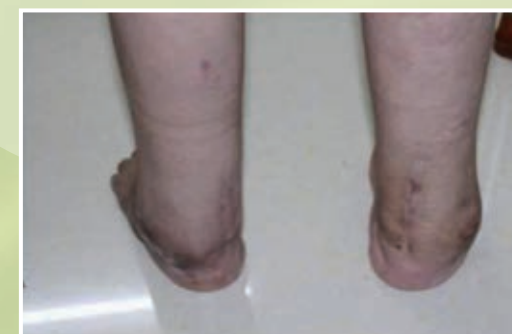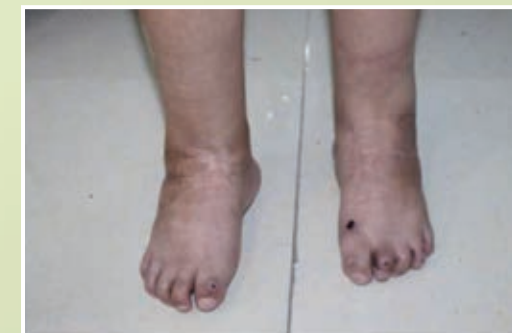手術前 Before Surgery

左腳手術後已經矯正，病人可以用拐杖行路，比較以前容易。

Left foot was corrected after surgery. Walking with crutches became much easier.



手術後 After Surgery



在天鄰接受雙足手術後已經完全矯正，患者不穿鞋子亦可以用拐杖走路。

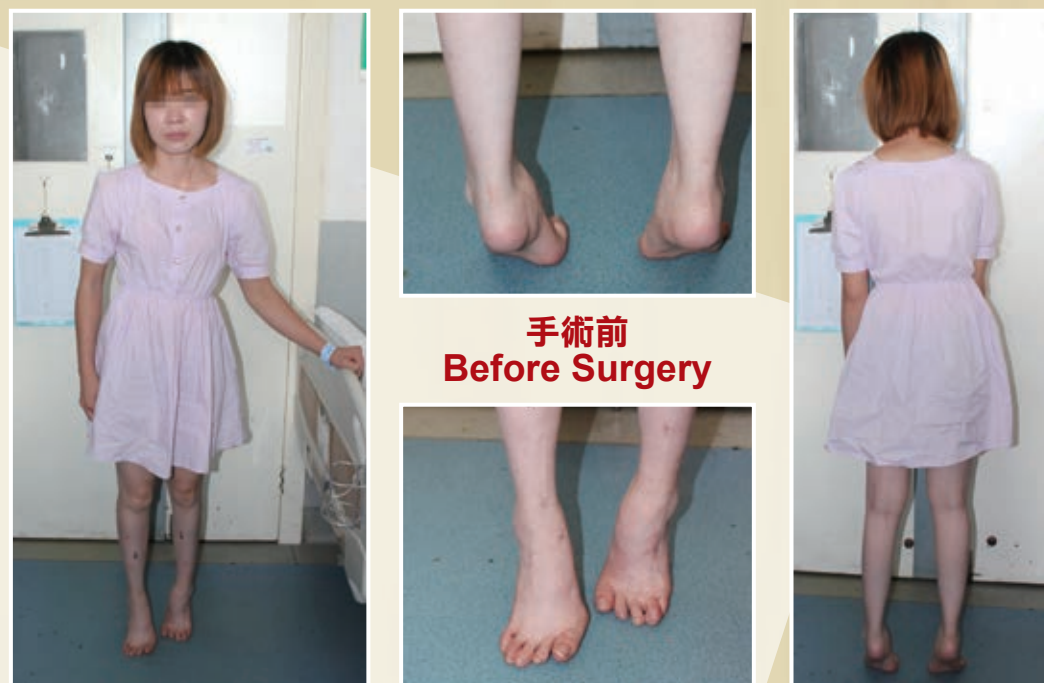After surgeries done by HIS Foundation, both feet are well corrected. Patient is now able to walk with forearm crutches without wearing shoes.



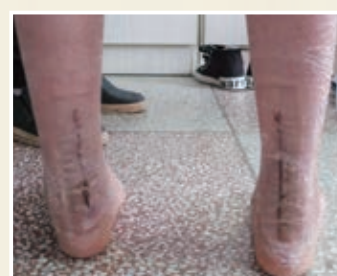手術後一年，患者結婚。

Patient got married one year after surgery.

F 004



手術前
Before Surgery



手術後
After Surgery

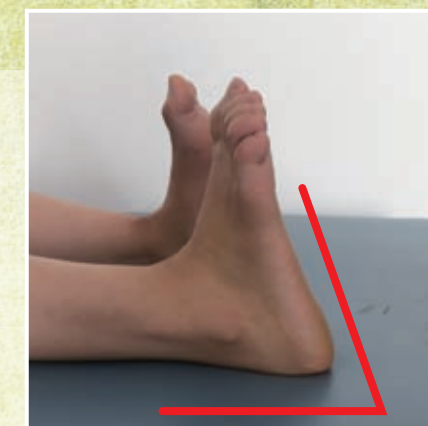
腦癱、雙側馬蹄足

Cerebral Palsy
Bilateral Equinus

一位患有腦癱的女病人，雙側跟腱收縮，雙足不能平放地上，站立及走路均用腳尖，步履不穩，時常要扶著東西以作平衡。手術後雙足均能放平走路，不用攙扶，對生活自理很有幫助。

A lady with cerebral palsy. Both feet in equinus and had difficulties with balance on standing and walking. After surgery both feet can be put flat on the floor. Thus, both walking and balance improve significantly, and she can take care of herself more independently.

F 005



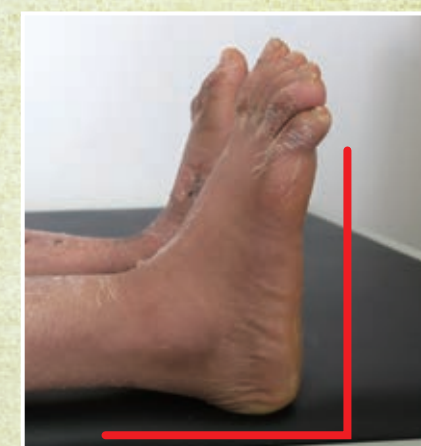手術前 Before Surgery

脊柱裂症、雙側仰趾足

Myelomeningocele, Bilateral Calcaneal Deformity

病人患先天性脊柱裂症，導致肌肉不平衡，雙足向上翻 25 度。走路時不穩定，而且腳跟因受力太大，容易引致皮膚破損。病人接受了肌腱轉移手術後，雙足位置恢復正常，走路比以前輕省。

Patient was born with myelomeningocele leading to muscle imbalance in both feet. It caused bilateral calcaneal deformities of 25 degrees which contributed to unsteady gait. The increased pressure over the heels predisposed to skin ulceration. After tendon transfers, the normal alignment of both feet are restored with improved gait.



手術後 After Surgery



F 006

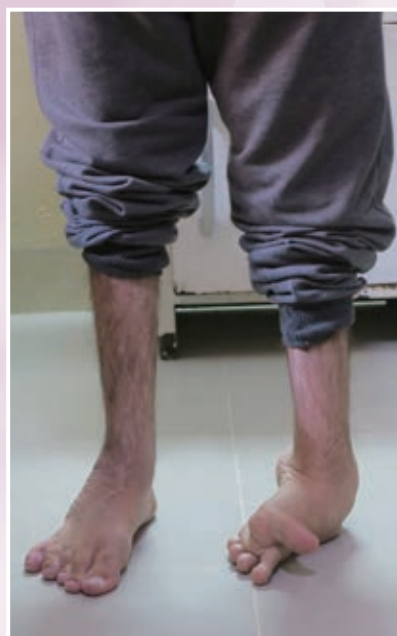
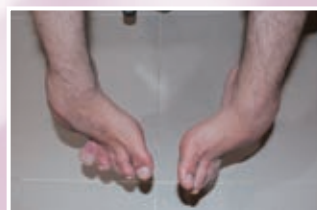
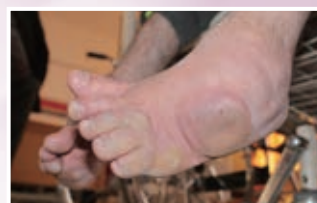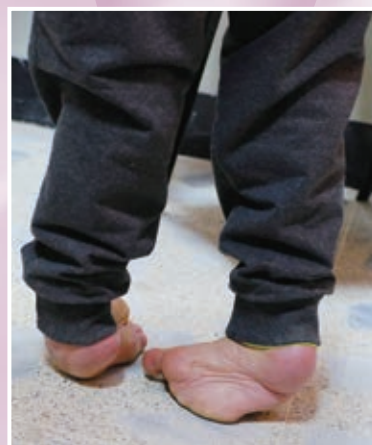先天性雙側馬蹄內翻

Bilateral Congenital Clubfoot

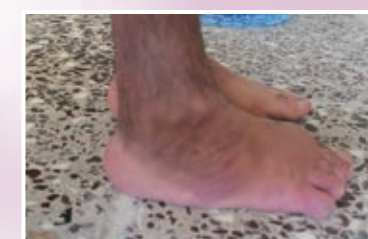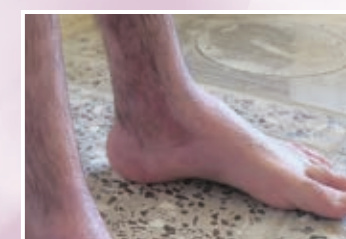
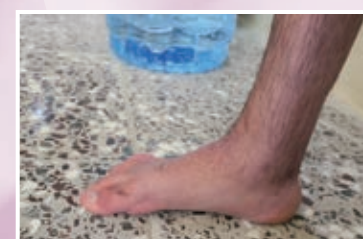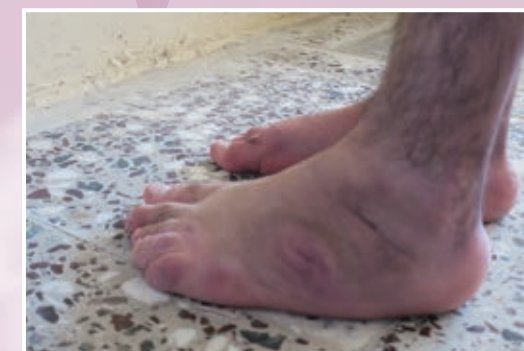
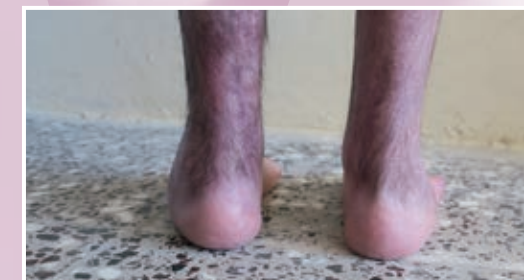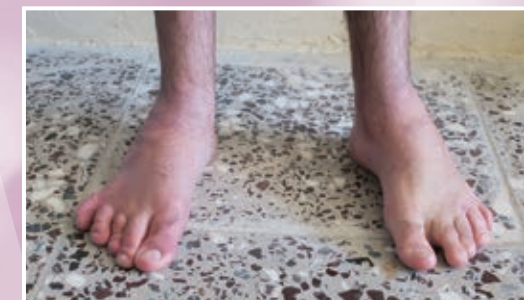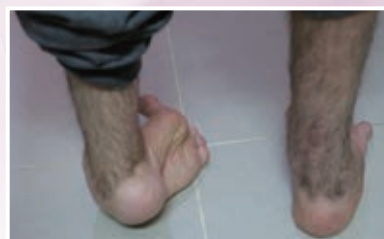一位 39 歲雅茲迪男士，患先天性雙側馬蹄內翻，雙足嚴重變形並且疼痛，站立不穩，走路非常困難。

A 39-year-old Yazidi man with bilateral congenital clubfoot. Both feet were grossly deformed and painful. Unstable on standing. Walking was very difficult.



右腳做了三關節融合手術，位置已經恢復正常，疼痛大大減少。

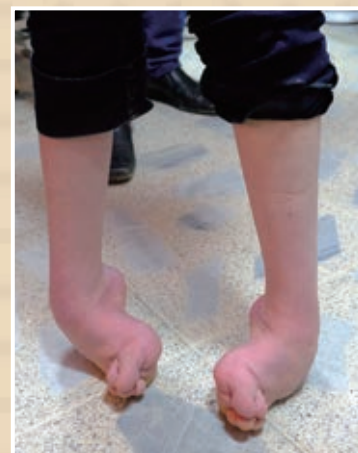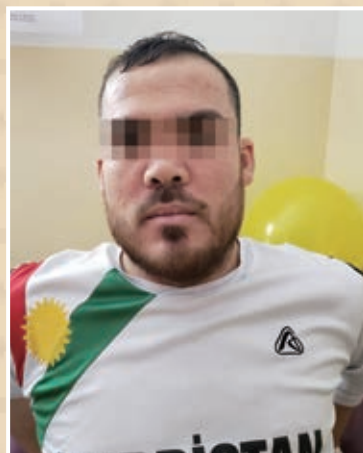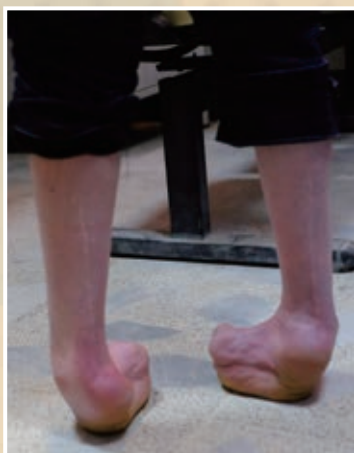Triple arthrodesis was performed on the right foot. The alignment was normal, and pain largely subsided.



第二次手術後，左腳已經矯正，疼痛大為減少。走路時可以不用扶著東西。雙足矯正以後，病者才第一次穿上鞋子。

After the second surgery, the deformities in the left foot were corrected. Pain subsided. Patient was able to walk without any support. After both feet were reconstructed, for the first time in his life, he was able to wear shoes.

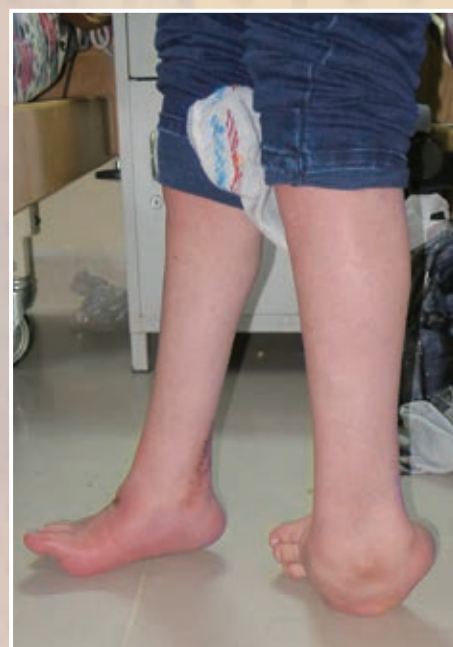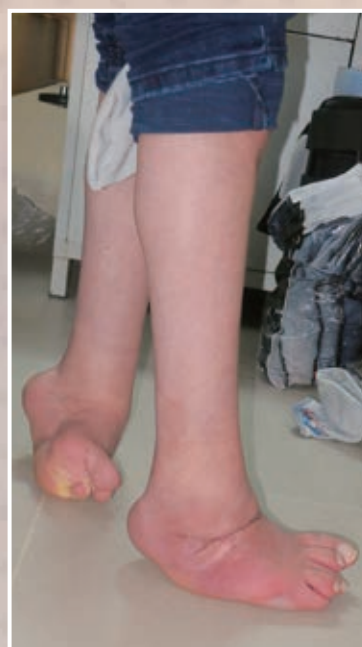F 007



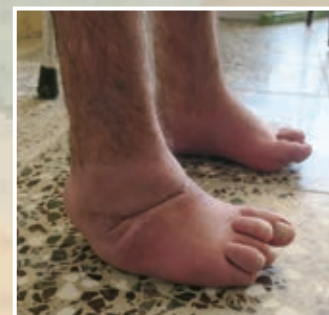先天性雙側馬蹄內翻 Bilateral Congenital Clubfoot

一位 24 歲的雅茲迪男士，患先天性雙側馬蹄內翻，穿鞋子和走路都非常困難。

A 24-year-old Yazidi man with bilateral congenital clubfoot. Wearing shoes and Walking were very difficult.

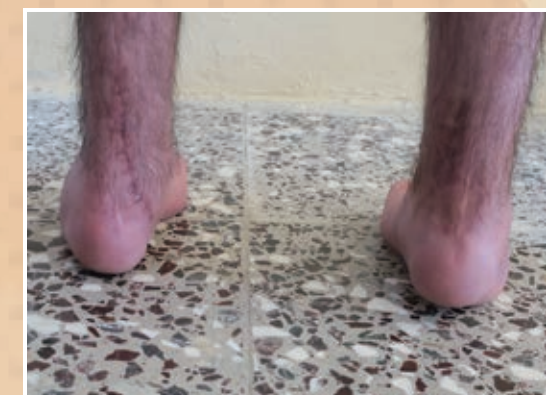
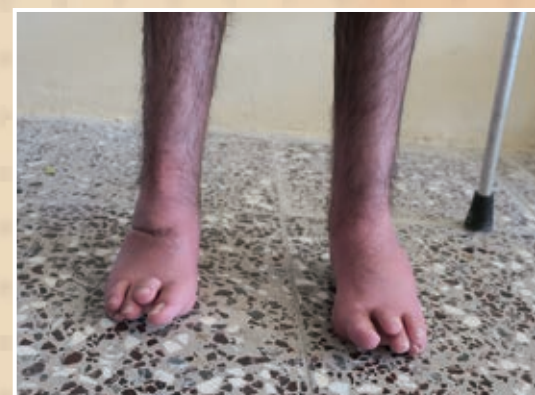
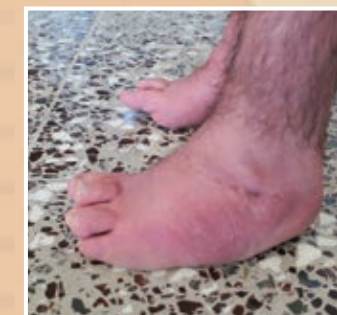右腳手術後位置已有很大改善。
Alignment of the right foot improved after surgery.



第二次手術後左腳有很大的改善，病人可以穿鞋子及用一支拐杖走路。

In the second surgery, the left foot was corrected. Patient is now able to wear shoes and walk with a cane.



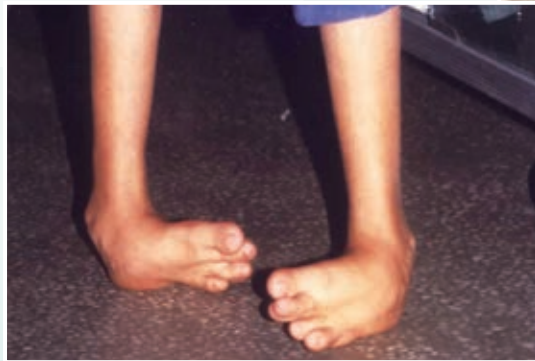F 008

先天性雙足馬蹄內翻

Bilateral Congenital Clubfoot

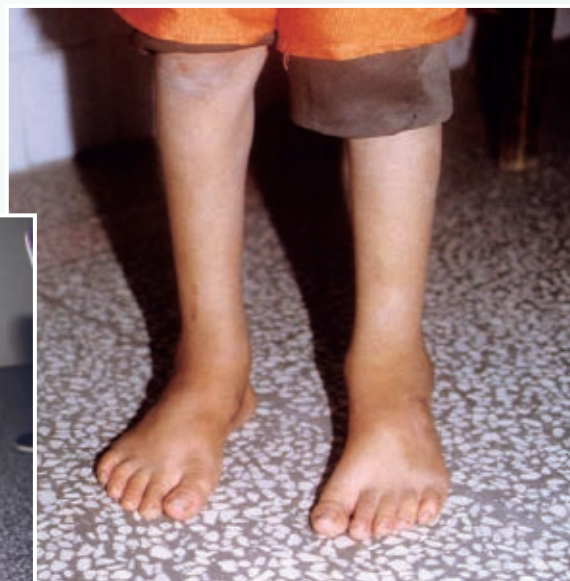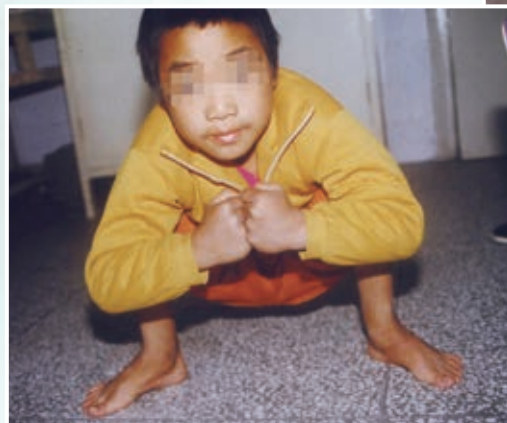一位河南的 8 歲男童，患有先天性雙足馬蹄內翻，隨著孩子成長，雙足變形越來越嚴重。

An 8-year-old boy from Henan was born with bilateral congenital clubfoot. Both feet became more and more deformed with growth.



手術後一年，雙足已經回復正常位置。

One year after surgery, both feet restored normal alignment.

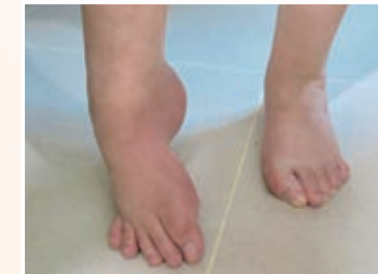

F 009

進行性腓骨肌萎縮、右側內翻高弓足

Charcot-Marie-Tooth Disease, Cavovarus Right Foot

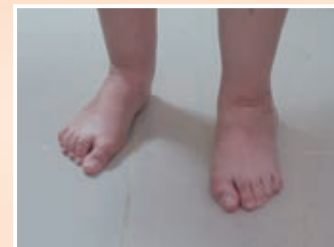手術前
Before Surgery



22 歲女士，患遺傳病進行性神經性腓骨肌萎縮症，引致右高弓足萎縮無力及內翻，站立及走路均需要攙扶。

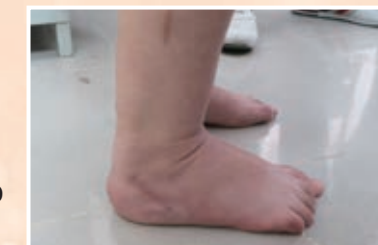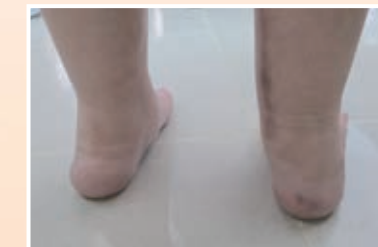A 22-year-old with progressive genetic condition Charcot-Marie-Tooth Disease. Had right cavovarus deformity associated with weakness and muscle wasting. Had to hold onto objects on standing and walking.

手術後
After Surgery



手術後右腳位置正常，患者能穿著支具自行走路。

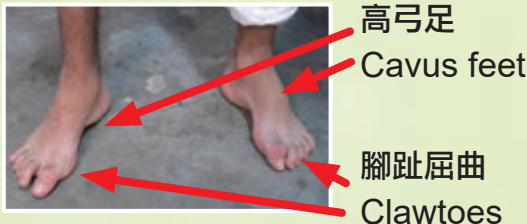After surgery, the alignment of the right foot is normal. Patient, on wearing a brace (AFO), is able to walk independently.



F 010

進行性神經性腓骨肌萎縮
雙足高弓、爪子腳趾
Charcot-Marie-Tooth Disease
Cavovarus Foot with Claw toes

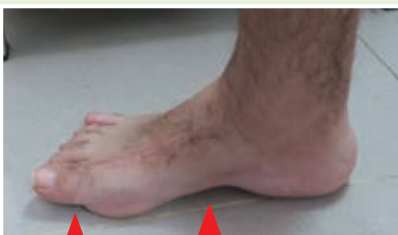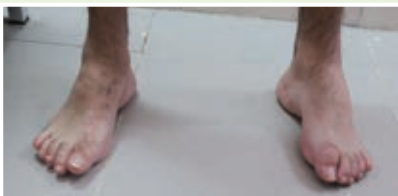雙手手趾有萎縮、
屈曲和無力情況。
Bilateral claw
fingers, wasting,
and weakness
noted.



16 歲男士，患遺傳病進行性神經性腓骨肌萎縮症，引致雙
高弓足萎縮無力，腳趾屈曲，走路不穩。


16-year-old with genetic condition Charcot-Marie-
Tooth Disease. Had bilateral cavus foot with
muscle wasting and weakness. Also has claw
toes and poor balance.

手術後
After Surgery



腳趾屈曲及高弓足已改善，
走路比較穩定。
Improvement of claw
toe and cavus deformity.
Balance improved.

右腳手術後
做物理治
療。
Physical
therapy
after
surgery of
right foot.



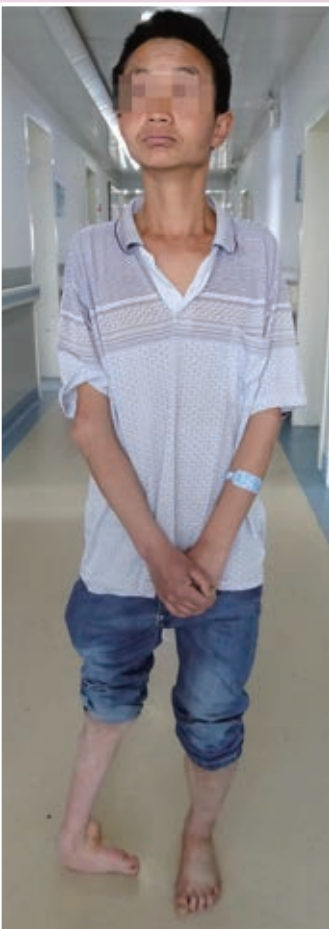* 拍照時，患者在等候做左腳手術
At time of photography, patient was waiting for left foot surgery.

F 011

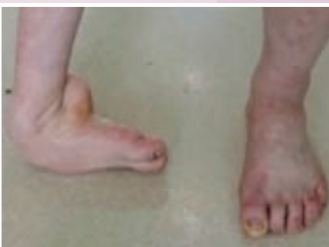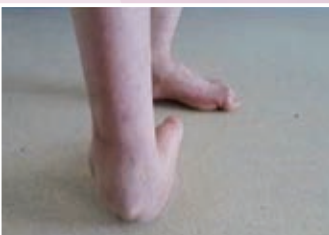右側腦偏癱、
右足馬蹄內翻
Right Hemiplegia
Right Clubfoot

31 歲大理男士，患右側偏
癱，引致右足變形，成馬蹄
內翻狀，穿鞋子及行路困
難，幸未有疼痛。手術後右
足恢復正常位置，行路明顯
改善。

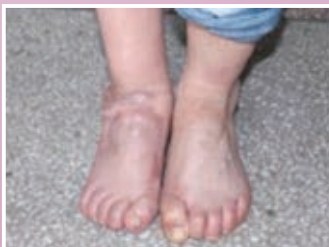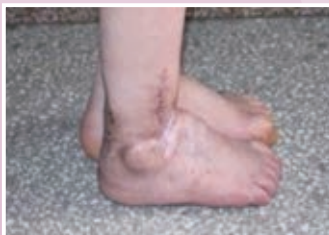A 31-year-old resident of
Dali suffering from right
hemiplegia. The right foot
was grossly deformed
with difficult in wearing
shoes and walking. Had
no pain. After surgery,
normal alignment of the
foot was restored with
improvement of gait.



手術前
Before Surgery



手術後
After Surgery



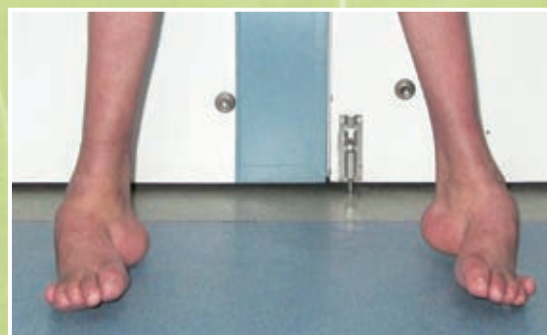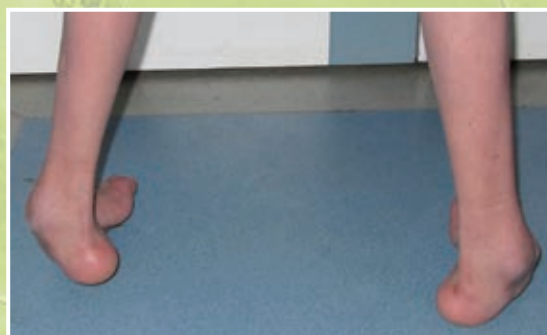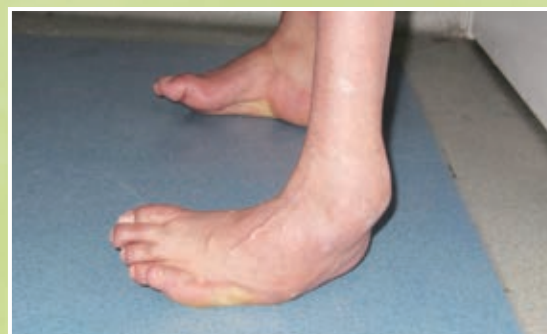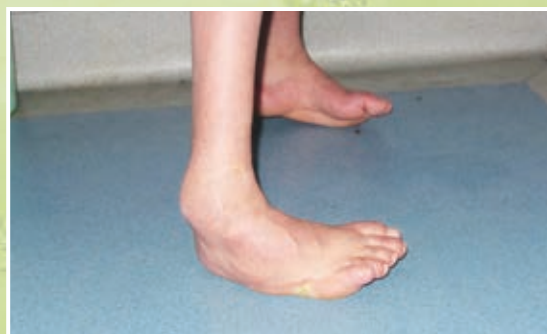F 012

進行性神經性腓骨肌萎縮症、 右側內翻高弓足

Charcot-Marie-Tooth Disease Bilateral Cavovarus

19 歲大理男士，患遺傳病進行性神經性腓骨肌萎縮症，引致雙足變形越來越嚴重，最終導致雙側高弓足，內翻，不穩，萎縮無力及內翻，站立及走路均需要攙扶，不穿鞋子，不能步行。

A 19-year-old with progressive genetic condition Charcot-Marie-Tooth Disease. Alignment of both feet were getting worse. Eventually, both feet developed cavovarus deformity associated with weakness, instablility, and muscle wasting. Patient had to hold onto objects on standing and walking. He was unable to ambulate without shoes.

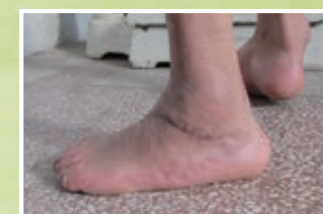
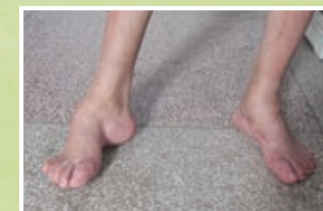
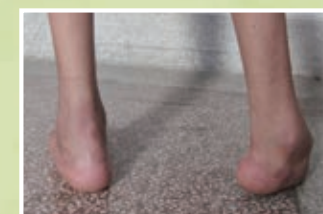站立時用腳外側負重。 Weight bearing on lateral border of both feet.



手術分兩階段進行，每次做一隻腳，左腳手術後位置恢復正常，可以平放地上，負重時受力平均，疼痛消失。

A two-stage operation plan was implemented. After the first operation, alignment of the left foot was normal. Weight bearing was even, and foot pain subsided.

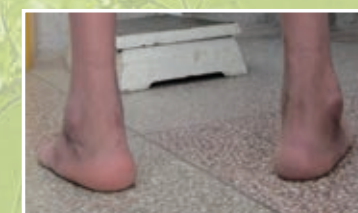
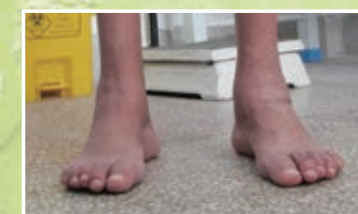


第二階段手術完成後，雙足位置正常、沒有疼痛、平穩負重，不穿鞋子亦可走路。

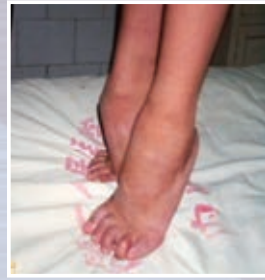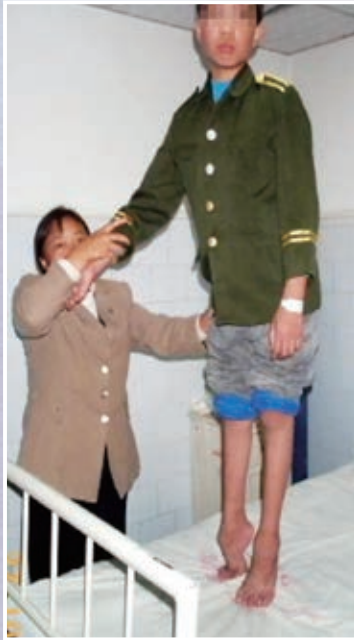After all surgeries were completed, both feet were pain free with normal stable alignment. Patient was able to walk without wearing shoes.

雙腳能平放地面。

Both feet plantigrade.



F 013

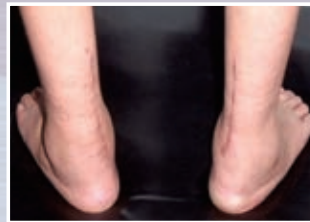
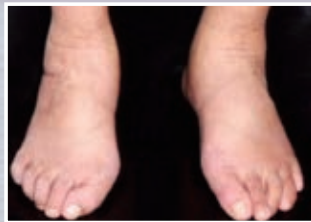
脊椎裂症、雙馬蹄足

Myelomeningocele Equinus feet

這位 11 歲的孩子，因為天生有脊椎裂症，引致雙足漸漸變形、無力。每天媽媽要背著他去學校。媽媽非常擔心，因為孩子越來越重，媽媽怕不能再背著他外出。

This 11-year-old boy was born with myelomeningocele leading to weakness and progressive deformity of his feet. Mother had to carry him to school. As he got more and more heavy, mother was concerned that she was not able to carry him much further.



手術後兩個月，雙足已經矯正，孩子開始自己走路。

Two months after surgery, both feet were well corrected. Patient started to walk independently.



這家庭因為天鄰的服務而信主。

Family learnt about Christ from HIS Foundation services and became Christians.

四年後家訪，孩子走路自如，上山比我們同工更快。

Home visit 4 years later, patient walked normally and even faster than our worker on going uphill.

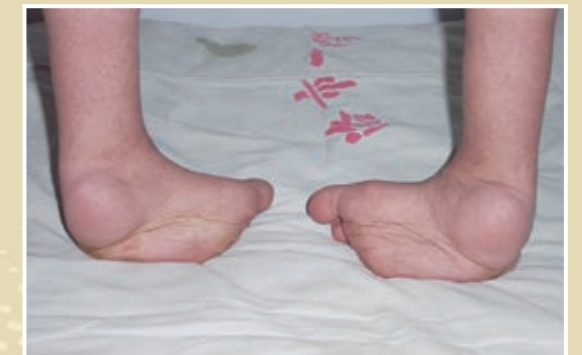
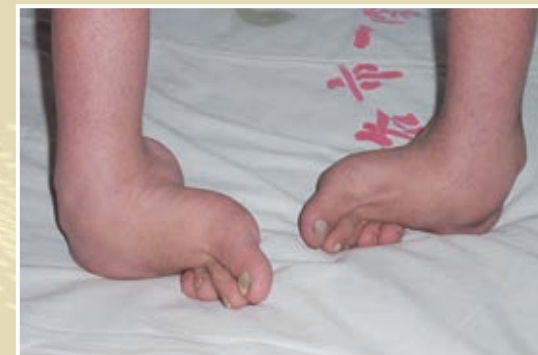
雙側先天性馬蹄內翻

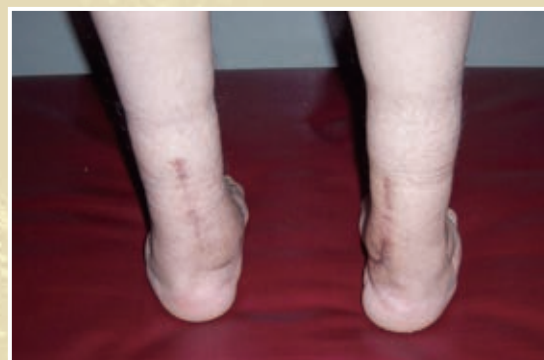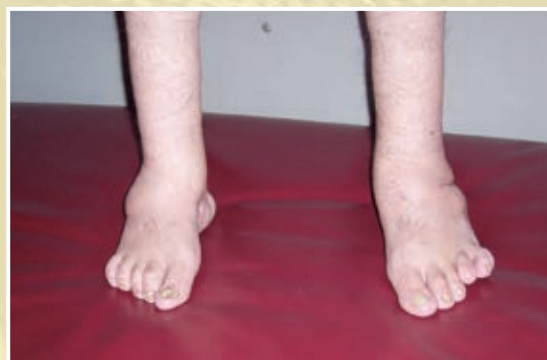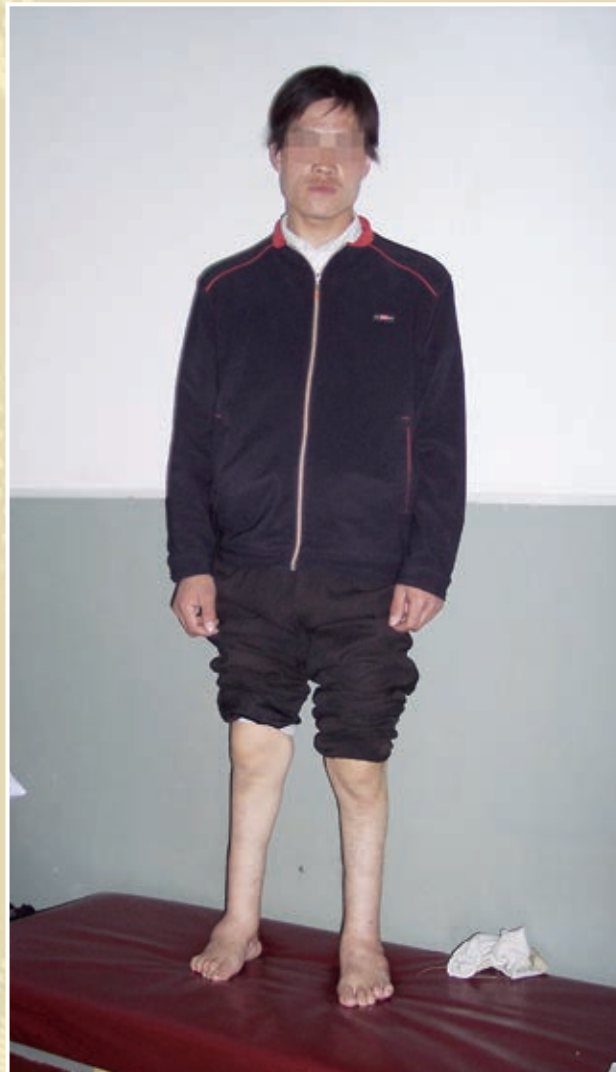Bilateral Congenital Clubfoot

一位 20 歲河南男士，患先天性馬蹄內翻，從未接受過治療，雙足隨著年齡長大，變形越發嚴重，走路時只能用腳的外側負重。

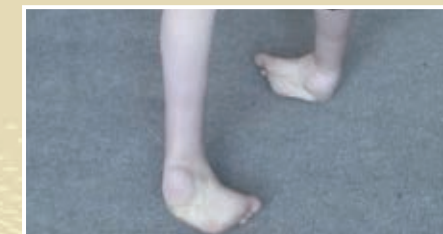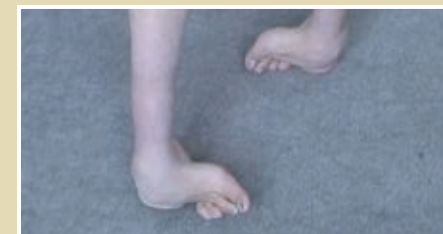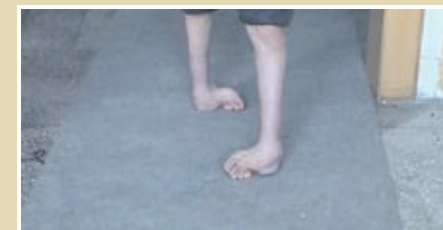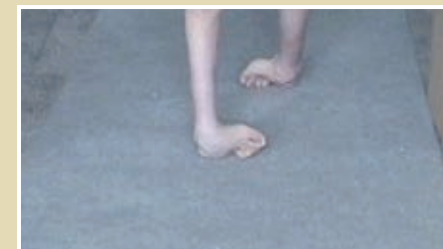A 20-year-old man from Henan. He had bilateral congenital clubfeet. As he got older, the deformities got worse. Eventually he was bearing weight on the lateral side of the feet.



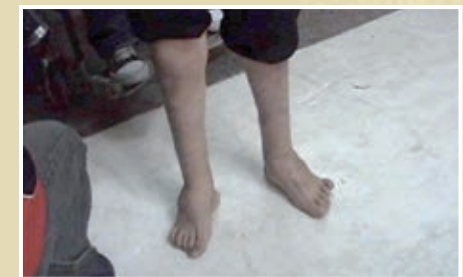
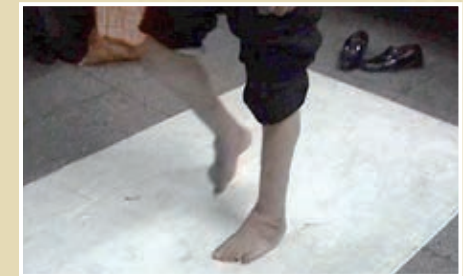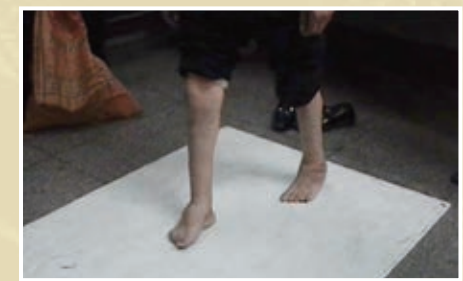F 015



雙足經過截骨及融合手術後，已經可以平放地上，走路姿勢大大改善了。
After osteotomy and arthrodesis surgeries, both feet are plantigrade. The gait is much improved.



手術前
Before Surgery



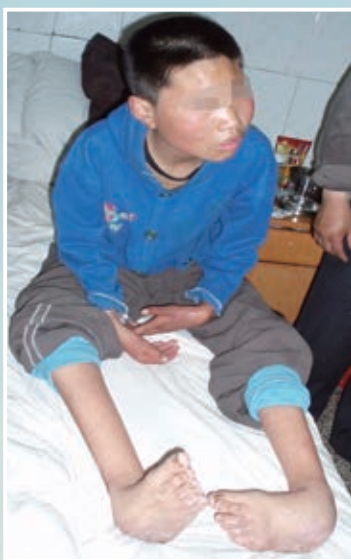手術後一年
One year after surgery

F 015

關節彎曲綜合症 Arthrogryposis

小來出生時患有關節彎曲綜合症，全身多處關節都有變形及僵硬，出生後不久就被父母遺棄，幸得好心人收養。他的雙腳用外側負重，走路時非常疼痛，如果不穿鞋子，幾乎不能步行。

Xiao Loi was born with arthrogryposis. Many joints are deformed and stiff. He was abandoned by the parents. Luckily, someone adopted him. Weight bearing of both feet were on the lateral border of the feet and were very painful. He could barely walk without shoes.



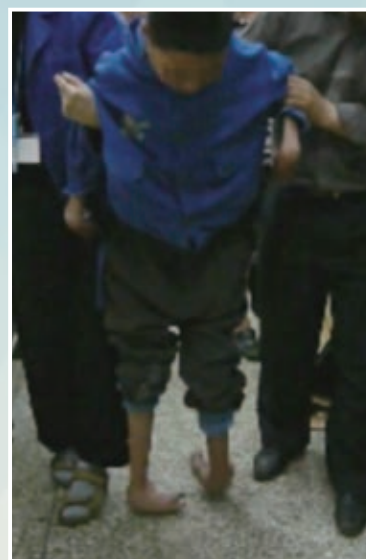雙手和雙腳都非常僵硬，缺乏活動能力。

Ankylosis in both hands and feet with lost of movement.



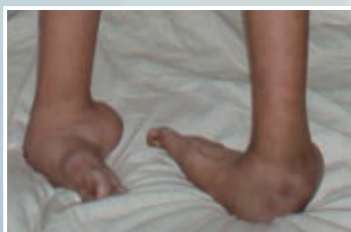站立時不穩，需要扶著東西以保持平衡。

Needed support on standing due to poor balance.



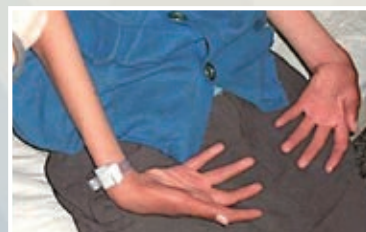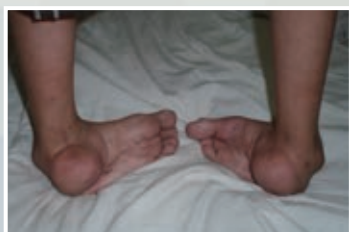
不穿鞋子走路非常疼痛及困難。

Walking bare foot was painful and difficult.



站立時，雙腳用外側負重，不能放平。

Both feet bearing weight on the lateral border on standing.



手腕及手指僵硬，缺乏活動能力。

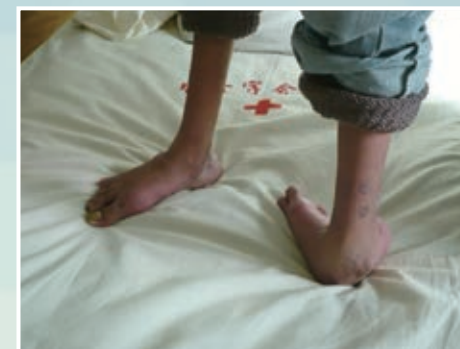The wrists and fingers are stiff.



完成右腳手術後 After Surgery on the Right Foot

右腳已經完全放平，站立和行走都不會疼痛。

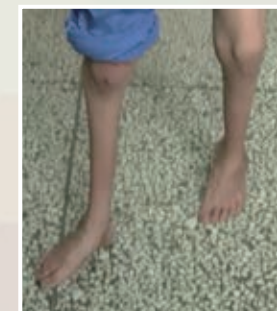Right foot is plantigrade. No more pain on standing and walking.



完成雙腳手術後 After Surgery on Both Feet

雙腳手術完成後，可以平放地上，走路自如，沒有疼痛，而且不穿鞋子亦能步行。

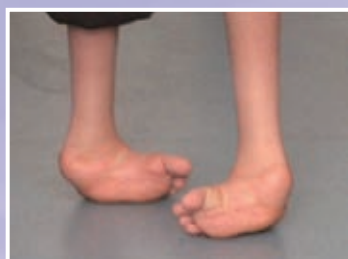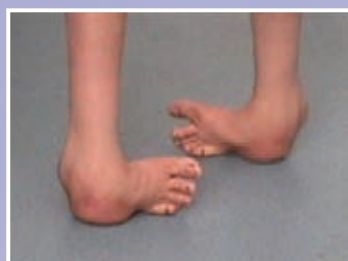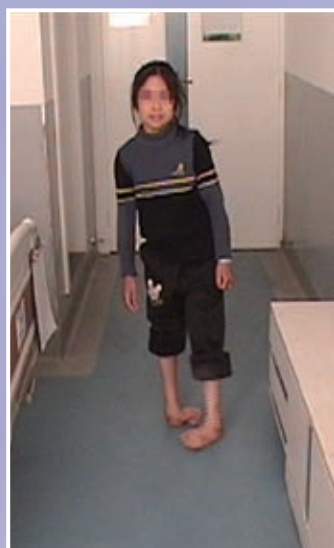After surgeries, both feet were plantigrade. There was no pain on walking, even without shoes.



小來在工廠找到工作，後來結了婚，又帶妻子來跟天鄰義工們見面。

Xiao Loi found a job in a factory. He later got married and brought his wife to come and see HIS Foundation volunteers.

F 016



一位 8 歲傈僳族女童，患先天性雙側馬蹄內翻，嚴重變形。

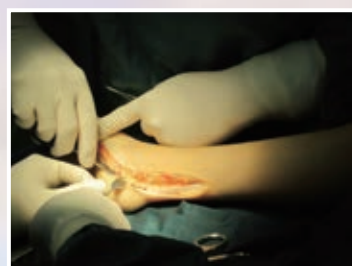
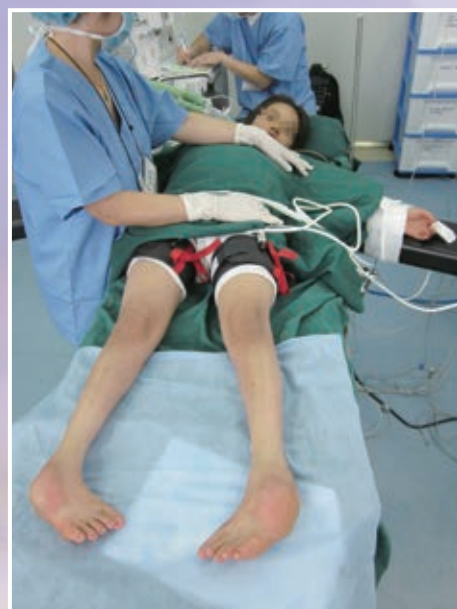An 8-year-old Lisu girl with bilateral congenital clubfoot. Both feet were grossly deformed.

雙側先天性馬蹄內翻

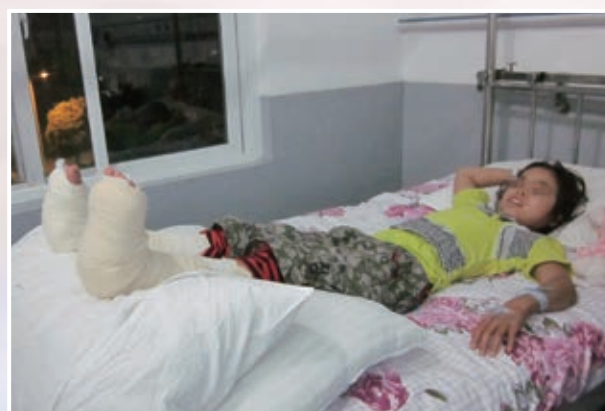Bilateral Congenital Clubfoot

手術開始前的照片，雙足均有很厚的繭皮在外側負重之處。

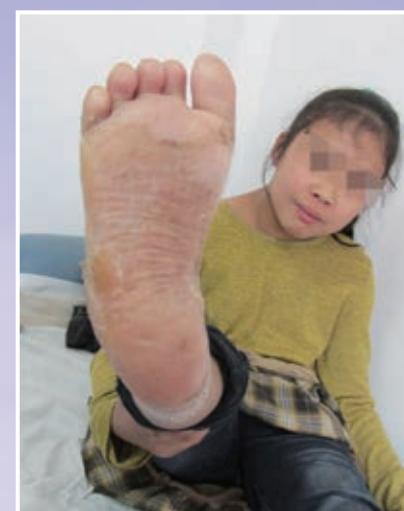Photo taken before surgery showing thick callosity over the lateral side of both feet.



手術進行中
Surgery in progress

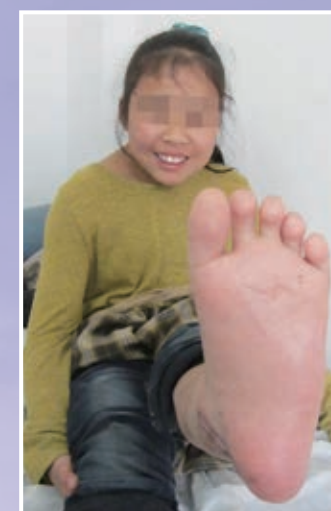

手術後，雙腳打了石膏。
After surgery, plaster was applied to both feet.



病人和家屬與醫療隊員合照。病人雙腳配了支具。

Patient and family had a photo with members of medical team. Please note that patient was fitted with a pair of braces.



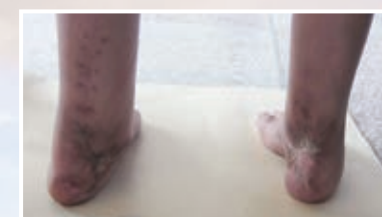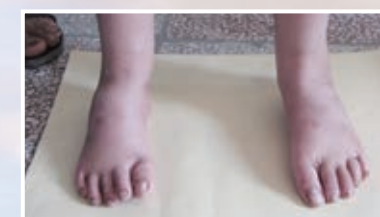手術後，雙足位置大為改善。

Alignment of both feet greatly improved after surgery.



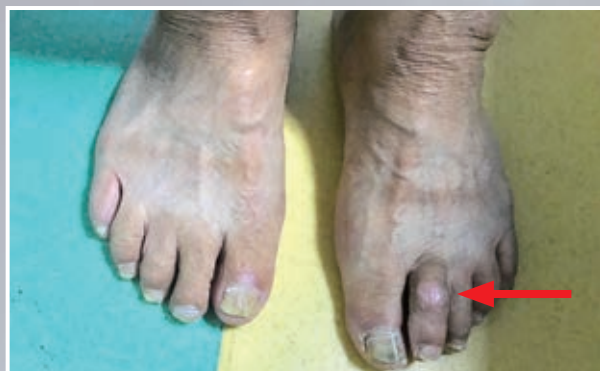康復後雙足能够平放地上，走路姿勢平穩，比手術前有所改善。病人外出走路時喜歡配帶支具。

After rehabilitation, patient's feet were plantigrade and her gait was much improved. Patient prefers to continue to wear the braces when going outside.



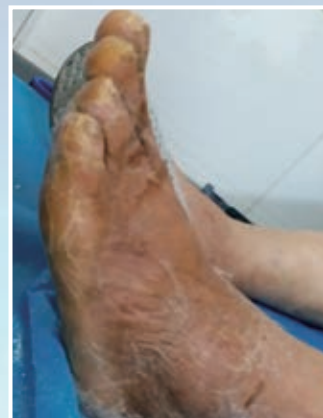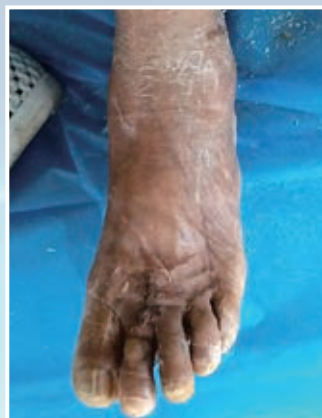F 017

腳趾退化性關節炎 Degenerative Arthritis Left Toe



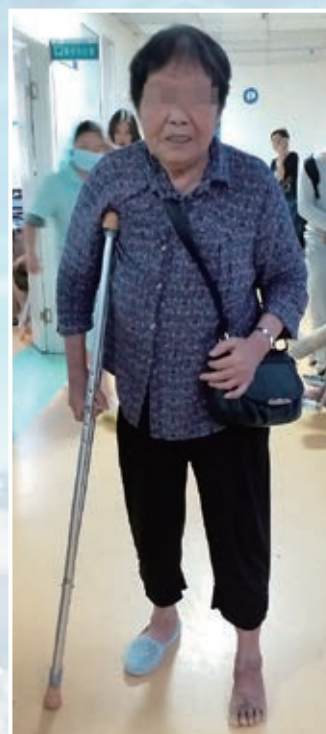一位 60 多歲的四川婦人，左側第二腳趾，因退化性關節炎，引致關節腫脹及屈曲，關節凸出，穿鞋時產生磨擦及疼痛。

A Sichuan lady in her sixties. Her second toe had degenerative arthritis leading to swelling and claw toe. The toe rubbed against the shoe and became painful.

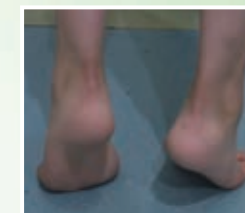
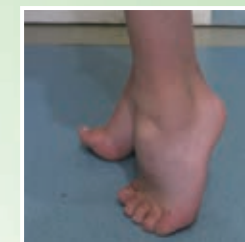
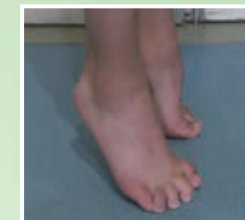手術後腳趾矯正了，沒有屈曲和凸出，穿鞋時不會疼痛。

After surgery, the claw toe and swelling were corrected. No more pain on wearing shoes.



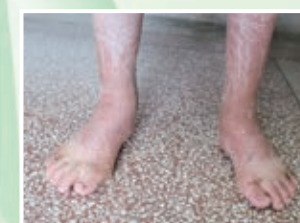
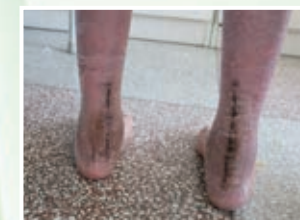F 018



腦癱、雙側馬蹄足 Cerebral Palsy, Bilateral Equinus

14 歲雲南省的男童，因為腦癱引致雙側馬蹄足，走路不穩，容易摔倒。

A 14-year-old boy from Yunnan with cerebral palsy. He had bilateral equinus deformities. He had unsteady gait and was prone to fall.



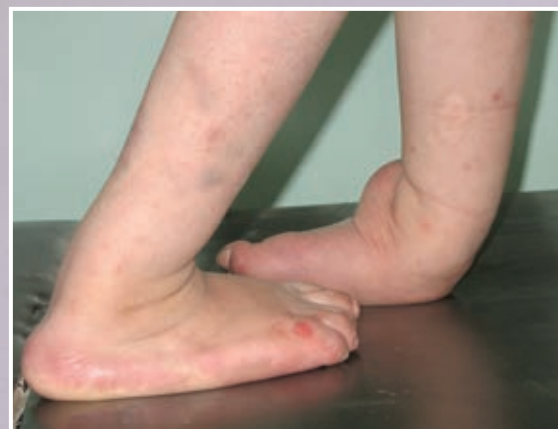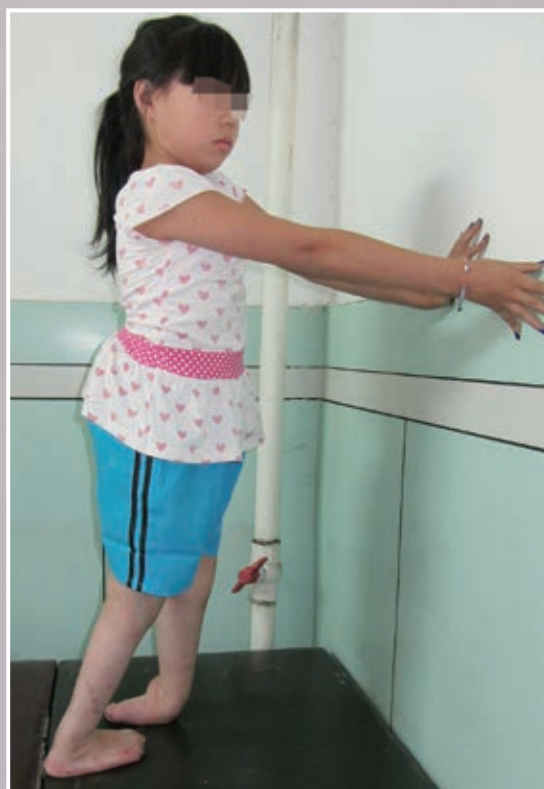手術後雙足位置正常，走路比以前平穩。

After surgery, alignment of the feet were normal. The gait became much more stable.

F 019

脊柱裂症、左足嚴重後翻

Myelomeningocele,
Severe Left Equinus



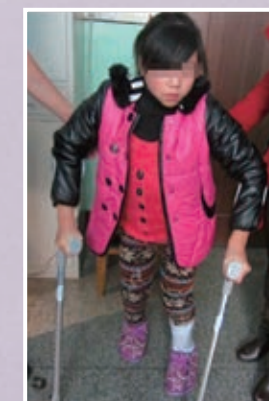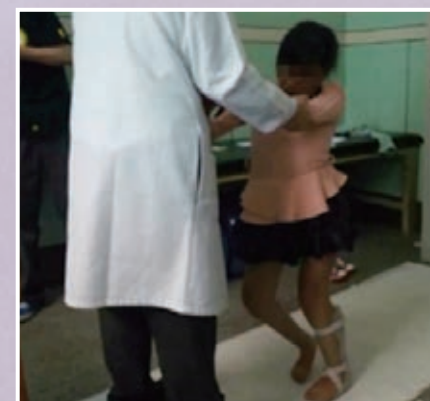一位 11 歲的河南女孩，因為患脊柱裂症，左足乏力及嚴重後翻，站立非常困難，經常要爬行。

A 11-year-old girl from Henan. She was suffering from myelomeningocele which led to weakness and severe equinus deformity of the left foot. Standing was very difficult, and she usually had to crawl.



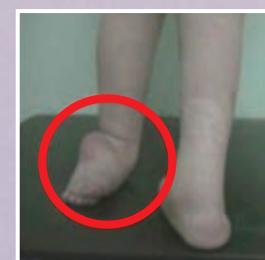如果扶着東西，可以勉強行走幾步，左足往後翻，不能放平，只能用腳背負重，步伐非常不穩。

If hold onto objects, patient was able to take a few unsteady steps. The left foot remained severely deformed and could only bear weight on the dorsum.



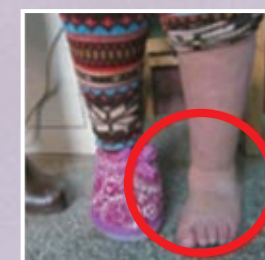手術後，左足可以平放，病人可以用拐杖走路。

After surgery, the left foot is plantigrade. Patient is able to walk with crutches.



手術前

Before Surgery



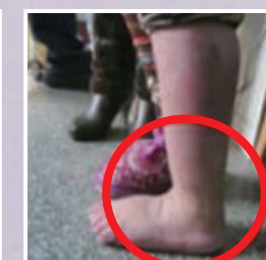手術後

After Surgery



手術前

Before Surgery



手術後

After Surgery

手術把畸形的左足矯正，能够平放地上負重。

After correction of deformity, the left foot is able to bear weight normally.

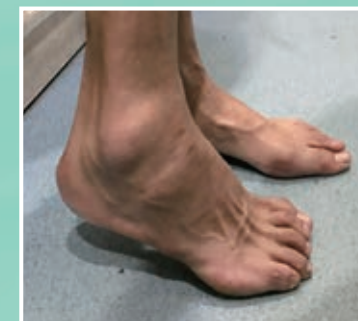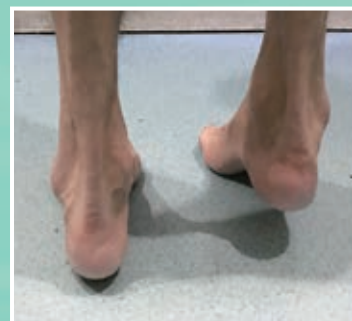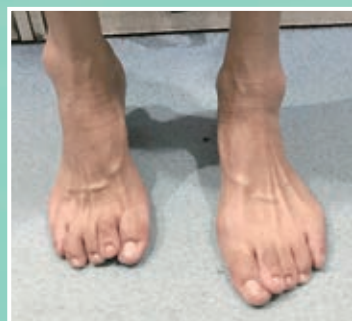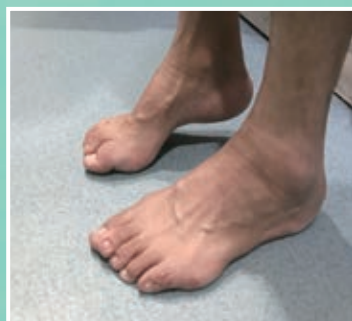F 020



右偏癱、 右馬蹄足 Right Hemiplegia Right Equinus

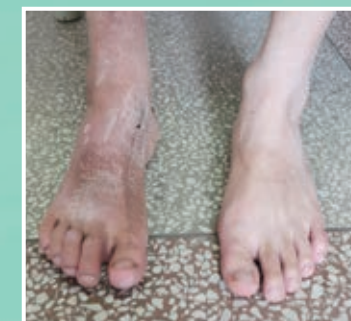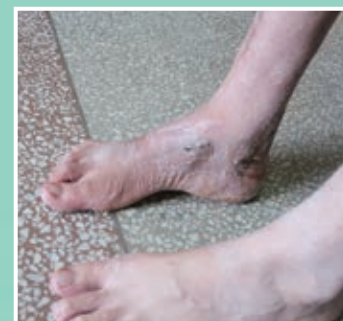一名 32 歲大理男子，患右偏癱，引致右下肢痙攣，右足站立時不能平放，走路不穩。

A 32-year-old man from Dali. He was suffering from right hemiplegia and was unable to stand with the foot flat on the ground, thus leading to unsteady gait.



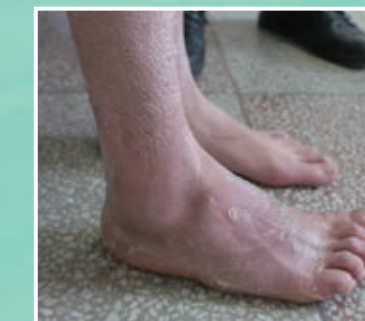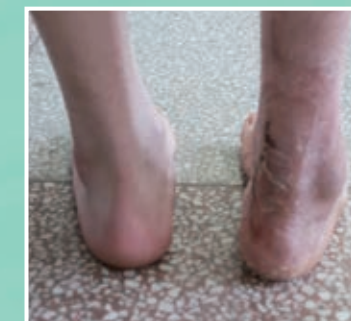手術後右腳可以平放地上，站立和走路比以前穩定。

After surgery, the right foot could be put flat on the ground. Standing and walking are steadier.



手術後兩個月，剛剛拆了石膏，右足位置已獲矯正。

Photos taken 2 months after surgery. The plaster cast was just removed. The alignment of the right foot was corrected.



F 021



脊椎裂症、雙高弓足及內翻

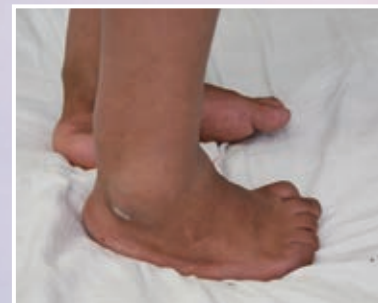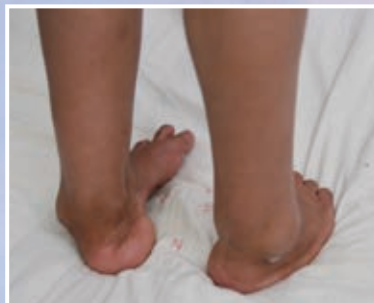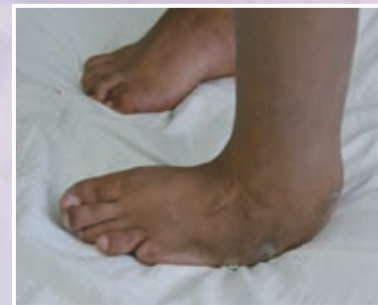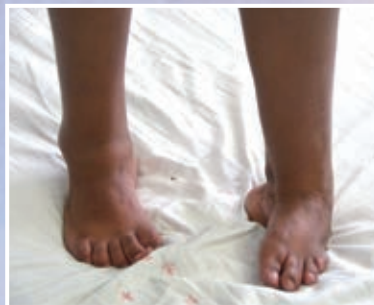Myelomeningocele, Bilateral Cavovarus

小馬是一位 14 歲姑娘，患脊柱裂症，自出生以來雙腳便沒有感覺，並且內翻，隨著年紀增長，變形越發嚴重，曾經四處求醫，做了幾次手術，花了不少金錢，雙足依然嚴重內翻，令走路困難，而且因為足部負重時受力不均，經常導致皮膚破損。

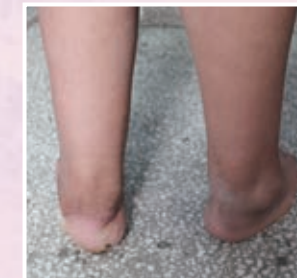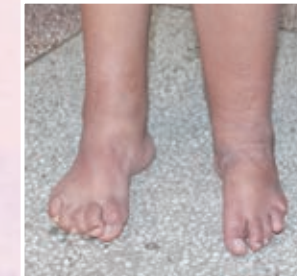Xiao Ma is 14-year-old lady with myelomeningocele since birth. It caused lost of sensation in both feet. Her feet deformities got worse with age. Although the family spent a lot of money in seeking medical treatment, the feet remain grossly deformed. Weight bearing was uneven and frequently caused skin breakdown.

雙足均有內翻現象，其中以左足更為嚴重，站立或步行時，用腳的外側負重，令走路不平穩，而且容易使皮膚破損。

Both feet showed severe deformities. The left foot was worse. On standing or walking, the feet bear weight on the lateral border. This caused unstable gait and frequent skin breakdown.



手術後一年 One year after surgery



第一個手術是矯正左足，因為左腳的變形比較嚴重。手術後傷口受細菌感染，經過多番清創及抗生素治療，才把細菌消滅。手術效果很好，左腳內翻完全矯正過來。

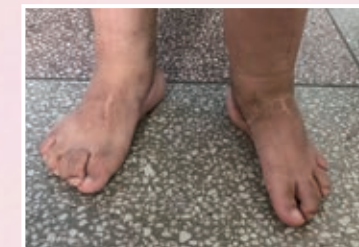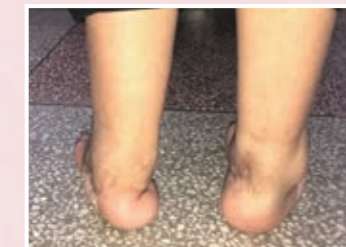The first operation was on the left foot which was more deformed. After surgery wound infection developed. Multiple debridement and antibiotics treatment was used before the infection was eradicated. The results of surgery was good. The left foot deformity was corrected.



手術後三年 3 years after surgery

經過三年及多項手術，雙腳變形已經矯正，走路平穩，皮膚破損問題基本上解決了，病人及家屬多次回來向醫療人員道謝。

After 3 years and multiple surgeries, both feet were well corrected. Patient's gait was stable. Skin breakdown was no longer an issue. Patient and family returned to give thanks to medical staff several times.



F 022



先天性馬蹄內翻 Congenital Clubfoot

一位母親在洛陽第一人民醫院生下一個患有先天性馬蹄內翻的女嬰後，把孩子遺棄了，醫院亦不能跟家人聯絡上，後來護士長收養了女嬰，並且帶女嬰到天鄰接受治療。女嬰的情況並不嚴重，經過打石膏的治理後，馬蹄內翻完全矯正過來。一年後，護士長知道天鄰醫療隊再到洛陽義診，特意抱女兒來道謝，孩子行走完全正常。

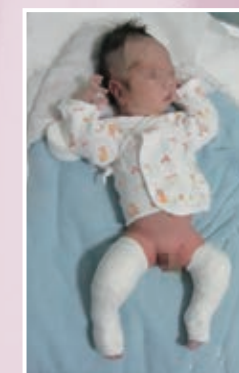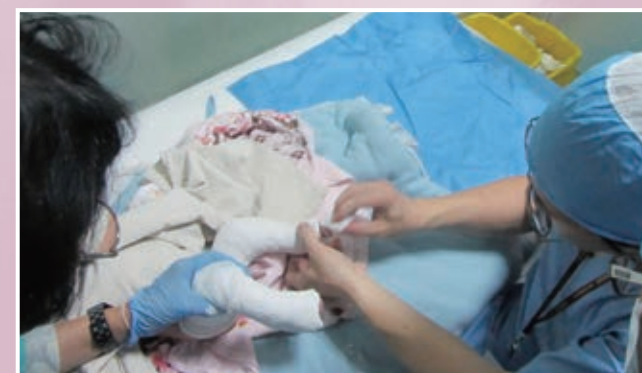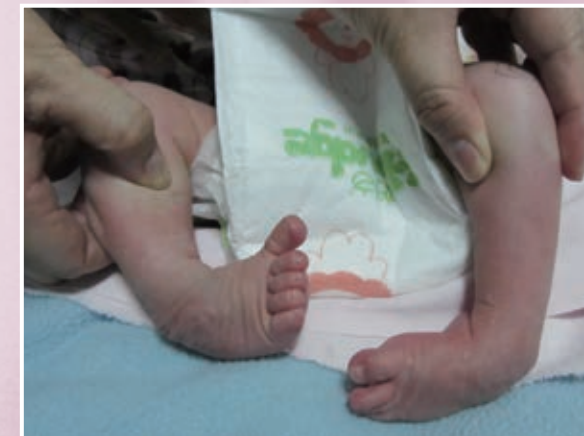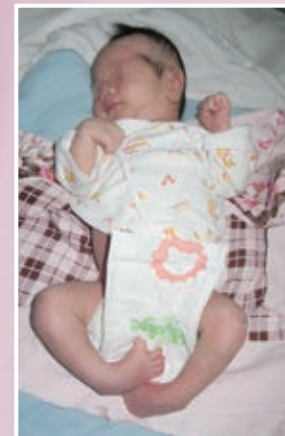Once, a mother gave birth to a baby girl with congenital clubfoot in Luoyang Hospital. She abandoned the baby, and the hospital was unable to find the family. Later, a nurse manager adopted the girl and brought her to HIS Foundation for treatment. The clubfoot was not serious and was corrected after serial cast treatment. One year later, when the nurse knew that HIS Foundation was returning for medical services, she brought the girl to see the medical team to express appreciation. The girl was able to walk and run normally.

F 023

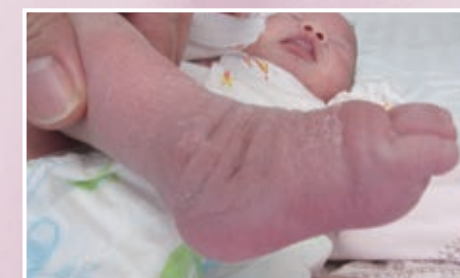天性雙側馬蹄內翻 Bilateral Congenital Clubfoot

一名患有先天性雙側馬蹄內翻的大理初生嬰兒。

A newborn with bilateral congenital clubfoot in Dali.



為嬰兒打石膏。
Application of casts.



兩星期後已經見到明顯改善。
Improvement of foot alignment noticed after 2 weeks of casting.

經過約三個月的石膏治療，雙足已經恢復正常位置。
The alignment of both feet were normal after about three months of serial casting.

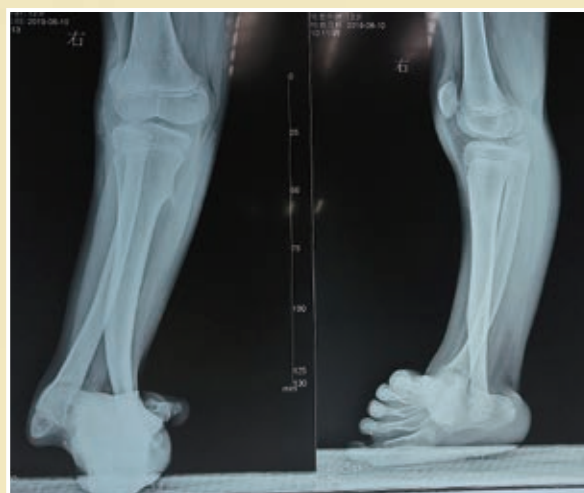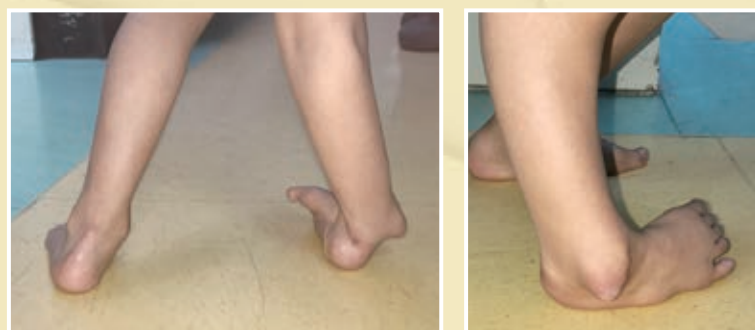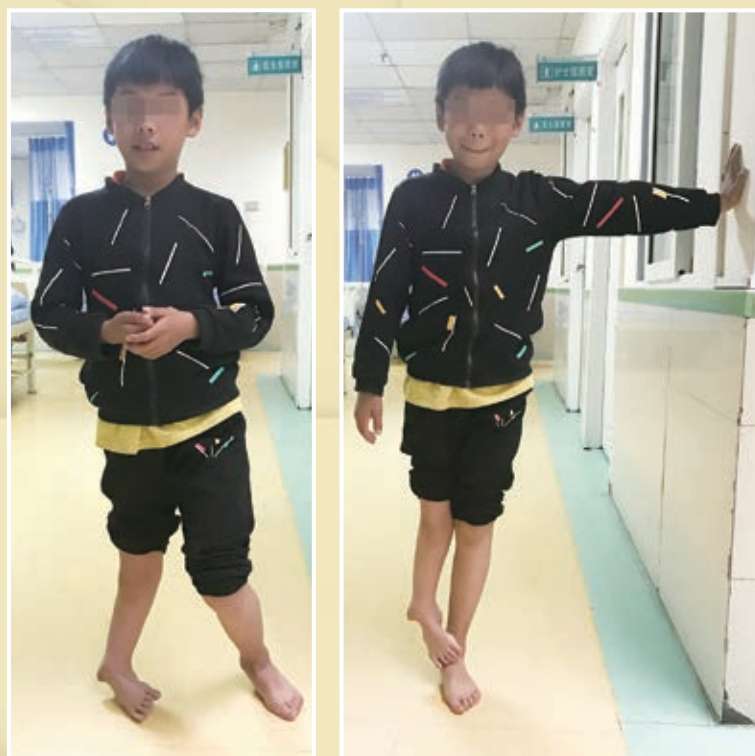
F 024

先天性脛骨及腓骨變形

Congenital Tibia and Fibular Anomalies

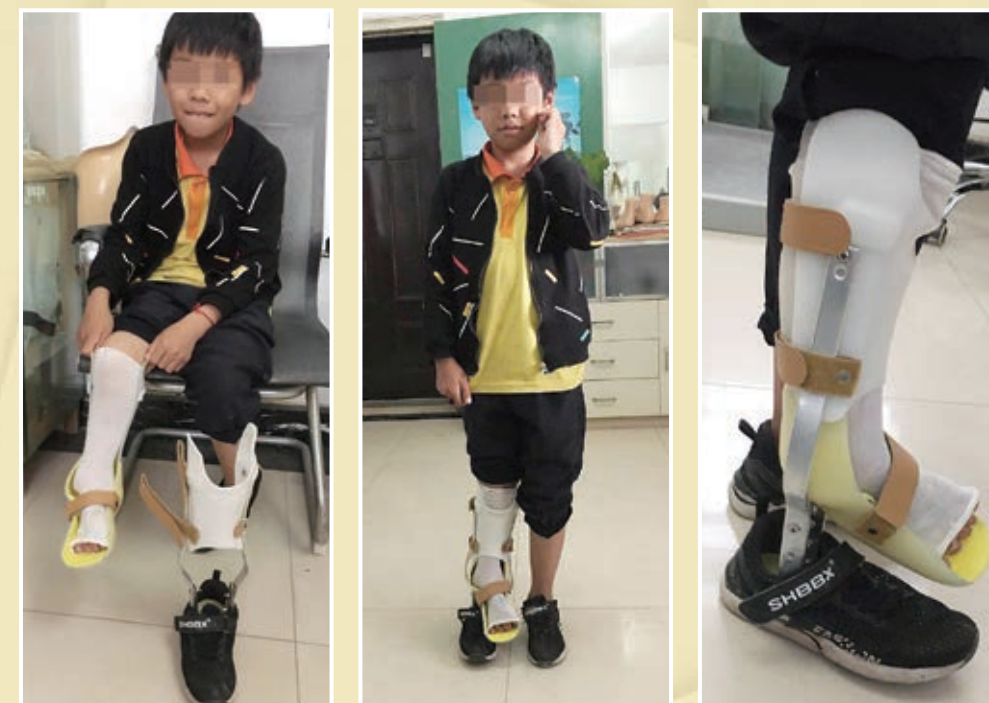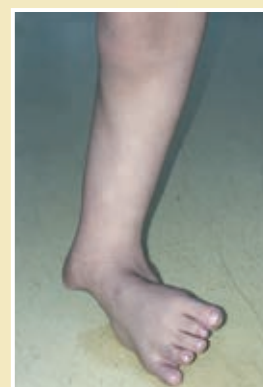一位 12 歲四川瀘州的孩子，右側脛骨及腓骨有先天性的畸形，右腳內翻，只能用腳的外側負重，走路非常困難。

A 12-year-old boy from Luzhou, Sichuan. He was born with anomalies of the right tibia and fibula. The right foot was deformed and could only bear weight on the lateral border, making walking very difficult.



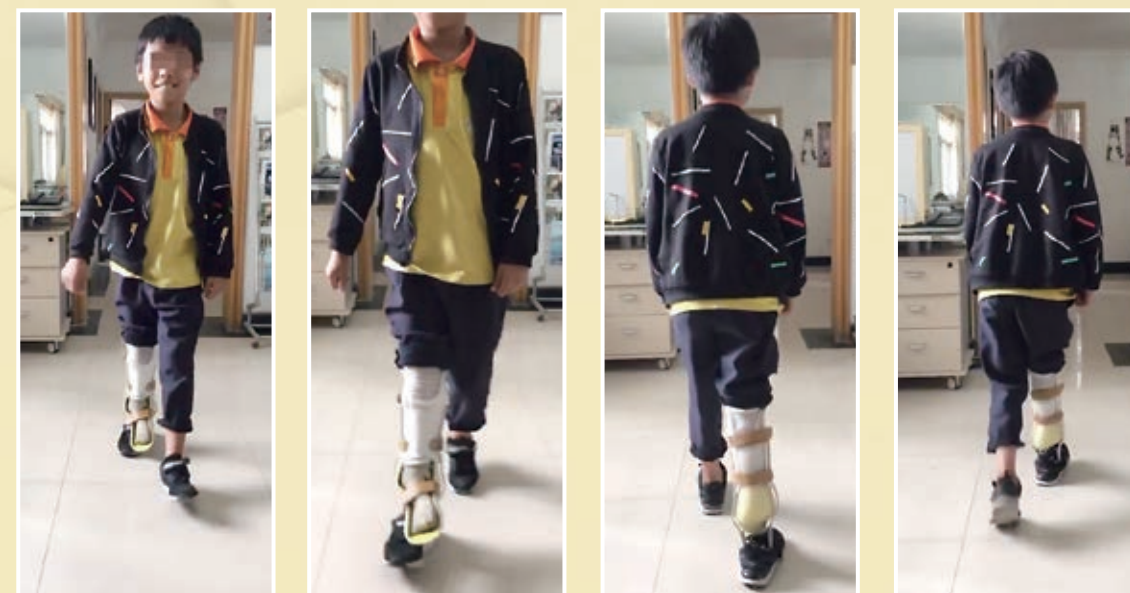X 光顯示脛骨、腓骨及腳部均嚴重變形。

X-ray shows severe deformities in the tibia, the fibula, and the foot.



天鄰的支具師為他做了一個特別的支架，穿上後走路比以前輕鬆快捷得多。

Our orthotist made a special brace for the patient. He was able to walk much easier and faster with the brace on.



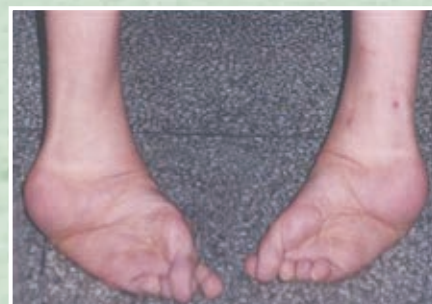F 025

雙側先天性馬蹄內翻 Bilateral Congenital Clubfoot

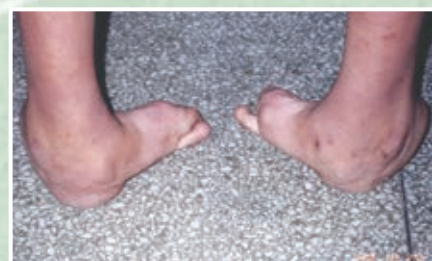

21 歲河南女子，患先天性馬蹄內翻，站立和行走時用腳背負重。

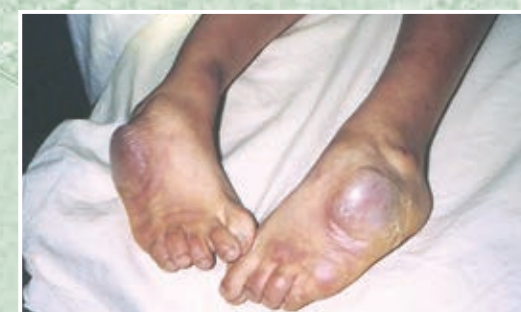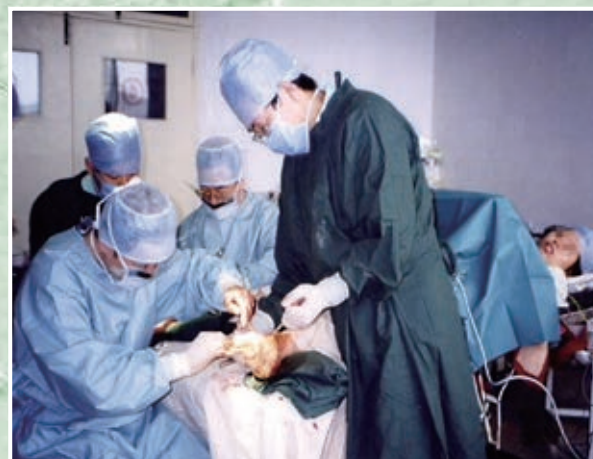A 21-year-old lady from Henan with bilateral congenital clubfoot. She was weight bearing on the dorsum of both feet on standing and walking.





站立時的雙足照片
Photos taken with patient standing



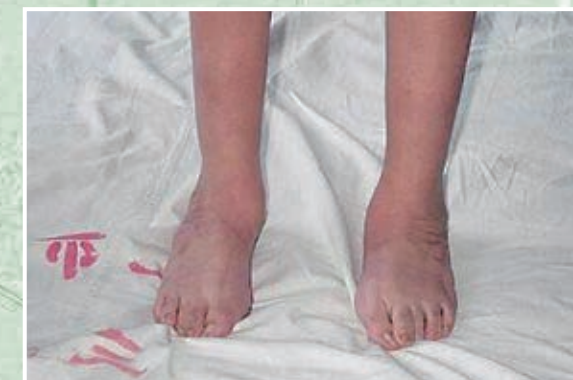手術中
Surgery in Progress



腳背因為長期負重而結出厚厚的繭皮
Thick callosities developed over the dorsum of the feet from weight bearing



步伐平穩
Steady gait



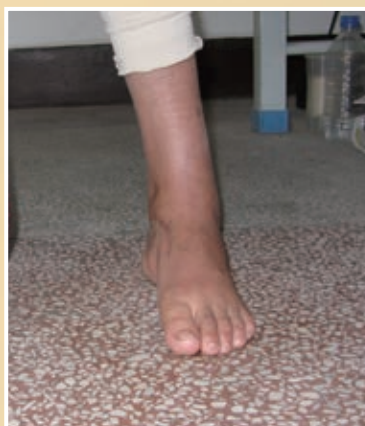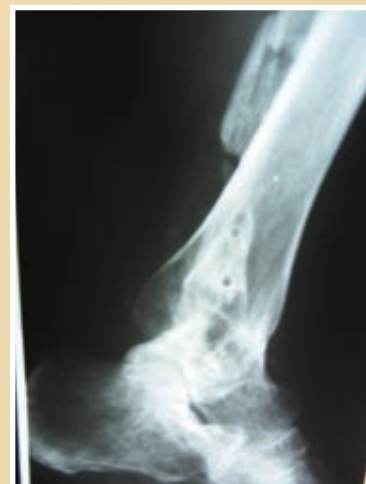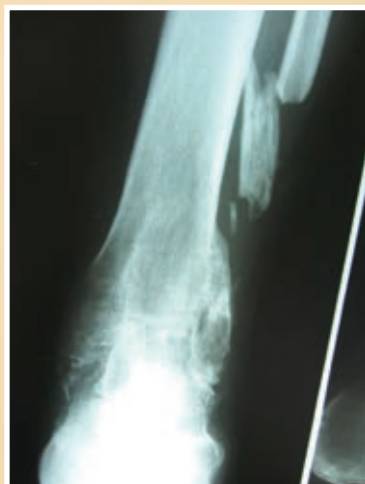
手術後，雙腳位置已經恢復正常。
Normal alignment of both feet after surgery.



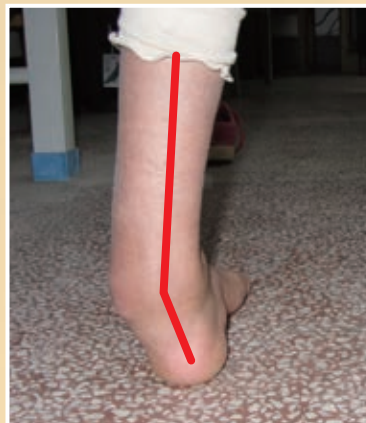F 026

左側踝關節骨折 Fracture Left Ankle

X 光顯示左側踝關節骨折及僵硬。
X-ray shows fracture and
ankylosis of left ankle.

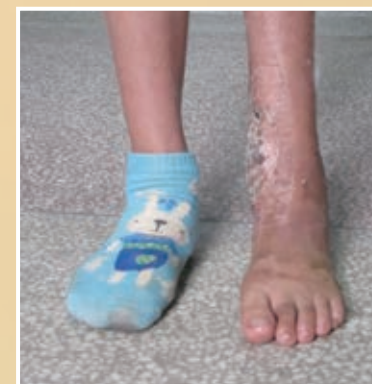

踝關節嚴重內翻。
Severe varus deformity
of ankle.

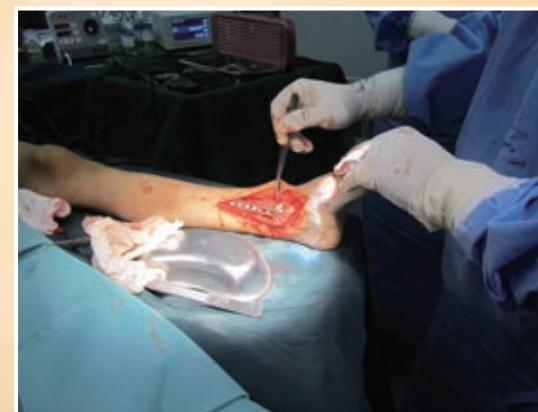


12 歲大理女童，因交通意外引致左側踝關節骨折及僵硬，並且嚴重內翻，且有疼痛，走路困難。

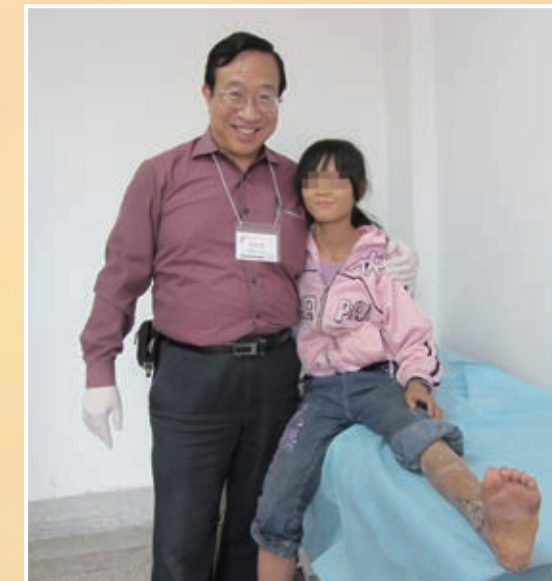12-year-old girl who was a victim of traffic accident. She sustained left ankle fracture. The ankle was in severe varus and was painful.



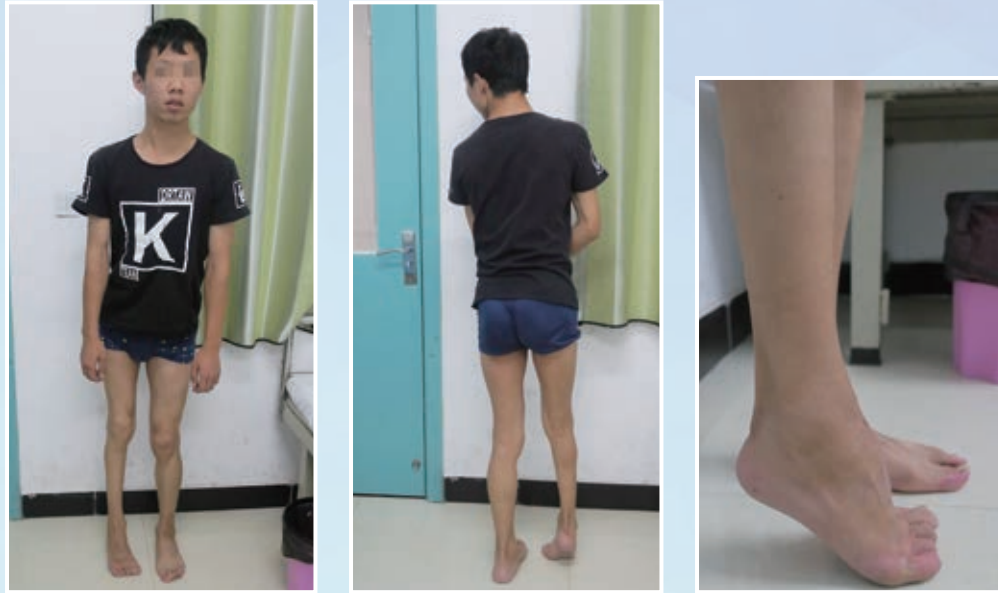手術後踝關節內翻已矯正。
Alignment of ankle
normal after surgery.



手術進行中
Surgery in progress



F 027



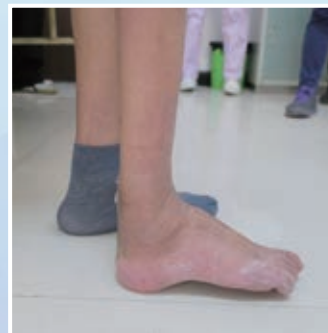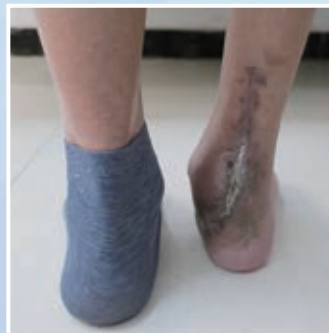腦癱，右馬蹄足

Cerebral Palsy, Right Equinus Deformity

一位 24 歲腦癱男子，影響右側身體肌肉緊張，平衡及走路均有困難。做了跟腱延長手術後右腳可以平放，平衡亦因而改善。

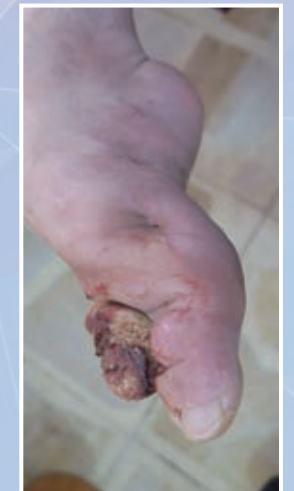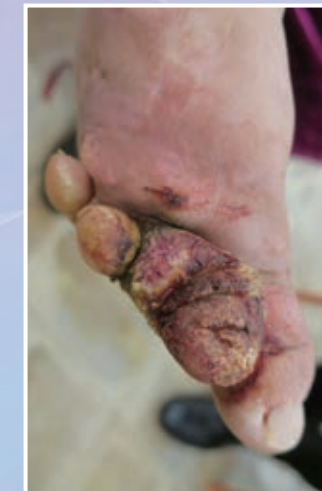A 24-year-old man with cerebral palsy. The muscle tension on the right side of body increased. The right foot had an equinus deformity. Patient had poor balance and difficulty in walking. After surgical lengthening of heelcord, the right foot could be put flat on the floor and the balance improved.

手術後 After Surgery



右側馬蹄足、腳趾慢性感染

Right Equinus, Chronic Infection Right Toes

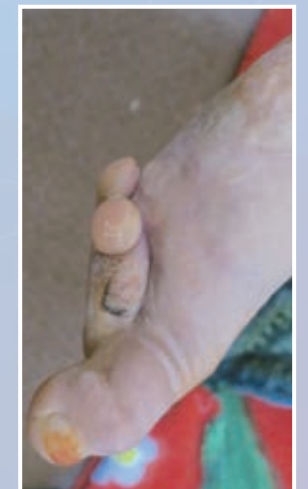


一位庫爾德斯坦的雅茲迪難民，患有馬蹄足，走路時因腳趾長期負重過度導致磨損，產生潰瘍，並且引發慢性感染，已經多年未癒。

A Yazidi female refugee in Kurdistan. She has equinus deformity of the right foot with excessive weight bearing and ulceration of toes. The chronic infection remained unhealed for several years.

手術切除了兩隻有慢性感染的腳趾後，感染已經消除。現在計劃等候一段時間，若感染沒有復發，將做手術把馬蹄足矯正。

The infection subsided after amputation of two chronically infected toes. If no recurrence of infection after some time, then further surgery can be performed to correct the equinus deformity.



F 028

F 029

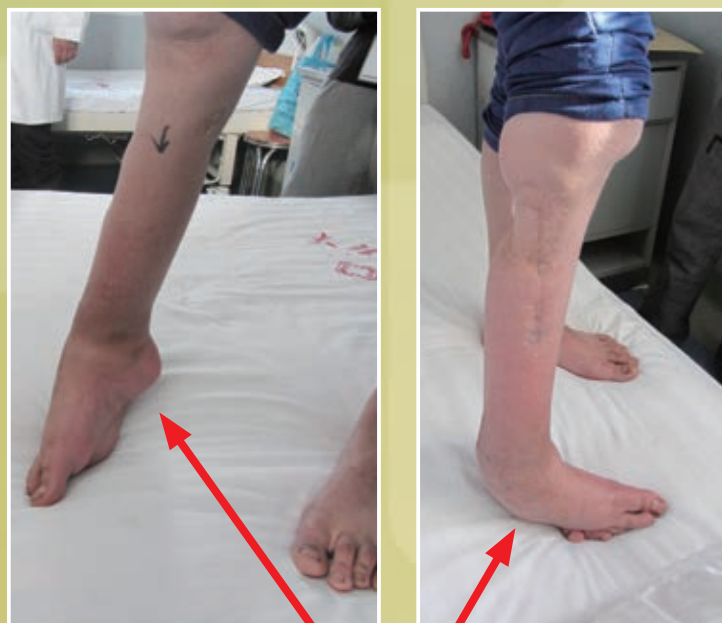

一位大理的女童，因為交通意外，令右小腿骨折，神經及肌肉受損，引致右足癱瘓、變形，足部內翻，走路困難。

A Dali girl was a victim of traffic accident. She had fracture of the right leg and injury to nerve and muscles. The right foot became deformed and paralyzed. Patient had difficulty walking.

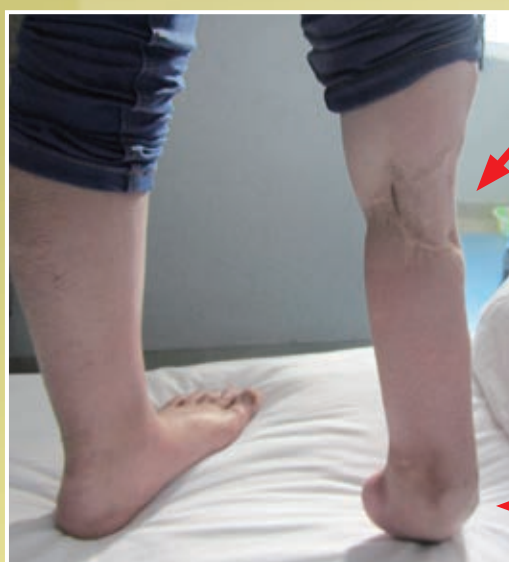創傷性腓總神經麻痺、右足馬蹄內翻

Post-traumatic Common Peroneal Nerve Palsy
Right Equinovarus



右足部內翻，負重困難

Varus deformity of the right foot with difficulty in weight bearing.



最初意外受傷及骨折部位
Site of injury and fracture

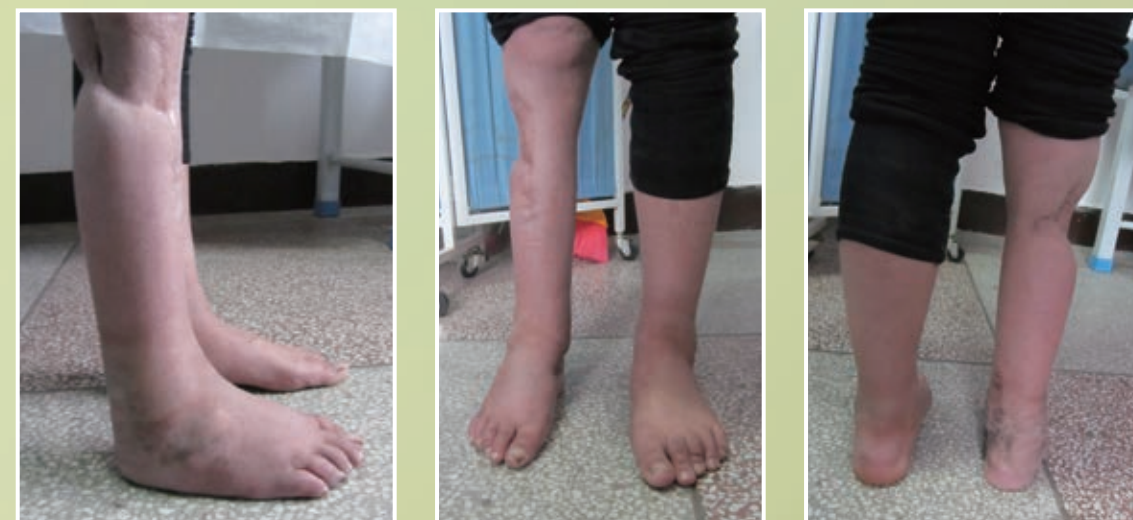足內翻，缺乏活動能力
Foot in varus and lost mobility.



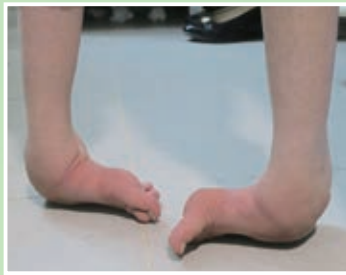女童接受了右足重組手術包括截骨及關節融合術，右腳位置已經恢復正常，可以正常負重。

The girl had reconstructive surgery of the right foot which included osteotomy and arthrodesis. After operation, the foot restored normal alignment and was able to bear weight.

右腳可以平放在地上。 The right foot is plantigrade.



F 030



手術前
Before Surgery



先天性雙側 馬蹄內翻 Congenital Bilateral Clubfoot

先天性馬蹄內翻，若能在初生時馬上用石膏矯正，很多病人不用接受手術或只需要簡單手術治療。

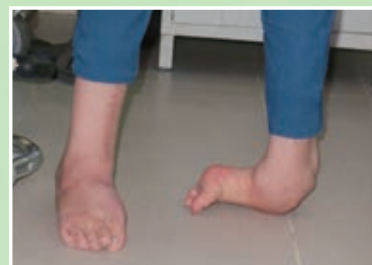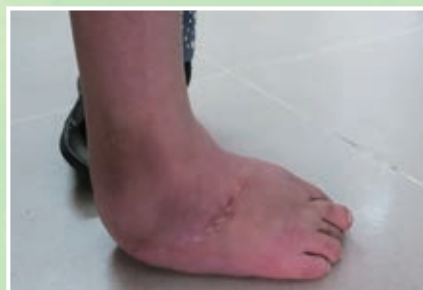If clubfoot are treated early after birth with plaster, then most patients do not need surgery or require only minor operations.

一位 19 歲雅茲迪女士，患先天性馬蹄內翻，從未接受過治療，站立時腳部非常疼痛，若不穿鞋子，不能走路。

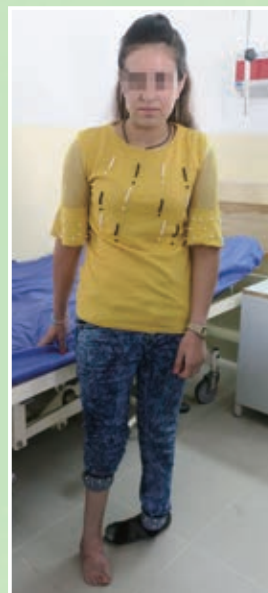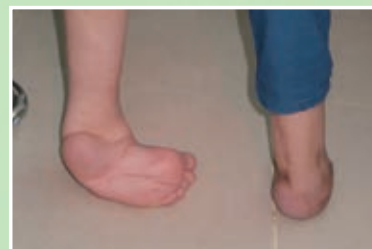A 19-year-old Yazidi lady with bilateral congenital clubfoot. She never had any treatment. Both feet were very painful on weight bearing. Was unable to walk without wearing shoes.

右腳手術後已能平放地上，疼痛大大減少。

After surgery, the right foot alignment greatly improved, and pain largely subsided.



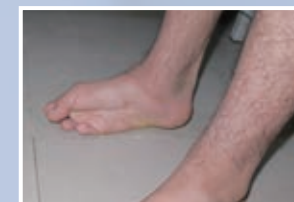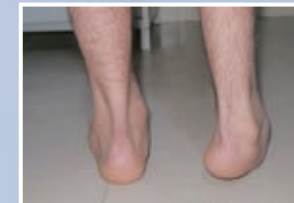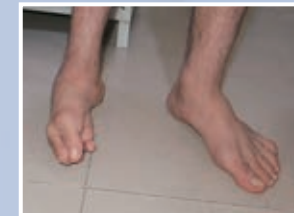手術後 After Surgery



拍照時病人在等候左腳手術。

At time of photography, patient was waiting for surgery of the left foot.

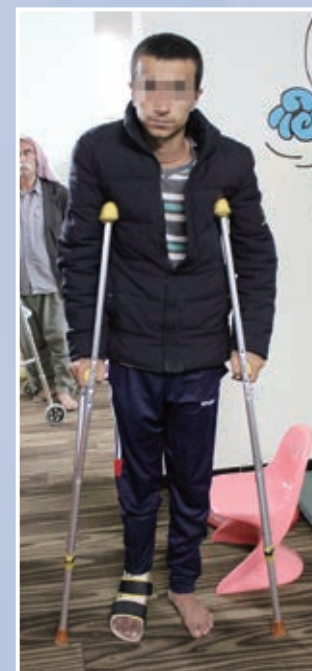F 031



先天性右側馬蹄內翻 Congenital Right Clubfoot

一位 17 歲患右側先天性馬蹄內翻的雅茲迪男病人。

A 17-year-old male Yazidi patient with congenital right clubfoot.

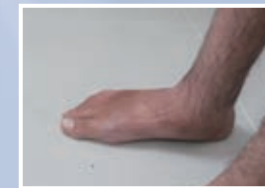
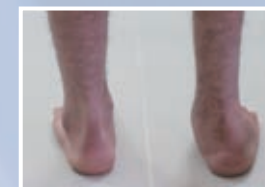
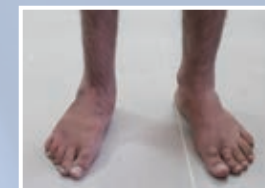
手術後 2 個月，石膏剛剛拆了，配了支具，開始做物理治療。

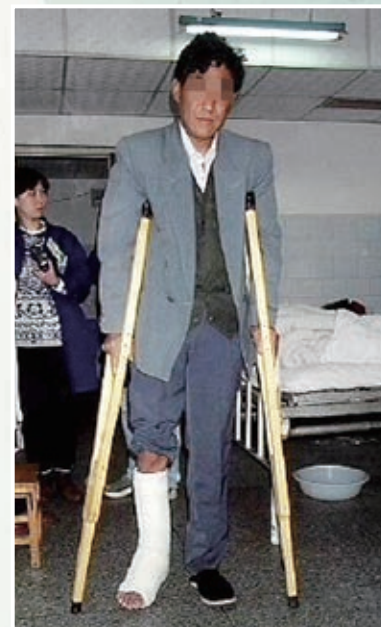2 months after surgery, the cast was removed, and patient started on physical therapy.

手術後一年，病人帶著笑容回來覆診。他已經行動自如。

One year after surgery, patient returned to the clinic with a smiling face. He walks normally.



F 032

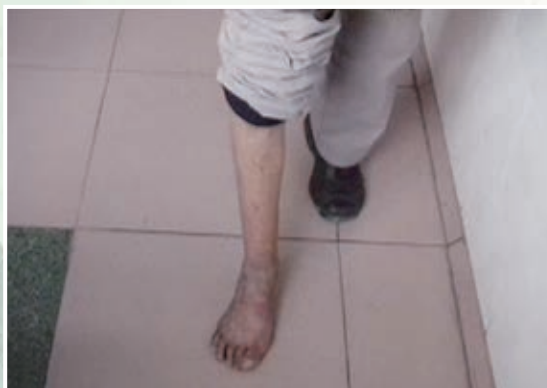

兒麻後遺症、右側馬蹄足

Post-poliomyelitis Deformity, Right Equinus

一位 40 歲來自河南農村的木匠，患小兒麻痺後遺症，右足成馬蹄狀，走路不穩，容易摔倒。接受了跟腱鬆解手術後，右腳可以平放地上。手術後勞動力比以前強，木匠生意亦比以前繁忙。

A 40-year-old carpenter from rural Henan. He developed post-poliomyelitis equinus deformity in the right foot. Gait was unsteady. After release of the heelcord, the foot became plantigrade. Working capacity improved after surgery and his carpentry business became busier.



F 033

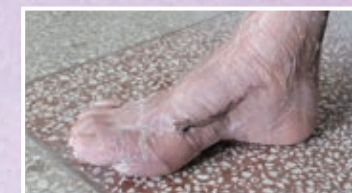
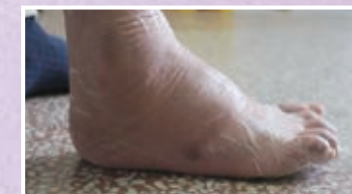
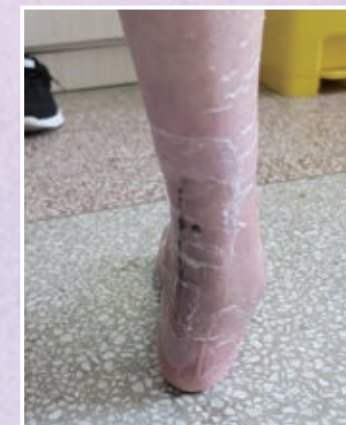兒麻後遺，右側馬蹄內翻足

Post-poliomyelitis Deformity, Right Equinovarus

一位 42 歲女士，因幼年患小兒麻痺症，令右足變形，成馬蹄內翻狀。經手術治療後，右腳位置正常，可以平放在地上，走路比以前輕鬆。

A 42-year-old lady with history of childhood poliomyelitis. It caused equinovarus deformity of the right foot. After surgery, the alignment of the foot is normal with improvement of gait.

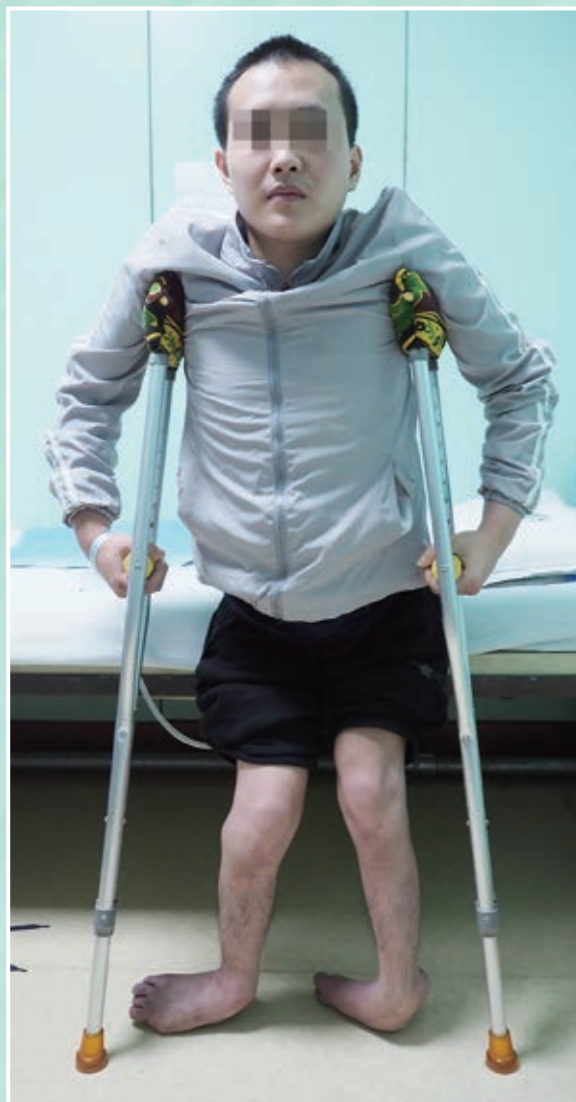

手術後兩個月，剛剛拆了石膏。

Two months after surgery, the plaster cast was just removed.



F 034

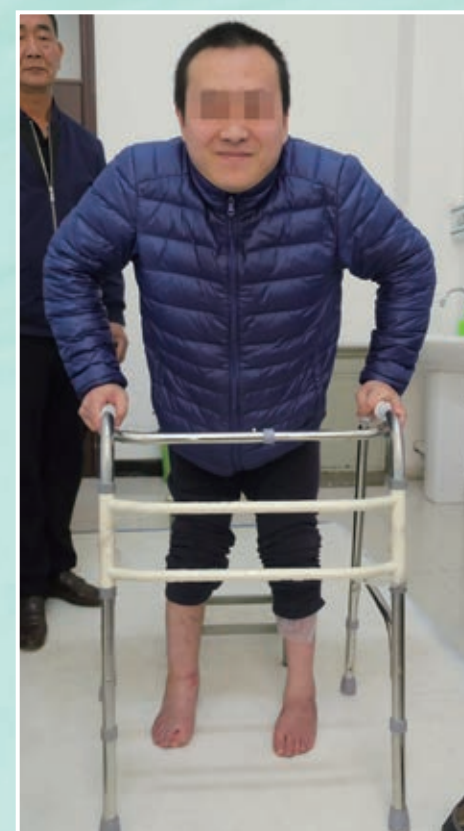
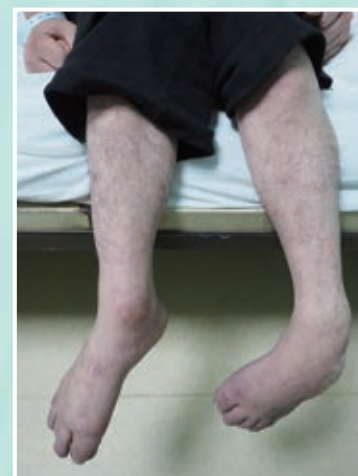
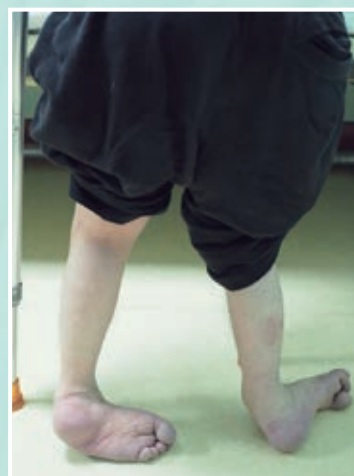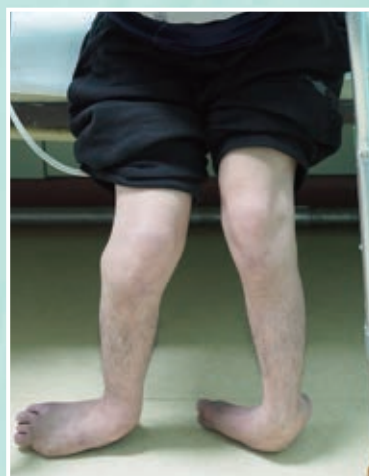脊柱裂症 左足內翻、右足外翻

Myelomeningocele Left foot Varus, Right Foot Valgus

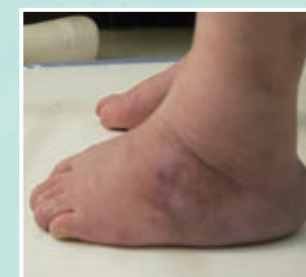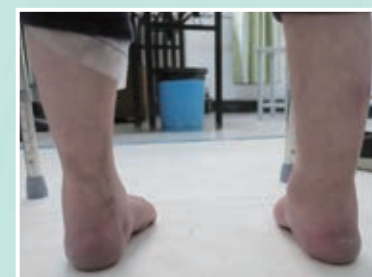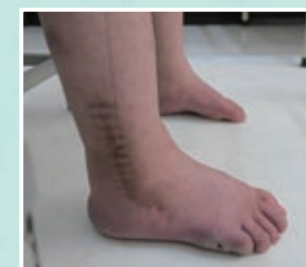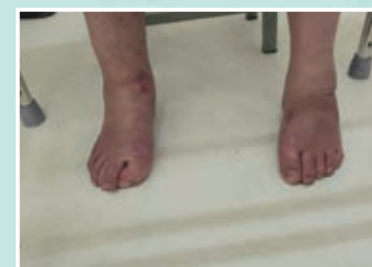一位 24 歲的河南男士，自出生以來患脊柱裂症，引致下肢部份癱瘓，雙足嚴重變形，左腳內翻而右腳則外翻，而且缺乏感覺，穿鞋子、站立和走路均非常困難。

A 24-year-old man from Henan. He has myelomeningocele since birth. His lower limbs are paralyzed. The left foot developed varus deformity while the right foot had a valgus alignment. Both feet have impaired sensation. Wearing shoes, standing, and walking were all very difficult.



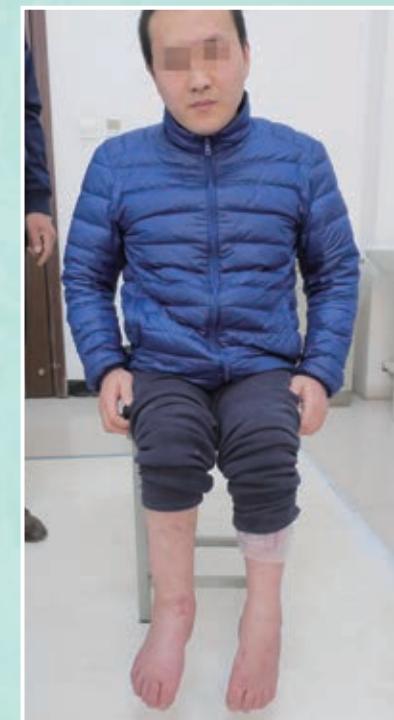病人左右腳分兩次做了手術治療，包括截骨和關節融合。手術後，雙足可以平放地上負重，可以穿鞋子，又可以用助行器站立和走路。

Patient had two operations, one for each foot. The surgery include osteotomy and arthrodesis. After surgery, both feet are plantigrade on weight bearing. Patient can wear shoes. He can also stand and walk with a walker.



手術後雙足的位置正常。

After surgery, both feet restored normal alignment.



F 035

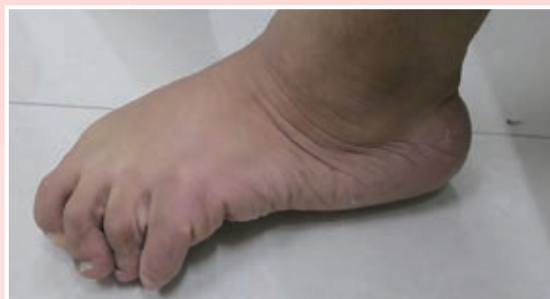
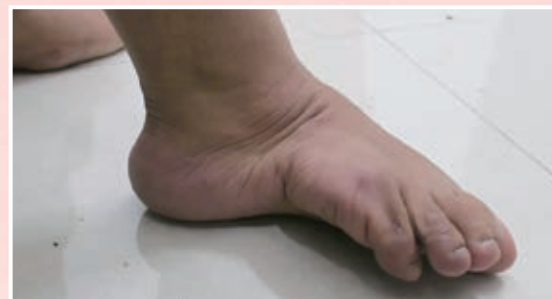
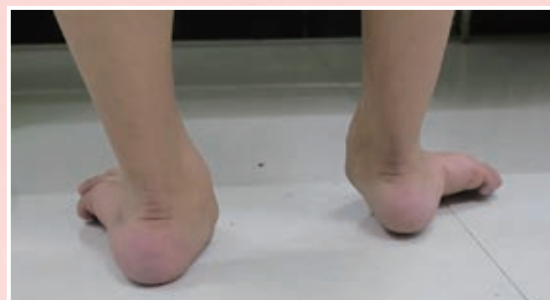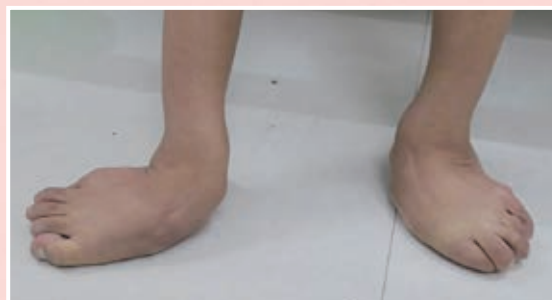脊柱裂症、 雙側外翻扁平足

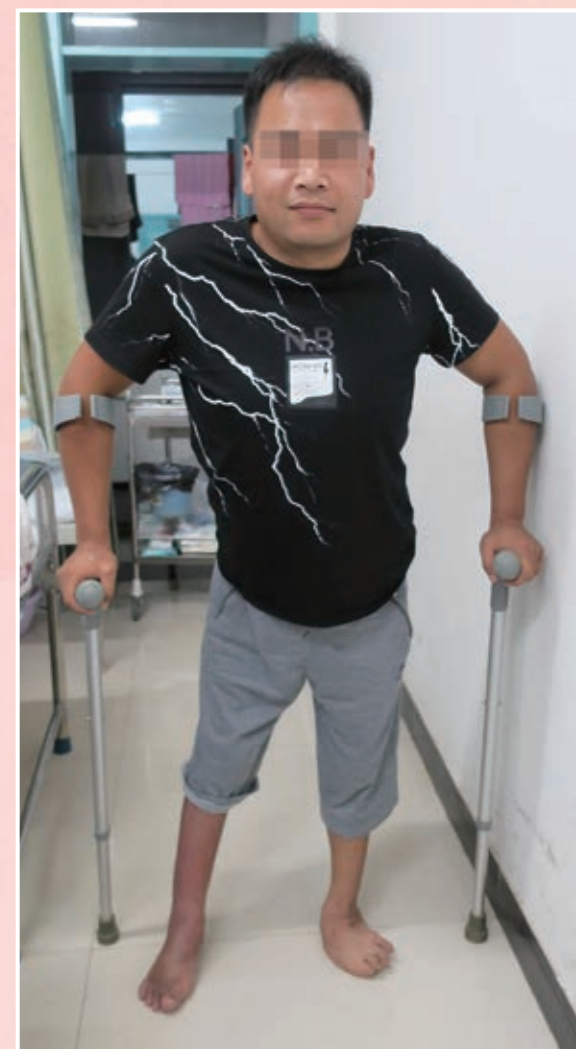Myelomeningocele Bilateral Pes Planovalgus

一位 26 歲河南脊椎裂患者，雙足部分癱瘓變形，外翻並成扁平足，穿鞋子及走路均困難。

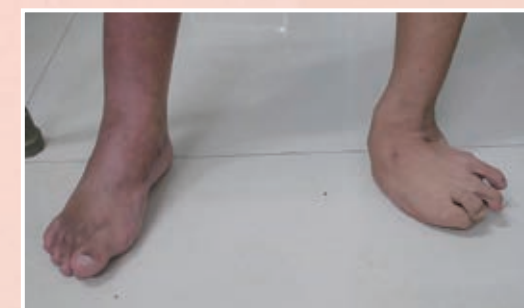A 26-year-old man from Henan. He had myelomeningocele leading to partial paralysis of both feet. The feet developed planovalgus deformity. Wearing shoes and walking were difficult.



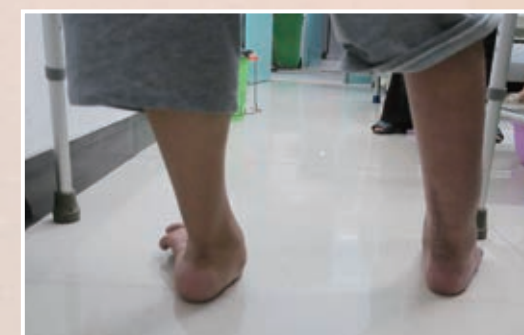手術前 Before Surgery



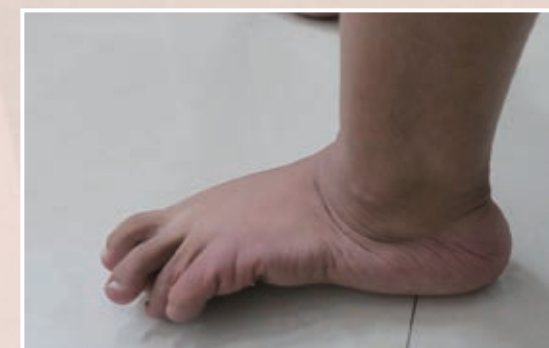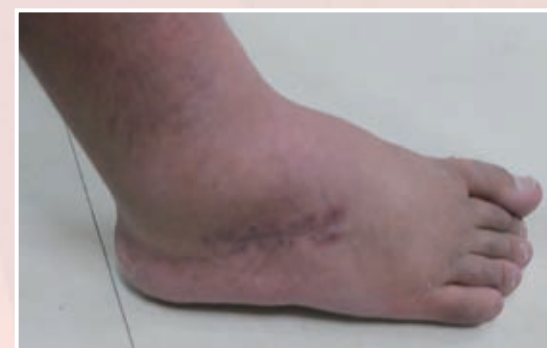右腳，已經接受手術矯正。
Right foot after corrective surgery.



右腳已經接受手術，位置正常。拍照時，病人在等候做左腳的手術。
Right foot had surgery and the alignment is restored to normal. At time of photo, patient was waiting for surgery of the left foot.



左腳，正在等候手術。
Left foot, waiting for surgery.



F 036

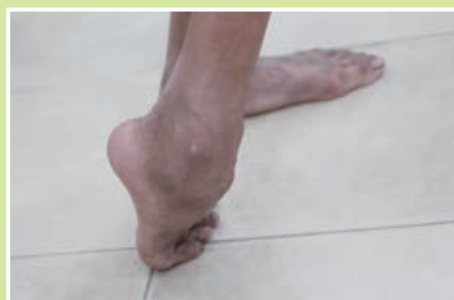

腦癱、右偏癱 右側馬蹄內翻足

Cerebral Palsy Right Hemiplegia Equinovarus Right Foot

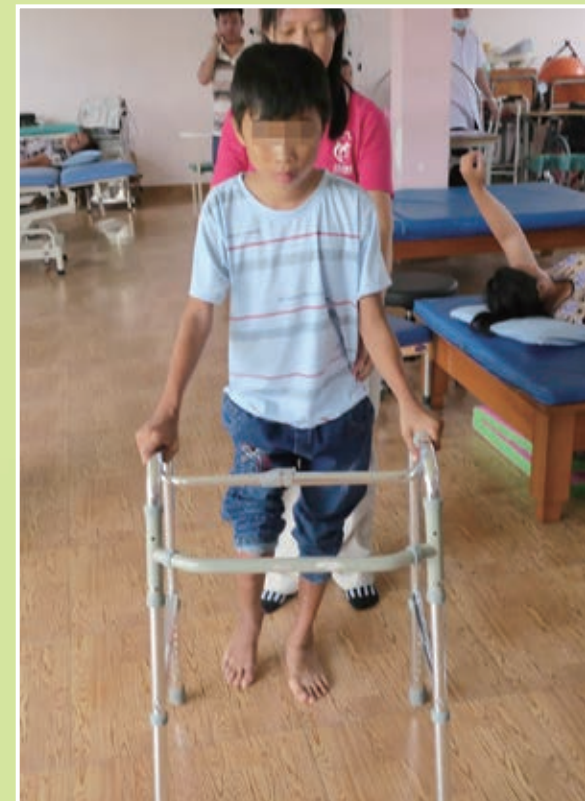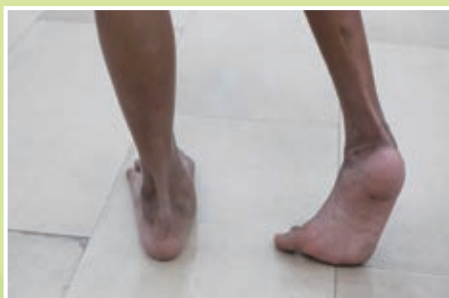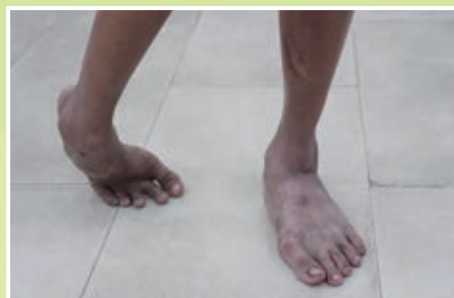一位 14 歲越南男孩，患腦癱，屬右偏癱類，令右腳成馬蹄內翻形，走路時右足只能用腳尖著地。

A 14-year-old Vietnamese boy. He is suffering from cerebral palsy, right hemiplegic type. There was an equinovarus deformity in the right foot. On walking, only the toes bear weight.



腦癱令肌肉緊張及跟腱攣縮，右足不能平放地上。

Cerebral palsy causes increase in muscle tension and shortening of heelcord. The right foot could not be put flat on the ground.

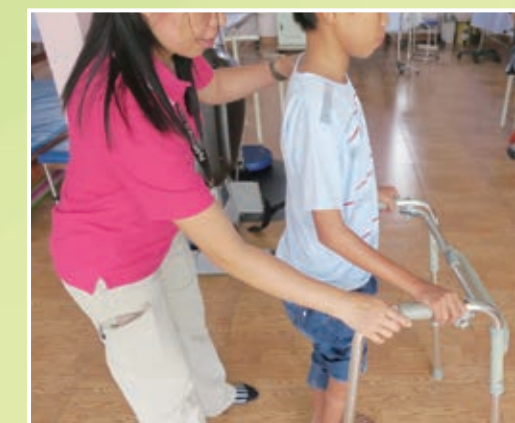

病人在物理治療師指導下作鍛鍊。

Patient was having training under the supervision of a physical therapist.

病人接受了跟腱延長手術，剛剛拆了石膏，右腳可以平放地上，走路姿勢改善了，而且比以前穩定。

Patient had surgery for lengthening of heelcord. The plaster cast was just removed. Patient can put the foot flat on the ground. Thus, the gait is more stable.



F 037



小兒麻痺後遺症 左馬蹄足

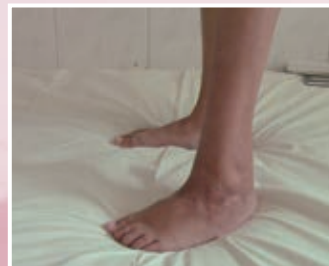
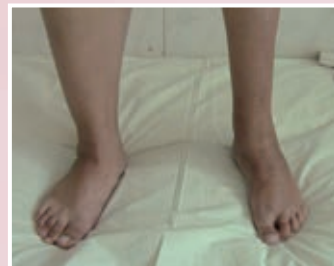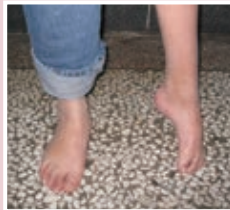Post-poliomyelitis Deformity Left Equinus Foot

一位 23 歲河南女士，幼年患小兒麻痺症，左腿萎縮乏力，跟腱緊張，左足成馬蹄狀，站立時只能用腳趾負重。走路時不穩，容易摔倒，而且經常疼痛。

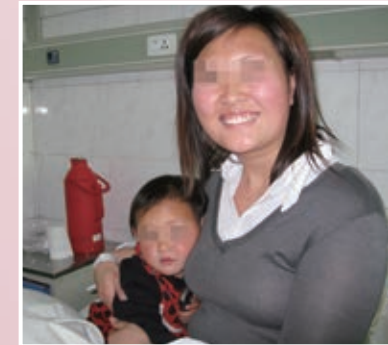患者接受了跟腱延長手術，手術後左脚可以平放地上負重，走路穩定，而且能走很遠，亦沒有疼痛。

A 23-year-old lady from Henan. She had poliomyelitis from early childhood leading to weakness and atrophy of the left lower limb. The heelcord was tight and an equinus deformity developed. She could only bear weight on the toes. The gait was unsteady, and she was prone to fall. She also had pain on walking.

Patient had lengthening of heelcord. After surgery she can put the left foot flat on the ground on standing. The gait is steady, and she can walk for long distance without pain.



手術後一年 One year after surgery



患者說：「以前我的腳變形，走路特別費力，容易摔倒，而且疼痛。生女兒後雖然孩子在身邊，卻不敢抱著她走路，不只我家人，連我都不放心自己抱孩子，女兒出外都是由奶奶帶，我感覺孩子跟自己不太親近，心裡也有不舒服。

手術後腳放平了，也有力了，可以正常地走路，孩子也可以抱。後來生了第二個女兒，我常常抱著她走路，我覺得小女兒對我特別親。現在我也多帶大女兒逛街、買衣服，我們的關係也改善了。

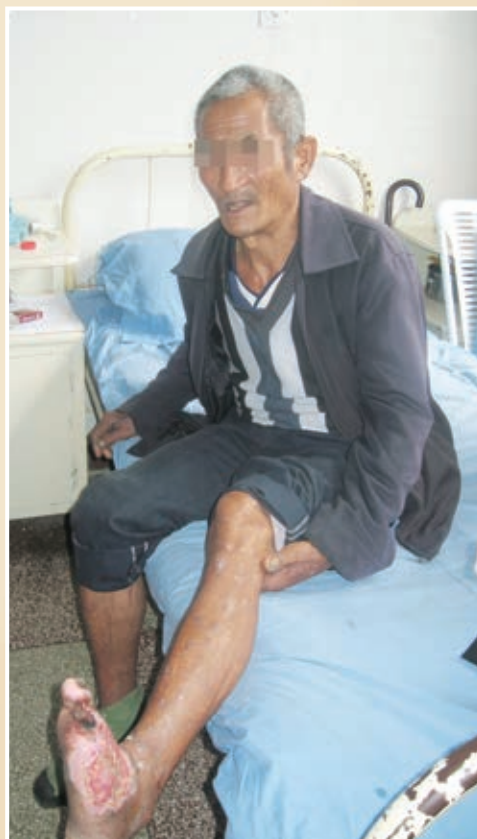以前在家覺得自己不重要，有點自卑，因為帶孩子和家務都由奶奶來做。手術後一切家務我都可以做，感覺大家都需要我，我現在也可以出外打工。真是特別感謝天鄰基金會給我的幫助。」

Patient said, "My foot was deformed, and walking was difficult. I fell easily and the foot frequently became painful. After birth of my daughter, I was unable to carry her when I was walking. Both my family and myself felt that it was unsafe for me to hold the child. Grandmother was the one that usually took my daughter out. My daughter was not close to me, and I was sad.

After surgery, my foot can be put flat on the ground, and it is stronger. I walk normally. Last year, I had a second daughter. I frequently carried her on walking. I feel that she is very close to me. Now I also bring my older daughter out for activities and shopping. Our relationship has improved.

In the past, I felt inferior because my role at home was not important. Childcare and household chores were all done by grandmother. After surgery I am able to do all housework. I feel that I am being needed. I can also go out to work. I really want to thank HIS Foundation for the help."

F 038



左足感染、腳趾壞疽

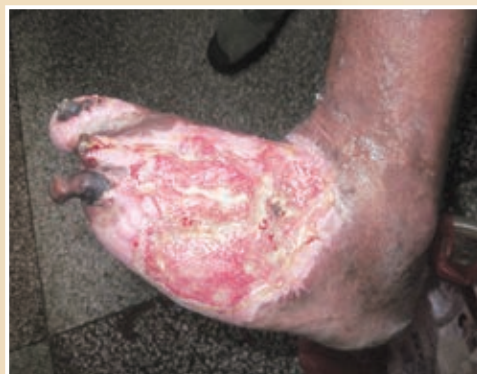Infection Left Foot Gangrenous Toes

一位農夫因為創傷，令左足感染，傷口長久不癒，而且腳趾壞疽，有些腳趾已經失去。

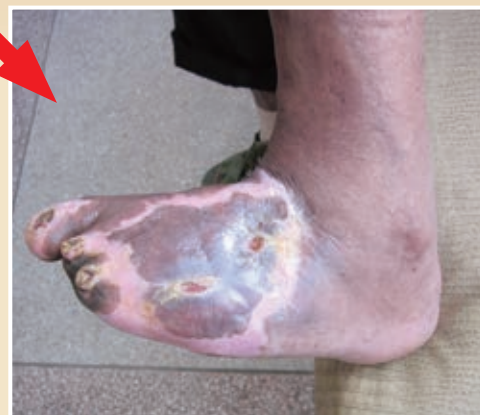入院後得到護士們悉心照料，每天多次清洗傷口，加上藥物治療，傷口慢慢痊愈，感染亦消除了。

A farmer developed infection of the left foot after trauma. The wound became infected and remain unhealed for a long time. Some toes became gangrenous and were autoamputated.

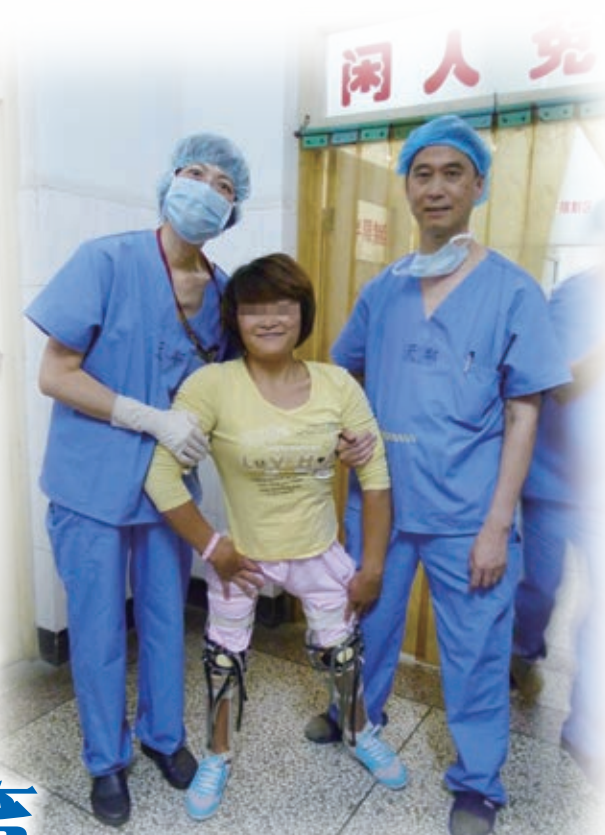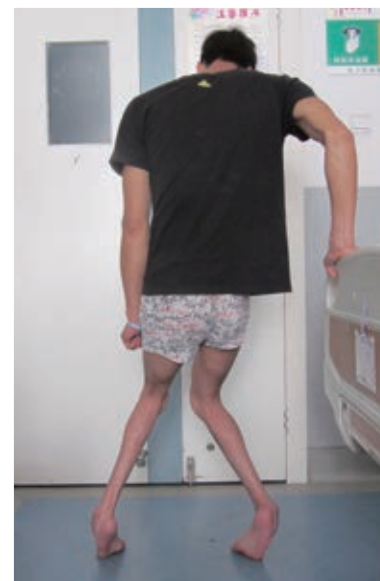
After admission, he got very attentive care from the nurses. He was given frequent wound care and medication. The wound gradually healed with eradication of infection.



治療後。
After treatment.

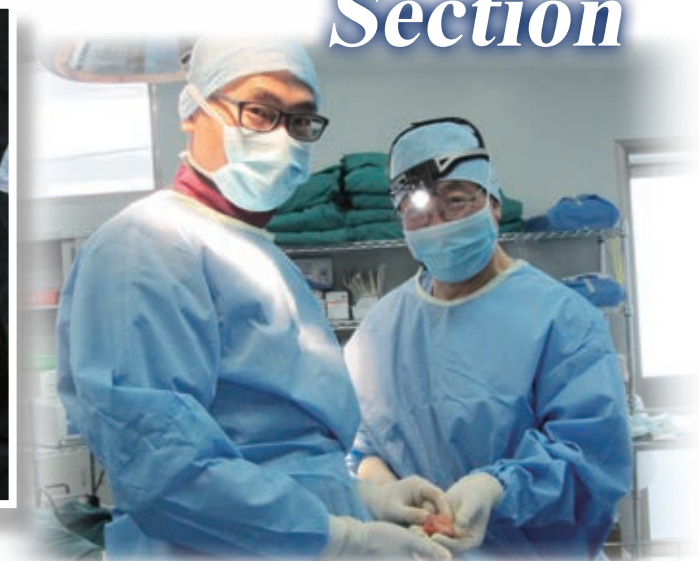
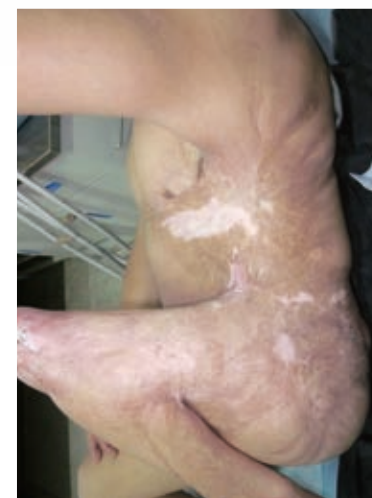
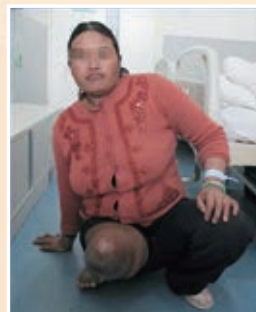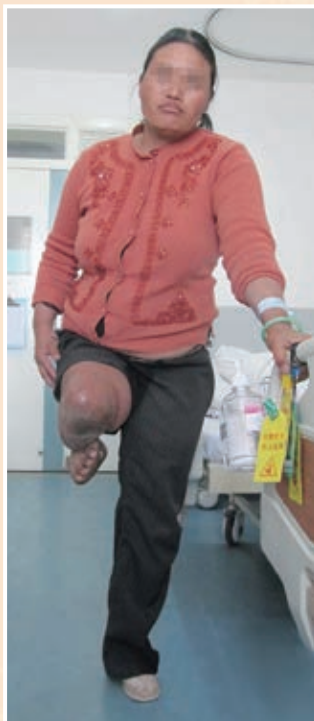F 039



多個肢體 部位篇

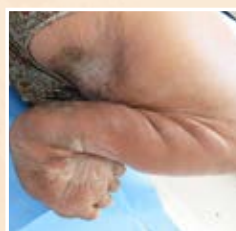Multiple Body Parts Section



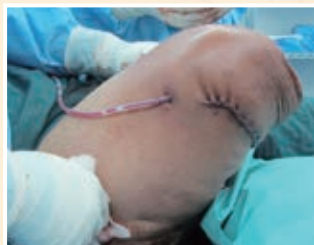

嚴重燙傷、下肢變形 Severe Burn Disabling Contractures

47 歲女病人，嬰兒時右下肢嚴重燙傷，引致變形、收縮及僵硬，右膝關節、踝關節及右足不能活動，患者平時蹲坐在地上，手腳並用移動前行。

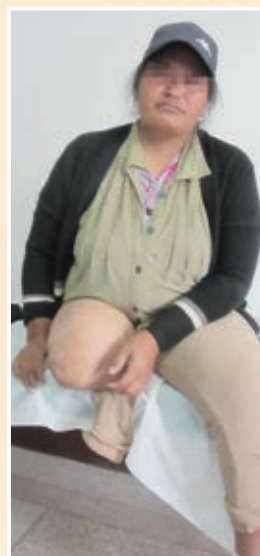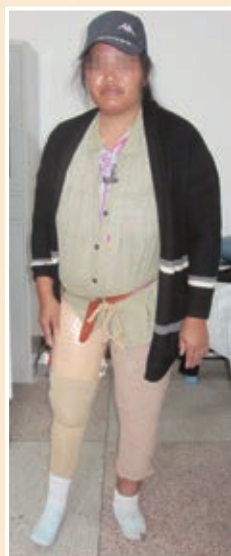


A 47-year-old lady had severe scald to the right leg leading to contracture, ankylosis, and deformity of the knee, ankle, and foot. Patient has to crawl from place to place.



病人接受了截肢手術把沒有功能的部分下肢切除。

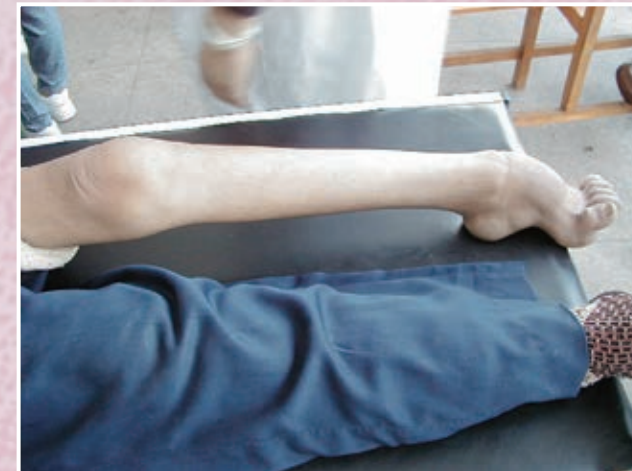Patient had an above knee amputation for removal of the nonfunctioning part of the lower limb.



手術後配上義肢，可以走路。

Patient was fitted with an above-knee prosthesis and was able to walk.

M 001



兒麻後遺症 左側馬蹄足、左膝關節攣縮

Post-poliomyelitis Deformities
Left equinus
Left knee flexion contracture

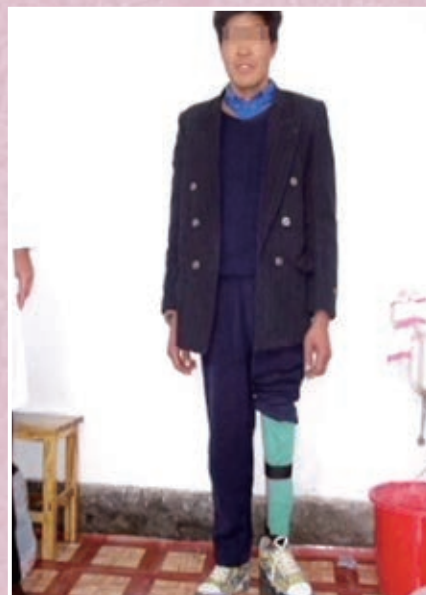34 歲河南農夫，幼年患小兒麻痺，令左下肢萎縮無力，並且短了，左足成馬蹄狀，左膝輕微攣縮，走路時必須用手按著大腿才能負重。

A 34-year-old farmer from Henan. He had poliomyelitis during childhood leading to weakness and shortening in left lower limb. The left foot developed equinus deformity and there was mild flexion contracture in the left knee. On walking, he must use the left hand to support the left thigh on weight bearing (hand-knee gait).

M 002

病人接受了跟腱延長及股骨截骨手術後，打了石膏，與醫護人員合照。

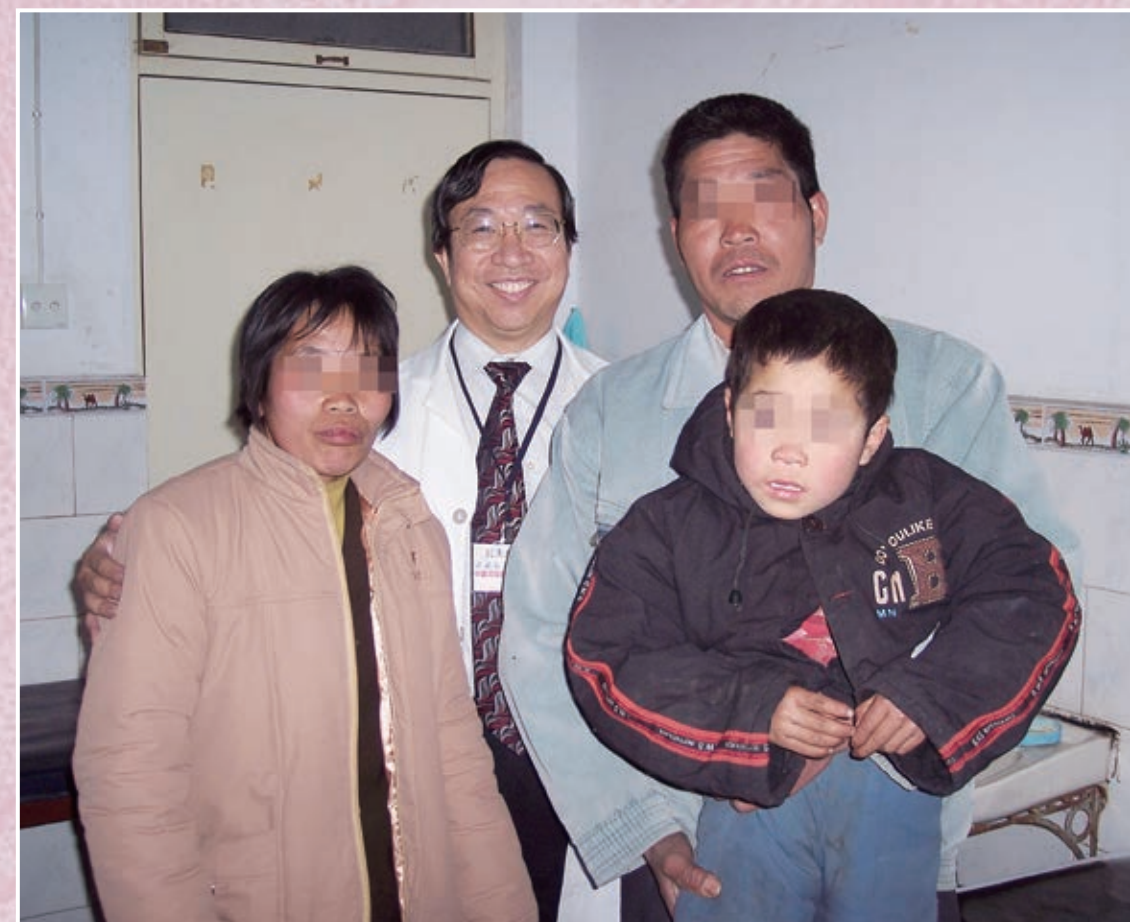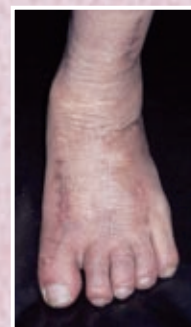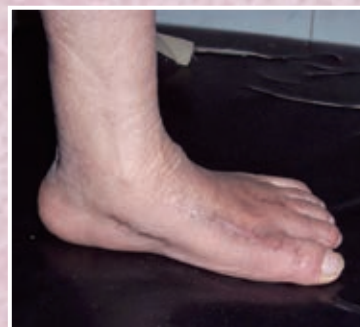After heelcord lengthening and femoral osteotomy surgery, patient was given a plaster cast. He had picture with surgical team members



手術後左足已經矯正，可以平放地上。因為左下肢比較短，所以把鞋底加高了。

The left foot was plantigrade after surgery. A shoe lift was added due to shortness in the left lower limb.

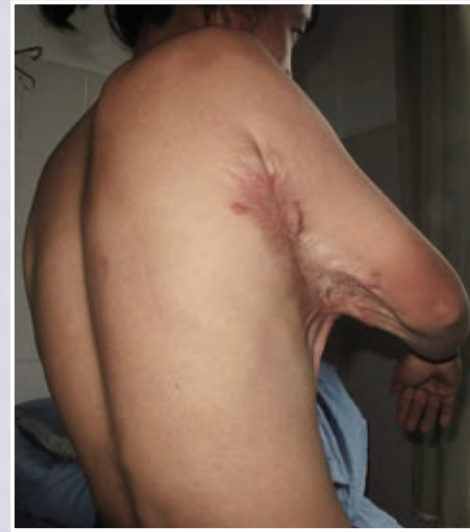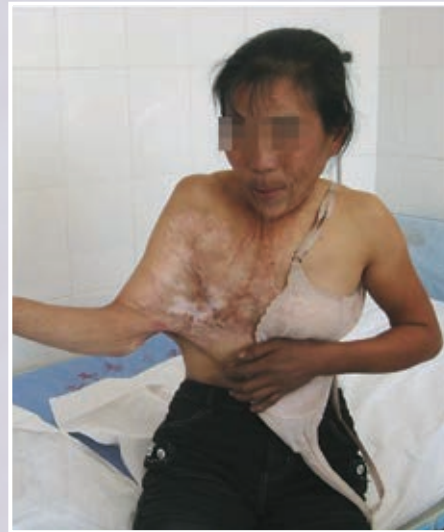康復後走路不需要用手按著大腿。
The hand-knee gait resolved after surgery.



病人說：「手術前，走路時手要扶著膝蓋，很不方便。手術後腿有力了，不用手扶，感覺很好，幫助很大。以前，只能用一隻手拿東西，現在可以兩隻手都用來拿東西。手術前連抱孩子都不能，現在可以了。」

Patient said, "Before surgery, I had to use a hand to support the thigh. It was very inconvenient. After surgery, my leg is stronger and no longer needs support with my hand. The operation is very helpful. The feeling is good. In the past, I could only use one hand to hold objects. Now, I can use both hands. I was unable to hold my son before, now I can do it."

M 002

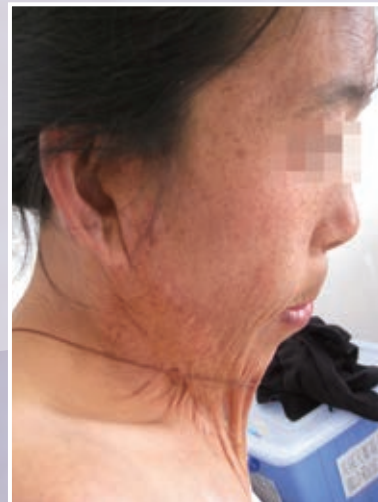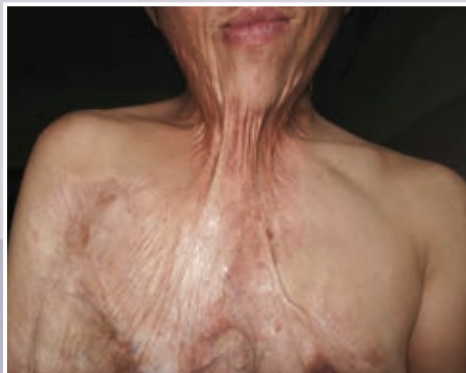


多處燒傷後疤痕、多部位攣縮

Multiple Burn Scars, Multiple Contracture

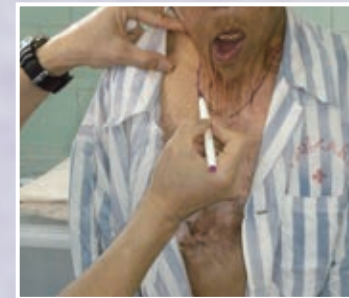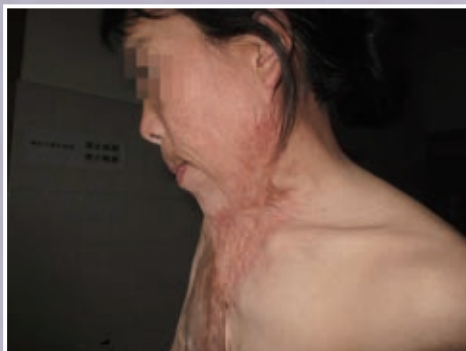20 多歲時嚴重燒傷的女病人，疤痕令右側肩膀和右上臂不能活動。

A female burn patient in her twenties. Dense scars prevent movement of the right shoulder and right arm.

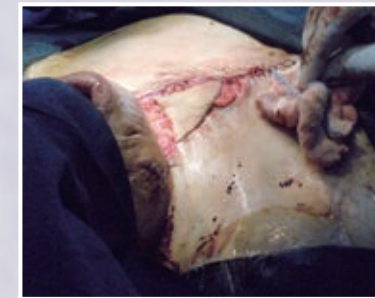


疤痕防止頸部的活動。令麻醉增添困難。

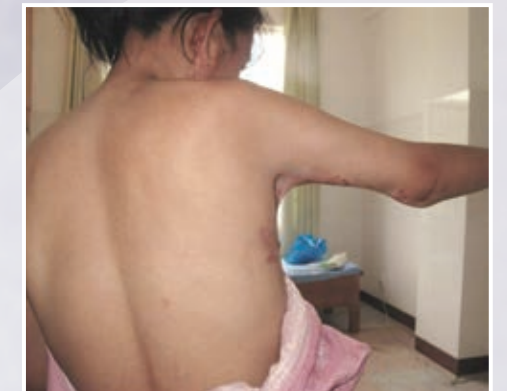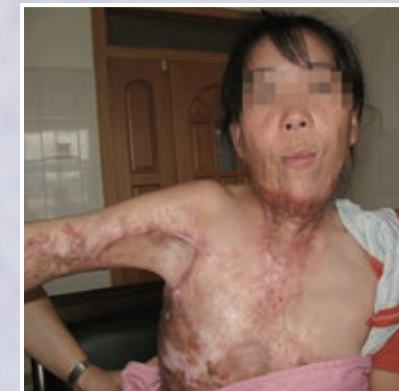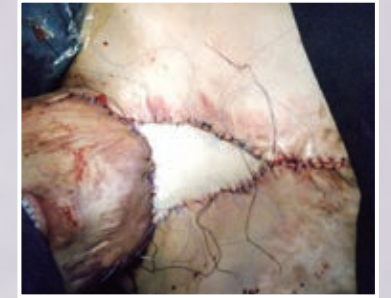
Movement of the neck was greatly limited by burn scars. This caused difficulties in intubation during anesthesia.



手術開始前之計劃。
Planning before the surgery.

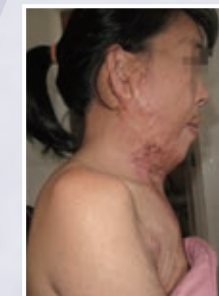
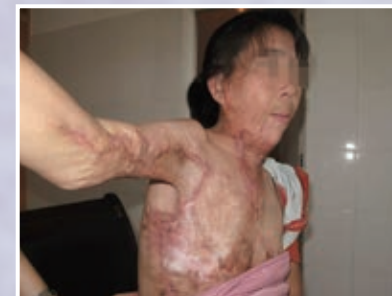
疤痕切除後，把新皮植上。
Transplanting new skin to the wound after excision of scars.



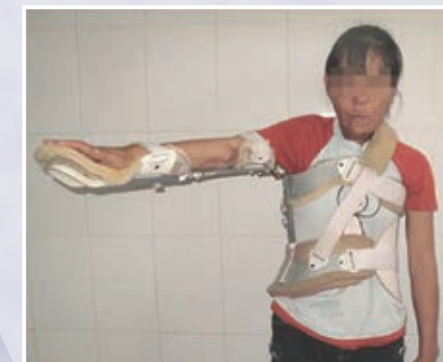手術後頸部、肩膀和上臂的活動能力大大改善。

Great improvement of range of motion in the neck, right shoulder and right arm after surgery.



矯形外科和骨科醫生工作了 13 小時才完成手術。

It took 13 hours for the plastic surgeon and orthopaedics surgeon to complete the operation.



康復時配帶的支具，避免疤痕收縮。

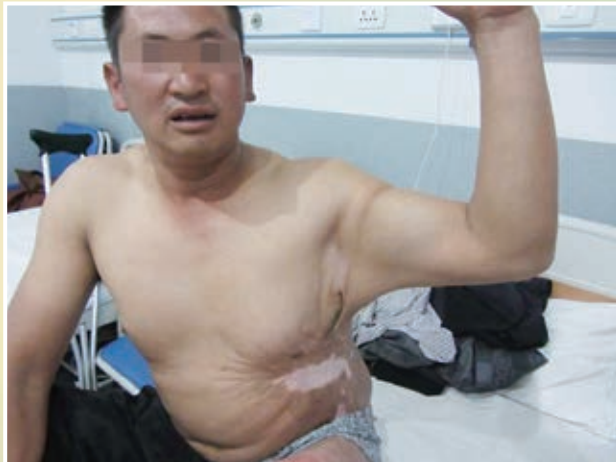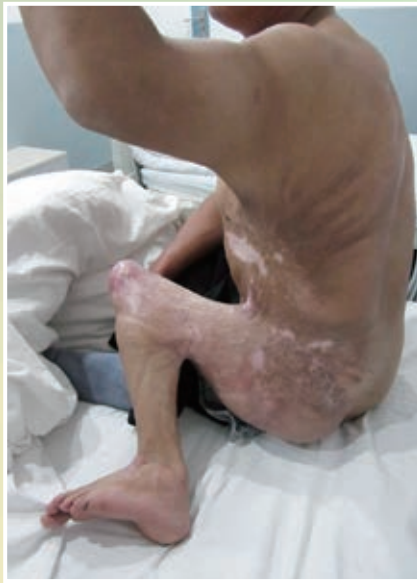A brace used after surgery to prevent contracture of scars.

嚴重燒傷、多部位變形

Severe Burn Contracture & Deformities

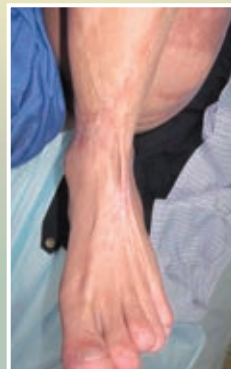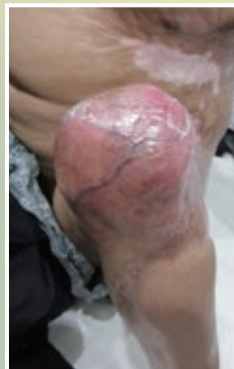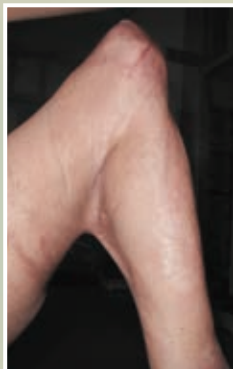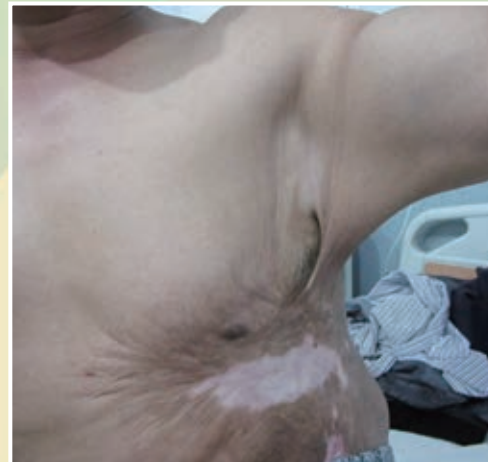37 歲男士，一歲時被熱水嚴重燙傷，身體多處有疤痕，令左側身軀及下肢變形，髖及膝關節屈曲，不能活動，站立和走路困難。

37-year-old male patient scald by hot water at age one leading to severe scars over the left side of body. Severe hip and knee joint contracture with no movement. Very difficult to stand or walk.



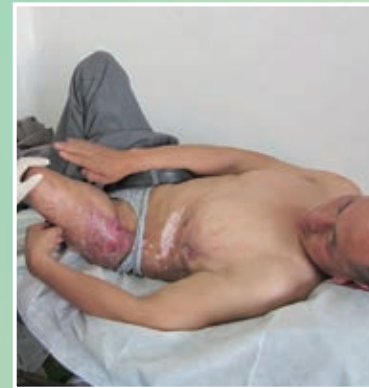疤痕令左側肩膀不能抬高，胸部疤痕令深呼吸困難。

Scars over the left axilla made elevation of shoulder difficult. Scars over the chest caused difficulty in taking deep breath.



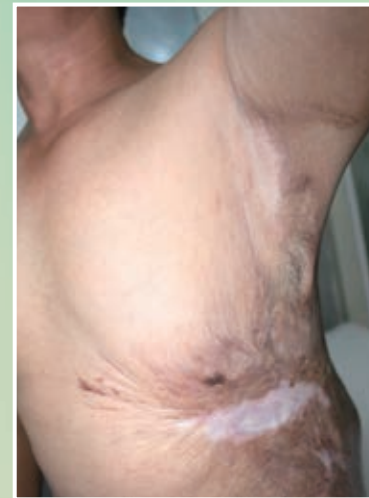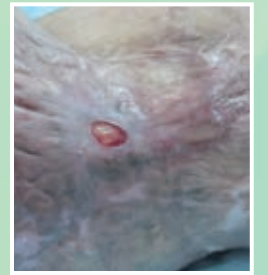左側髖、膝及踝關節均僵硬，不能活動。

Severe contracture of left hip, knee, and ankle with no movement.



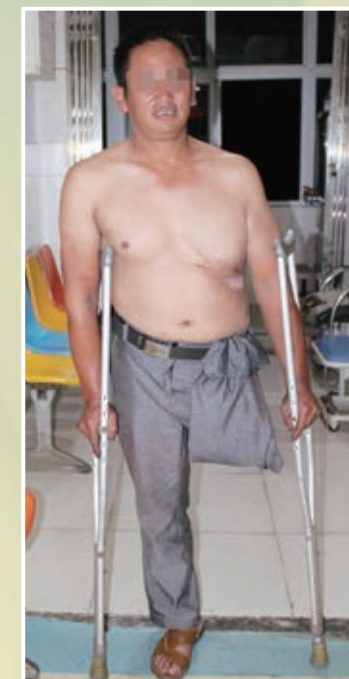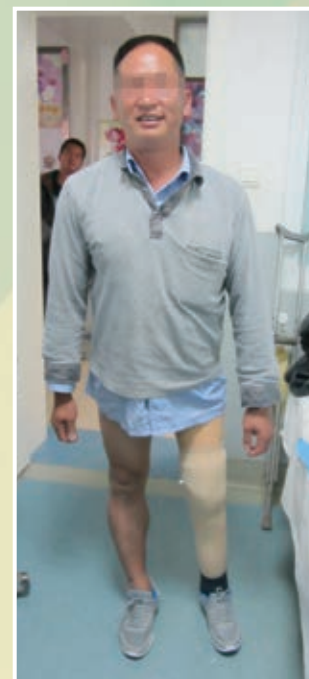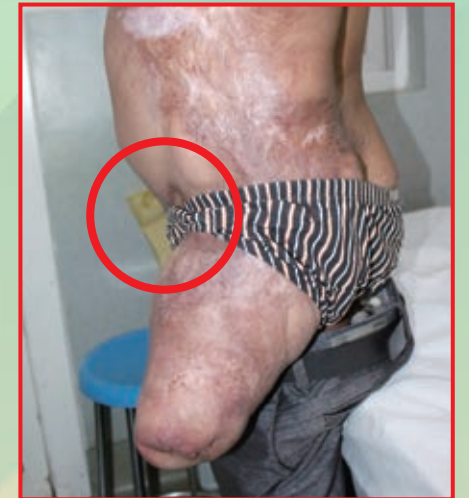手術將部分疤痕切除，植上新皮，左下肢作膝上截肢。手術後左側腹股溝傷口持久未痊愈。

Operation included excision and release of scars, skin graft, and skin flap. The left groin wound took a long time to heal.



原本僵硬的髖關節恢復部分活動。

The ankylosed left hip regained partial movement.



手術後左側肩膀活動能力增加。深呼吸比以前容易。

After surgery, the range of movement of left shoulder increased. Taking deep breath is easier.

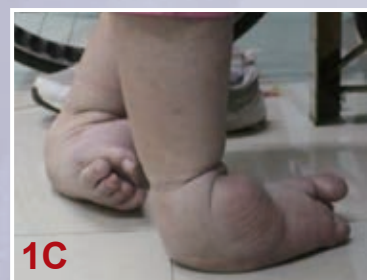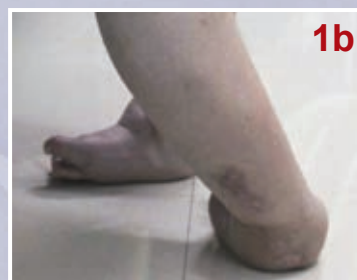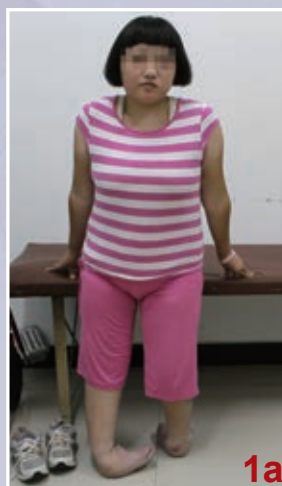
康復後，可用拐杖或義肢走路。

After rehabilitation, patient was able to walk with above knee prosthesis or by crutches.

M 004

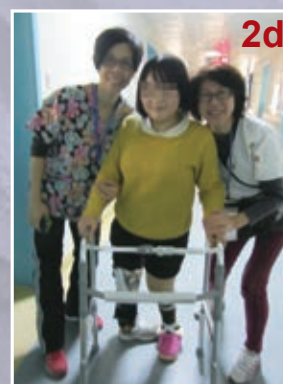
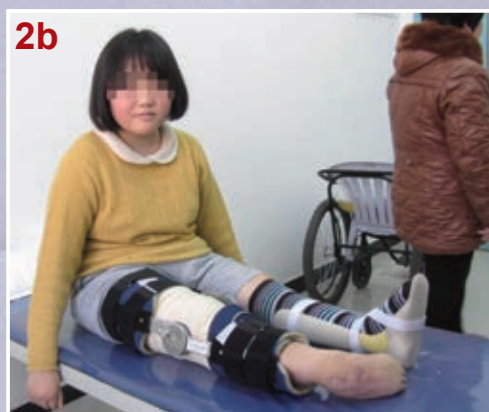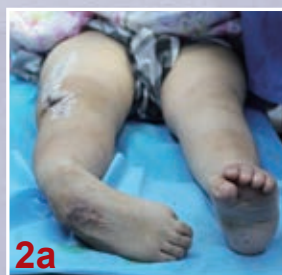脊柱裂症、雙側高弓、內翻及馬蹄足 右側四頭肌肌腱破裂

Myelomeningocele, Bilateral Equinovarus Feet
Ruptured Right Quadriceps Tendon



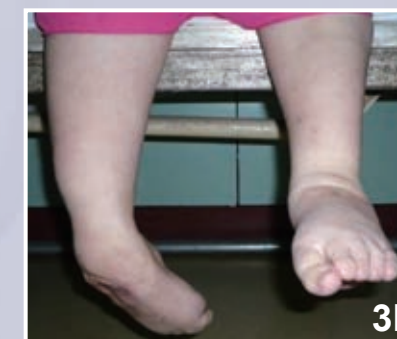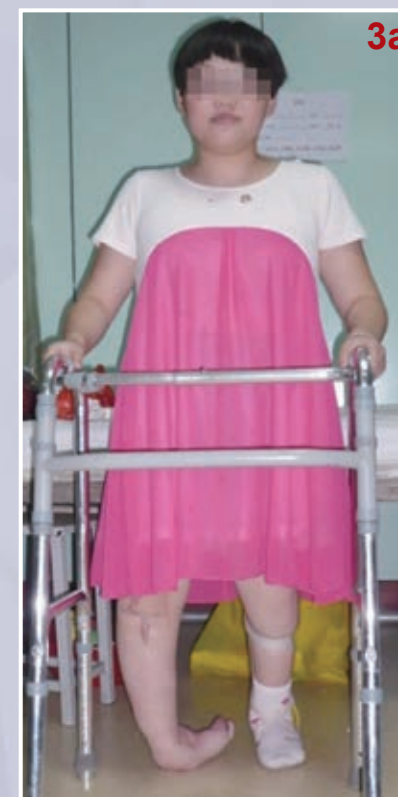1a,1b,1c 17 歲患脊椎裂症女病人，自小雙足變形，站立困難，幾乎不能走路。而且右膝四頭肌肌腱因意外折斷，右膝不能活動（2017）。

17-year-old 'myelomeningocele' female patient. Developed severe foot deformities since early childhood. Has difficulty standing. Barely able to walk. Ruptured right quadriceps tendon from accident, unable to move the right knee (2017).



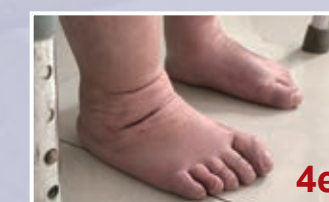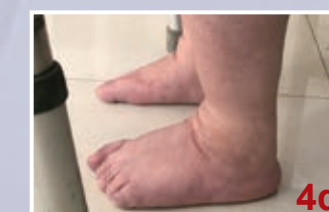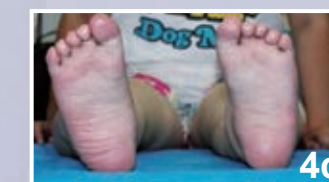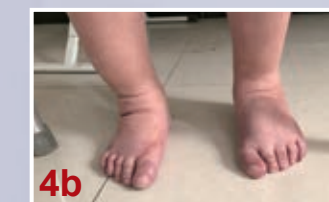2c,2d 手術後做物理治療。
Physiotherapy after surgery

2a,2b 手術將右膝四頭肌肌腱修補及矯正左腳變形。
After surgery to repair the right quadriceps tendon and correct the left foot deformity.

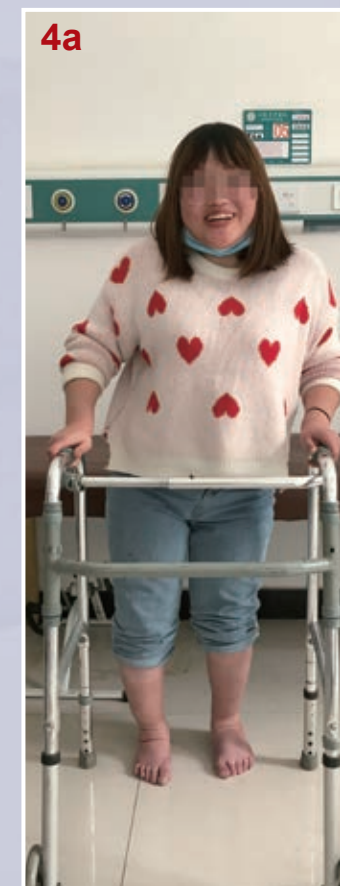

3a,3b 翌年（2018），接受右腳手術前照片，左足及右膝已矯正。

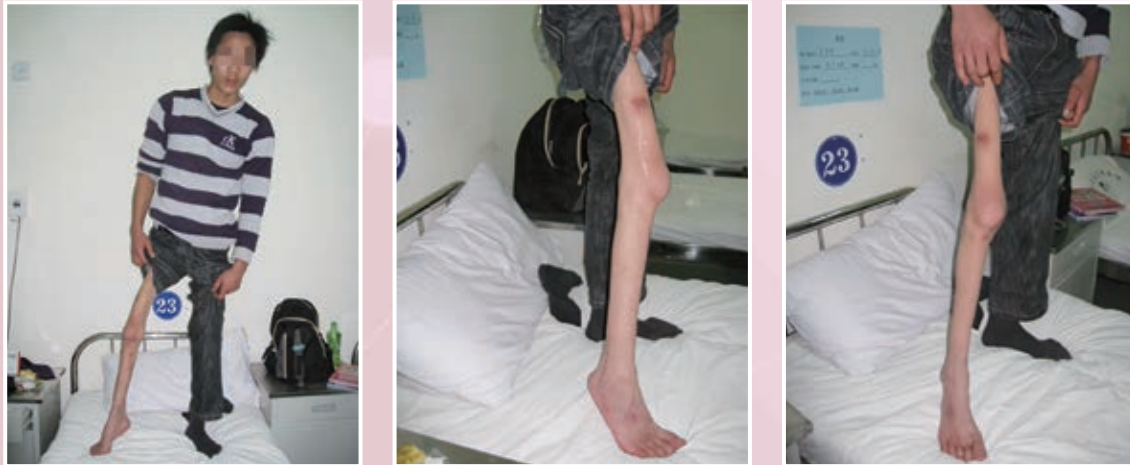Next year (2018), picture before surgery on the right foot. In the last surgery, right knee and left foot were well corrected.



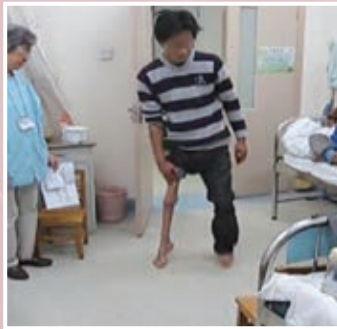4a-4e （2019）兩足均矯正好，可以用助行器或拐杖行路，在家可以不用輔助工具步行。
(2019) Both feet are well corrected. Able to ambulate with a walker. Can walk without aid at home.



M 005



右膝關節攣縮，右大腿上有以前手術留下的疤痕，此外，腿上的老繭皮是因為長年慮月用手按著走路而形成的。右下肢短了，右腳成馬蹄狀。



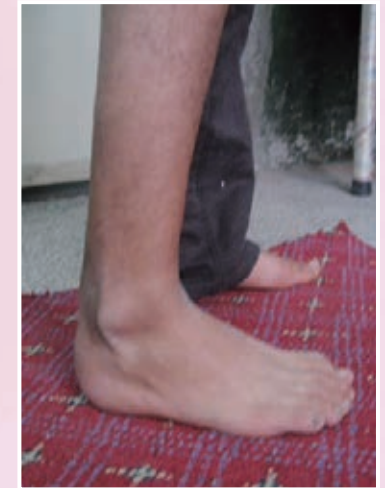
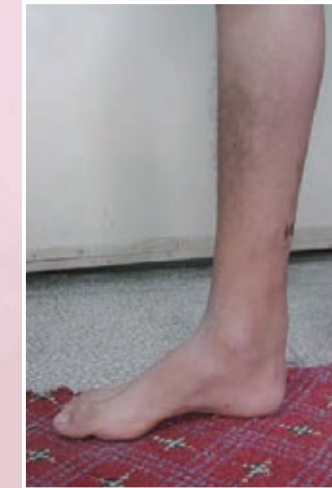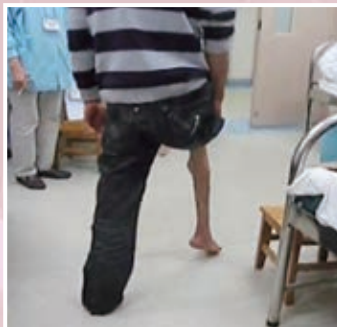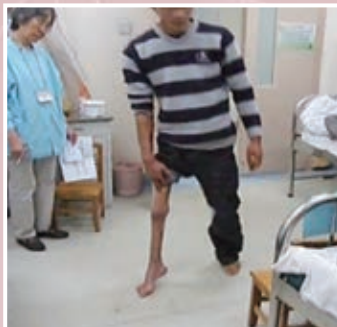Patient's right knee had flexion contracture. Old surgical scar was noted. The callosity over the right thigh was due to prolong pressure from the right hand on walking. The right lower limb was shorter and an equinus deformity developed.

兒麻後遺症 右膝關節攣縮、右馬蹄足

Post-poliomyelitis Deformities Right knee contracture Right Equinus

一位河南男子，年幼時患小兒麻痺症，令右下肢萎縮無力，生長緩慢而短了，而且右側膝關節收縮。雖然曾經在當地醫院做過手術，依然未能完全伸直右膝，走路要用右手按著大腿來支撐。

A gentleman from Henan. He suffered from poliomyelitis in childhood leading to weakness, wasting, and shortening of the right lower limb. Despite surgery by local hospital, there was residual flexion contracture of the right knee. He had to use the right hand to support the right thigh on ambulation.




手術後 After Surgery

右腳手術後已經可以平放地上，右膝關節能夠完全伸直，走路時右下肢可以負重，不需要用手按著大腿。

After surgery, the right foot is corrected and put flat on the ground. The right knee can fully extend and bear weight without using the hand for support.




M 006



右髖關節攣縮，固定在外展及屈曲位置，不能伸展。

Right hip contracture and was fixed in abduction and flexion, unable to extend.



右馬蹄足，不能放平。
Right equinus foot.

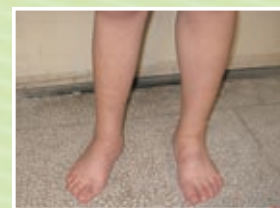
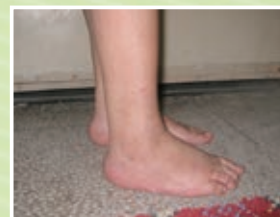
兒麻後遺症、右髖關節攣縮、右馬蹄足

Post-poliomyelitis Deformities, Right Hip Contracture, Right Equinus

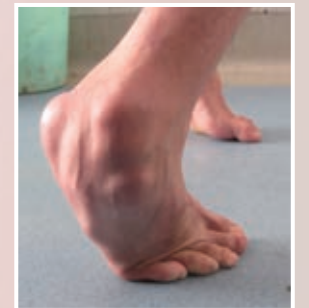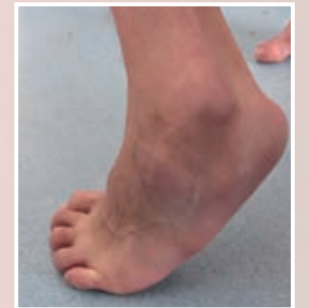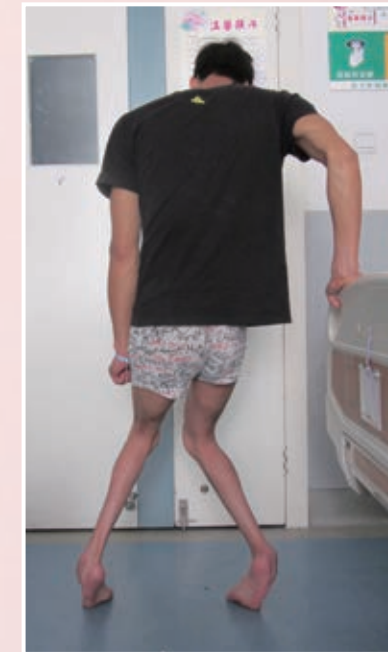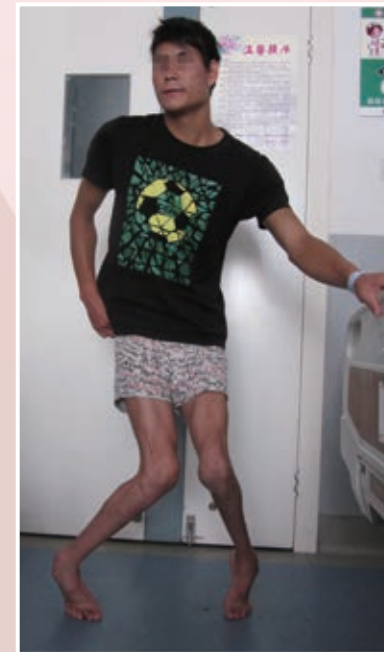一位 17 歲小兒麻後遺症女病人，右髖關節攣縮，不能站地，右腳亦變形成馬蹄足。接受了鬆解手術後，右髖關節和右足已經回復正常位置。

A 17-year-old lady with post-poliomyelitis deformities including right hip contracture and right equinus. The alignment of the hip and foot are normal after release procedures.

手術後
After
Surgery



M 007



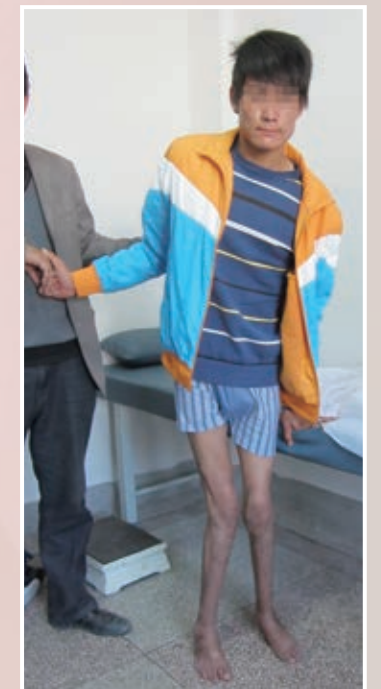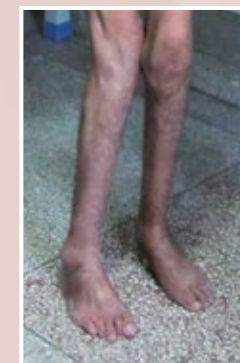
腦癱 Cerebral Palsy

一位 24 歲的大理男士，因為患有腦癱，雙下肢肌肉非常緊張，髖部、膝部及雙腳均有痙攣現象，不能隨意控制。站立時雙腳只用腳趾負重，不能平放地上，姿勢不穩及需要用手支撐身體，走路困難。

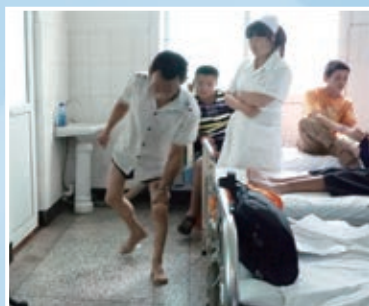A 24-year-old cerebral palsy patient from Dali. He had spasticity and contractures in both lower limbs. On standing, he was unable to put the feet flat on the ground and was bearing weight on the toes only. Standing was unsteady and walking was very difficulty.

手術把髖部、膝部及雙足的肌腱放鬆。手術後雙腳可以平放地上，姿勢和步伐比較平穩和輕鬆。

After soft tissue releases of hips, knees and both feet, patient was able to stand with feet plantigrade and the gait was steadier.

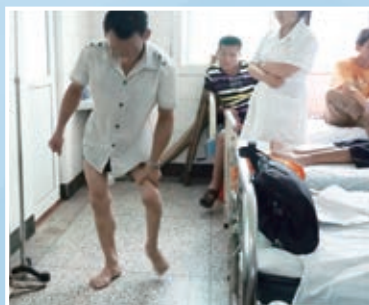

M 008



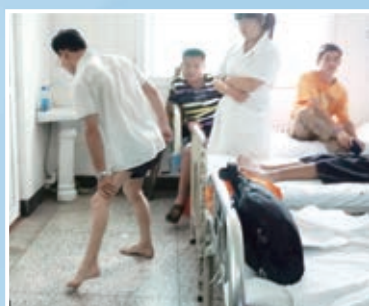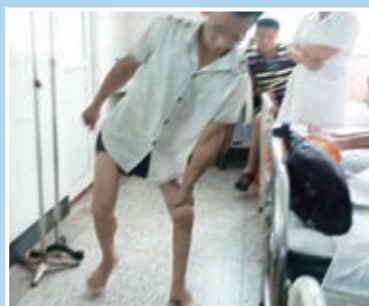小兒麻痺後遺症 左側膝關節攣縮 左側馬蹄足

Post-poliomyelitis Deformities
Flexion Contracture Left Knee
Equinus Deformity Left Ankle



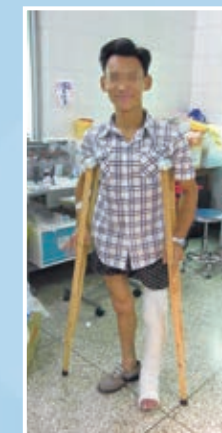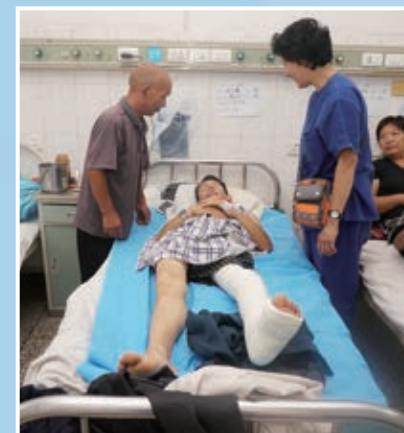一位 23 歲河南男子，幼年患小兒麻痺症，令左側膝關節攣縮，不能完全伸直，走路時需要用左手支撐大腿，方能讓左腳負重。此外，左跟腱收縮，令左足成輕微馬蹄狀。

A 23-year-old man from Henan. He suffered from poliomyelitis during childhood leading to flexion contracture of the left knee. The knee was unable to fully extend. Patient had to use the left hand to support the left thigh on weight bearing. There was also contracture of the left heelcord leading to mild equinus deformity of the left foot.



注意患者走路時必須用左手支撐大腿，方能負重。

Please note that patient had to use the left hand to support the left thigh on weight bearing.



病人接受了左股骨截骨及左跟腱延長手術，打了石膏，手術後與主治骨科醫生及物理治療師合照。

Patient had surgery including osteotomy of the left femur and lengthening of the left heelcord. A long leg cast was applied after surgery. He was posing for photo with his surgeon and physical therapist.



手術後兩個月回來覆診，左膝關節可以完全伸直，左腳亦可以平放地上。

At two month follow up, patient's left knee can extend fully. The left foot equinus deformity is fully corrected.

在手術後一年，病人康復得非常好，可以單腳而站。

At one year follow up, patient recovered very well. He can stand on one foot.

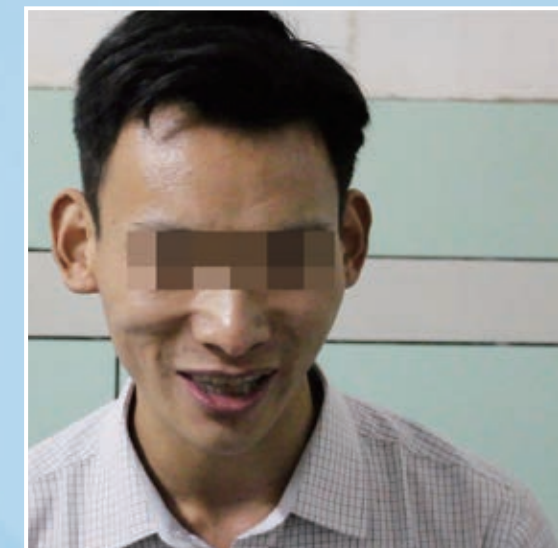


M 009



病者現在可以自由上、落樓梯，不用扶持，左下肢能够正常地負重。

Patient is able to go upstairs and downstairs at will without support. The left lower limb can bear weight normally.



病人說：「開車時左腳是管離合器的，手術前，左腳完全不能踏下去，現在就可以踏下去了。」

我現在走路速度不慢，跟正常人一樣。不會跟在後面，與其他人一樣，齊頭並進。

手術對我幫助很大，改變了我的人生。如果只依靠自己和家人的力量去完成這手術的話，相信需要很長的時間，感覺可能不會完成。未想到有這一個好像從天而降的機會。

我看到您們就好像見到親人，而且經常很想念您們。」

Patient said: "On driving, the left foot is to control the clutch. Before surgery, it could not press down. Now I can press down with no problem."

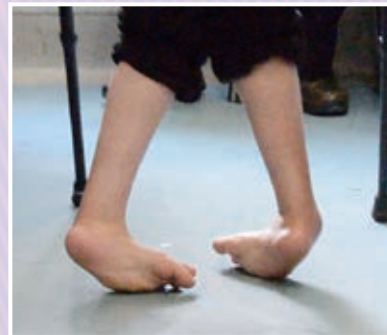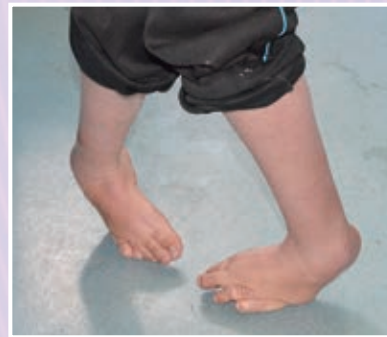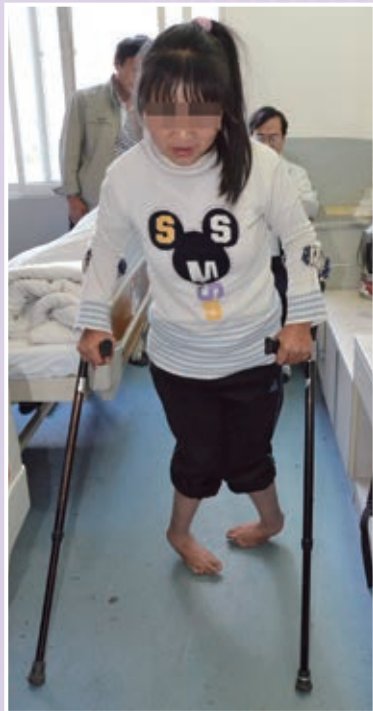On walking, my speed is normal. I won't fall behind. I walk just as fast as normal people.

The surgery is very helpful to me. It changes my life. If I only rely on the ability of my family and myself to have this operation, it will take a long time. Probably it can never be accomplished. I never thought of such an opportunity to have surgery. It is like a gift from Heaven.

When I see you, I feel like seeing my family. I frequently think about you."

M 009

腦癱 Cerebral Palsy

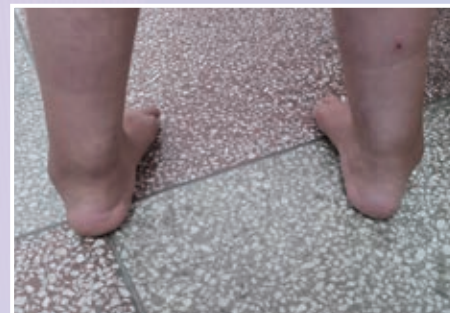
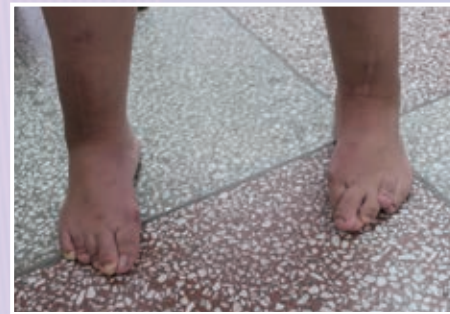

一位 17 患腦癱的女病人，下肢痙攣嚴重，控制困難，走路時只用腳尖著地，步行非常不穩。

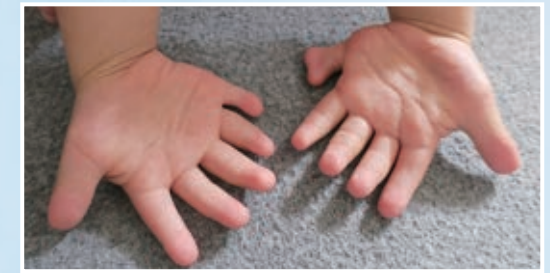A 17-year-old female cerebral palsy patient. Had severe spasticity in the lower limbs. Weight bear on toes only. Walking was very unsteady.

手術把膝部和腳部肌腱放鬆，雙足可以平放地面，站立及走路比以前穩定，不用拐杖亦可步行短距離。

Release of tendons around the knees and both feet were performed. Both feet are plantigrade and the gait is more stable. Patient is able to walk for short distance without crutches.



M 010



雙側膝外翻、多指

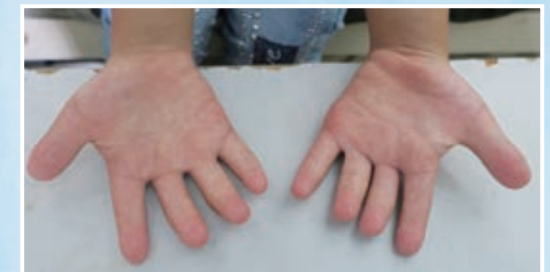Bilateral Genu Valgum, Polydactyly Both Hands

她是一個在伊拉克難民營的 7 歲女孩子，非常害羞又非常可愛，常常依在媽媽身旁。她天生每隻手有六個指頭，此外，兩個膝關節漸漸外翻。

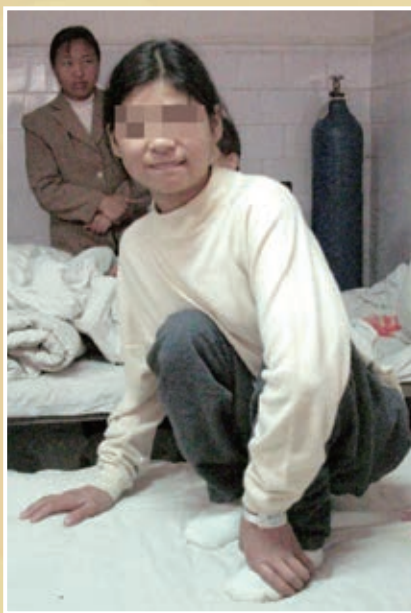She was a 7-year-old girl in the refugee camp in Iraq. She was shy and lovely and like to lean against her mother. She was born with six digits in each hand. She also developed progressive bilateral knock knee deformities.

手術後，多餘的手指被切除，雙側膝關節外翻已經矯正。

After surgery, the extra digits were removed and the alignment of lower limbs normal.



M 011

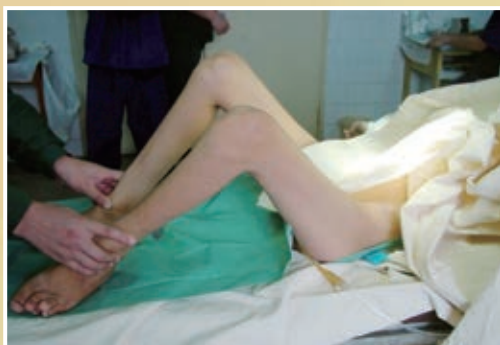
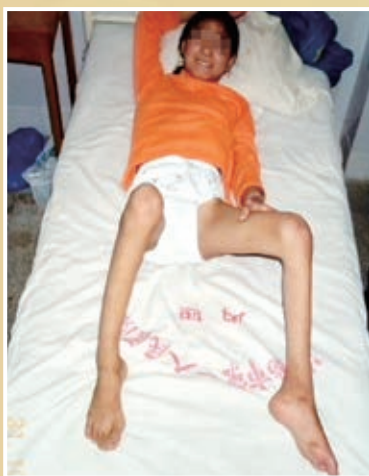
兒麻後遺症 雙側髖關節及雙側膝關節攣縮

Post-poliomyelitis Deformities Bilateral hip & knee contractures

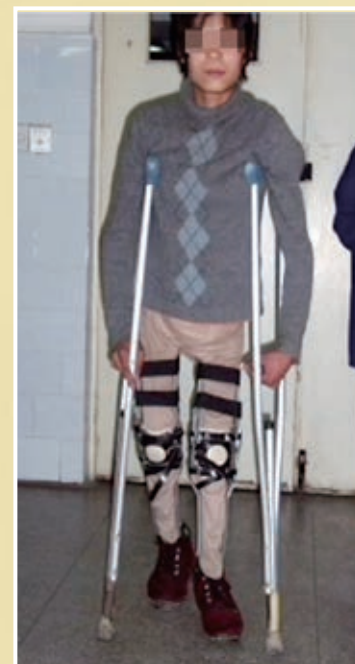一位 14 歲的河南少女，因為年幼時患上小兒麻痺症，令雙下肢癱瘓，失卻大部份肌肉功能，雙側髖關節及膝關節攣縮，不能站立，只能蹲在地上，屈曲著關節而行。

A 14-year-old girl from Henan. She had poliomyelitis at early age leading to lost of most motor functions in the lower limbs. Both hips and knees had severe contracture. She was unable to stand. To get around, she needed to squat down and moved with hips and knees in flexion.

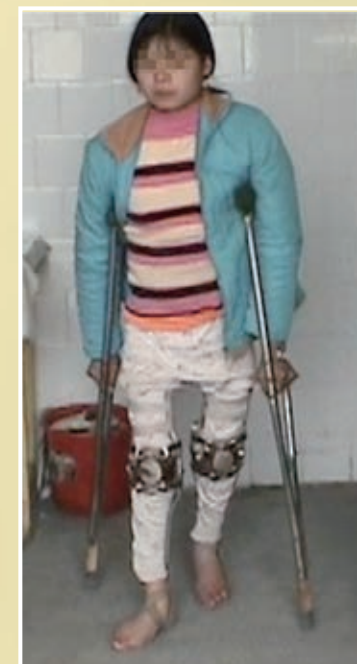

手術前檢查，雙髖關節及膝關節不能伸直。

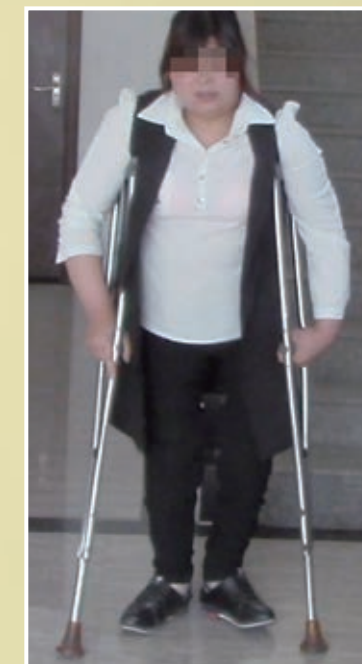Examination before surgery showed that both hips and knees could not be stretched out.



手術後 1 年
One year after surgery



手術後 3 年
3 years after surgery



手術後 17 年
17 years after surgery

手術後，下肢的攣縮已經矯正，配上支具，可以用拐杖走路。

After surgery, the contracture of lower limbs were corrected. Patient was able to ambulate with bilateral long leg braces and crutches.

17 年後陳志偉醫生探訪病人，她已經結婚成家，育有兩名子女。

Dr. W.C. Chan visited the patient 17 years later. She is married with two children.



M 012

小兒麻痺後遺症 右側膝關節攣縮、右側仰趾足

Post-poliomyelitis Deformities Contracture Right knee, Right Calcaneal Foot

一位9歲的河南女孩，因為幼年時患小兒麻痺症，令右下肢部分癱瘓，右膝關節收縮，不能完全伸直，走路時要用右手按在大腿上，才能負重。此外，右腳因為肌肉不平衡，變成仰趾足，走路時只能用腳跟著地用力，所以步伐不穩及困難。



A 9-year-old girl from Henan. She had poliomyelitis in early childhood leading to weakness in the right lower extremity. There was contracture in the right knee. On walking, she had to use the right hand pressed onto the right thigh to support the knee on weight bearing. Further, there was a calcaneal deformity of the right foot due to muscle imbalance. The foot could only weight bear on the heel. The gait was unsteady and ambulation difficult.

病人（左）膝部手術後打了石膏，與陳志偉醫生拍照。

Patient (left) had a cast put on after knee surgery. She had photo with Dr. C. W. Chan.

兩年後病人接受肌腱轉移手術，把右腳矯正。

Two years later, patient had a tendon transfer procedure for correction of right foot deformity.



15年後，醫療隊隊員去探望舊病人，她已結婚成家，育有兩個孩子，住在小鎮裡，丈夫做小生意，舊病人協助丈夫，當司機送貨。

15 years later, members of surgery team visited the old patient. She was married with two young children. They lived in a small town. The husband was running a small business and old patient was helping as a driver, delivering goods.



舊病人步伐不完全正常，右足負重時身子會有點歪，但是她行動自如，沒有不適，生活完全自理。

Patient's gait is not normal with the body listing to the side when right foot was weight bearing. However, she has no discomfort. Patient is completely independent on ambulation and self care.

M 013



兒麻後遺症 兩側髖關節及膝關節攣縮

Post-poliomyelitis Deformities Bilateral Hip & Knee Flexion Contracture

一位 21 歲河南女子，幼年患小兒麻痺症，令下肢肌肉萎縮無力，雙側髖關節及雙側膝關節嚴重攣縮，不能伸直，不能站立。長久以來只能蹲著，用手把小腿送前來走路。

她接受了雙側髖關節鬆解和雙側股骨髁上截骨手術，把下肢伸直，配上支具後，可以第一次站立，並且用助行器走路。

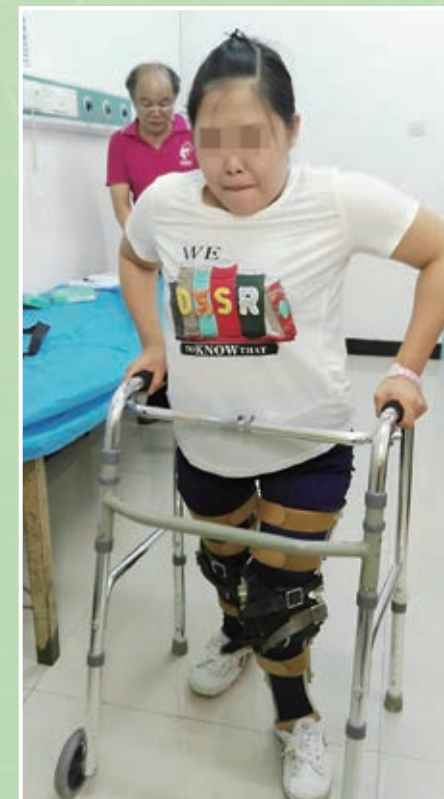A 21-year-old lady from Henan. She had poliomyelitis in childhood leading to weakness and wasting of both lower limbs. There were severe flexion contracture in both hips and both knees. She was unable to stand. For ambulation, she had to squat down and used her hands to move the legs forward.

Patient had bilateral hip releases and supracondylar osteotomy of femur done. The surgery allowed her to extend her hips and knees. After fitting of braces, she was able to stand for the first time. She was also able to walk with a walker.



手術後病人與手術隊員合照。

Patient had photo taken with a member of surgery team after surgery.



手術隊即將離開，隊員在病人的石膏上寫上祝福的字句。

Surgery team members wrote words of blessings on patient's plaster casts before departure.



耶穌愛你、福杯滿溢。

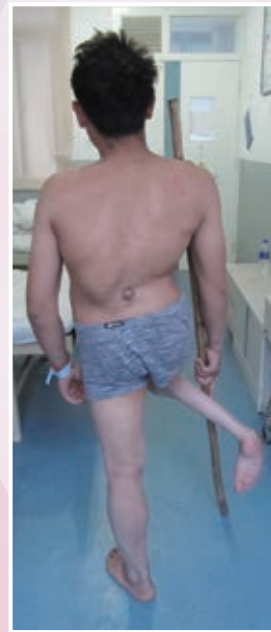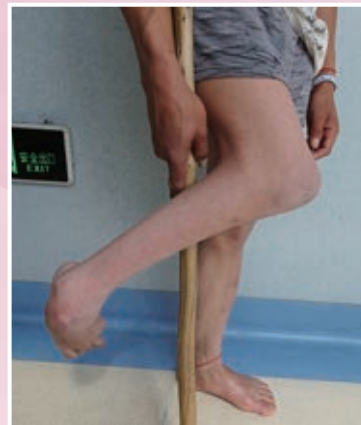Jesus love you. Overfilled with blessings.

病人穿上支具，用助行器練習走路。

Patient had bilateral long leg braces and practiced walking with a walker.

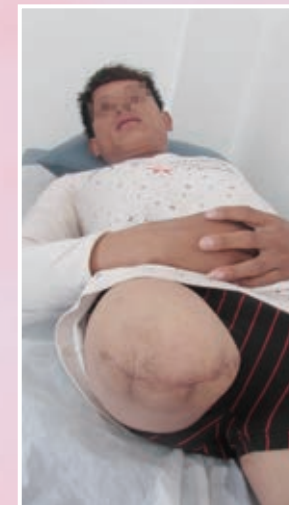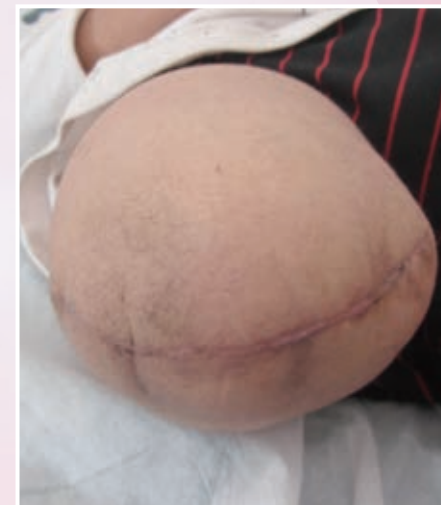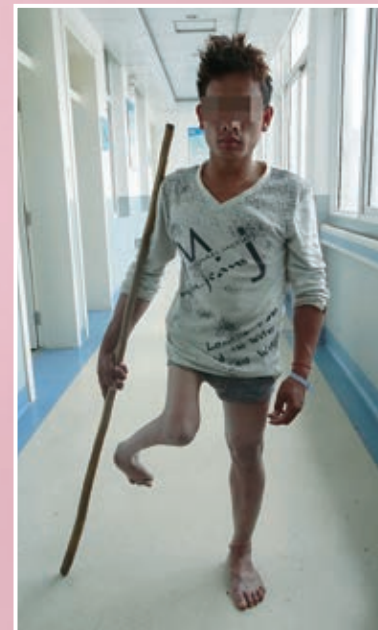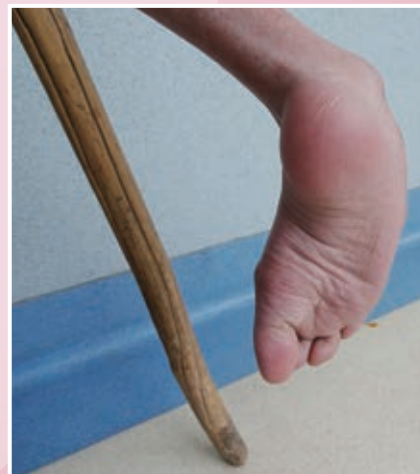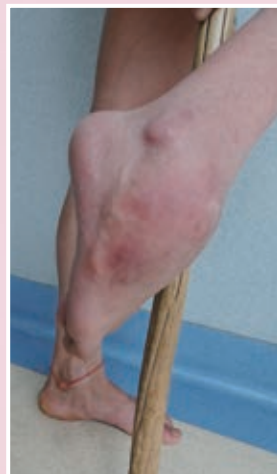M 014

脊柱裂症、多關節攣縮 Myelomeningocele Multiple Joint Contracture



一位大理男病人，患脊柱裂症，右下肢大腿以下癱瘓、收縮及僵硬，膝關節、踝關節及足部不能活動，已經失去功能。

A Dali male patient with myelomeningocele. There were fixed deformities in the right knee, ankle and foot with no function.



病人接受了截肢手術，把失卻功能的部位切除。

An above knee amputation was performed to remove the part of right lower limb that lost function.



病人後來配了義肢，可以不用拐杖走路。

Patient was fitted with above-knee prosthesis. He is now able to walk without the stick.

M 015



兒麻後遺症、雙側髖關節攣縮

Post-poliomyelitis Deformity Bilateral Hip Contracture






22 歲河南少女，因幼年患小兒麻痺症，令下肢癱瘓，雙側髖關節攣縮，不能站立。只能蹲在地上，用雙手固定雙足，然後把下肢移動向前。

A 22-year-old lady from Henan. She had poliomyelitis in early childhood leading to paralysis of both lower limbs. She was unable to stand because of severe contracture in both hips. To 'ambulate', she had to squat down and use her hands to stabilize both feet and move her legs alternatively forward.



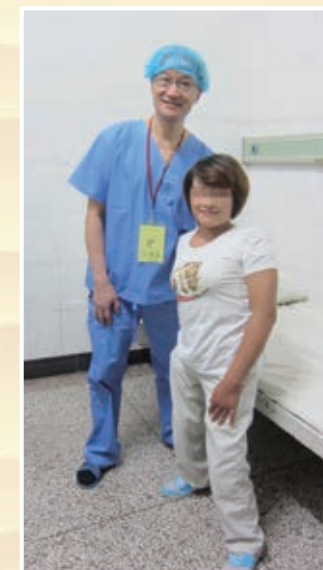手術前蹲著走路姿態。

The way to move forward before surgery.



患者接受了雙側髖關節鬆解手術後，配上支具，可以站立。又可以用拐杖慢慢走路。

After surgical release of both hips and fitting of long leg braces, patient was able to stand. She was able to walk slowly with crutches.



病人手術後與何耀基醫生合照。

Patient had a photo with Dr. YK Ho after surgery.



病人：「手術後站起來的一刻非常激動，因為站起來就是我的夢想，天鄰基金會令我的夢想實現。以前蹲著走路，視線特別低，別人與我說話都要蹲下來。但是現在我站起來了，跟別人可以平視，不用再仰視別人。手術後生活改善很大，以前造飯也要蹲下來，現在可以站著來造飯，像正常人一樣。以前爸爸媽媽見到我蹲著走路，都非常傷心，現在我可以站著走路，他們都很高興。」

Patient said: "I was very excited the first time I was able to stand up, it was a dream came true. HIS Foundation made my dream a reality. In the past when I was squatting down on moving, my eye level was low. People had to lower their body when they talked to me. Now I can stand up and looked at others at the same eye level. Also, in the past my parents felt heart breaking when they watched me squatting down to 'walk'. Now, they are very happy as they see me walking upright."

M 016



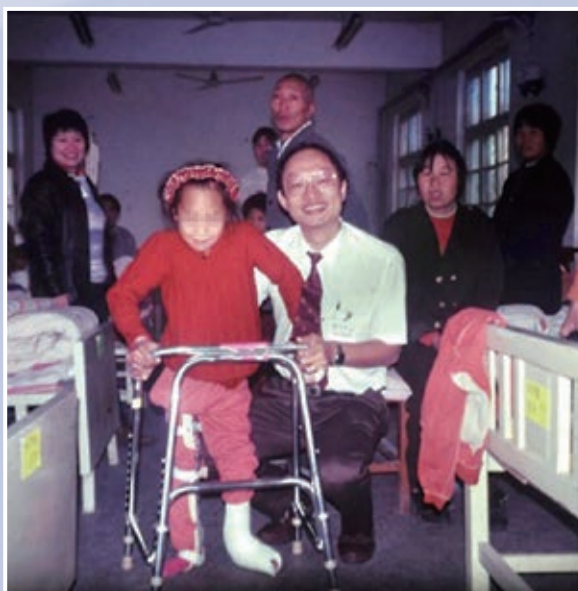**小兒麻痺後遺症
左側髖關節攣縮
左馬蹄內翻足**

Post-poliomyelitis
Deformities
Left Hip Contracture
Left Equinovarus Foot



一位9歲的河南農村女孩，因幼年患小兒麻痺症，令雙下肢軟弱無力，左足變形內翻，左側髖關節攣縮令她不能站立，只能夠在地上爬行。她接受了左側髖關節及左足鬆解手術後，打了石膏，右下肢配上臨時支具，第一次可以用助行器站立及行路。

A 9-year-old girl from rural Henan. She had poliomyelitis in early childhood leading to weakness in both lower limbs. Her left foot was deformed and turned in. Her left hip was contracted making her unable to stand. After surgical release of left hip and left foot, she was given a plaster cast. The right leg was fitted with a temporary long leg brace. She was, for the first time, able to stand up and walk with a walker.



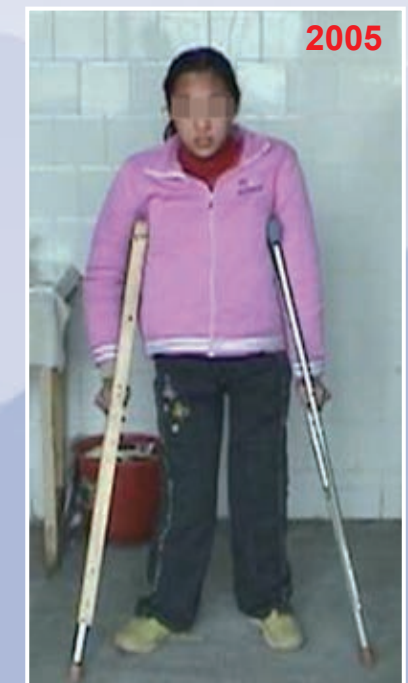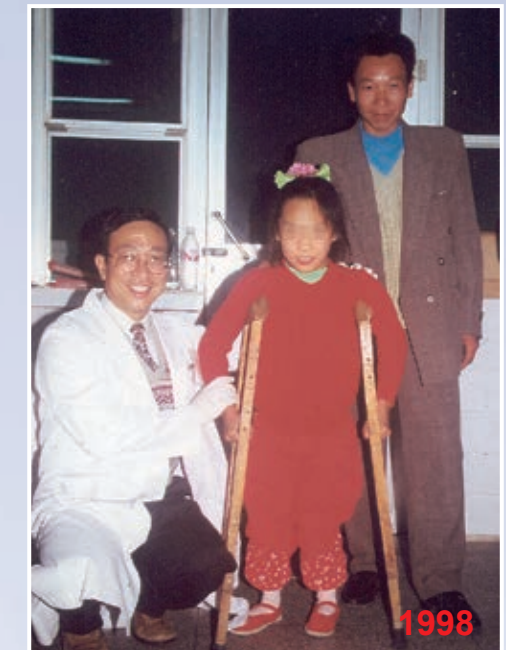翌年回來覆診時已經可以用拐杖走路。
Next year on follow up, patient was able to ambulate with crutches.

2004年，患者接受另一次手術，把左腳矯正。

In 2004, patient had another surgery to further correct her left foot.



2005年覆診，病人用兩拐行走自如。
In 2005, patient was able to ambulate very well with a pair of crutches.



病人於2010年結婚。
Patient got married in 2010.

M 017



2011 年，手術隊探訪病人時，她正懷孕。

Patient was pregnant when the surgery team visited her in 2010.

2018 年手術隊再探訪病人時與家人合照。

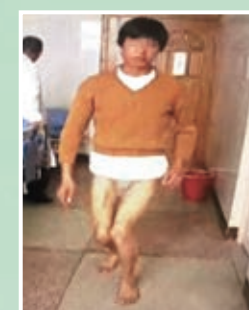Photo taken with patient and family on home visit in 2018.



病人走路的方式是用拐杖支撐身體，然後把雙下肢一起向前送，這樣走路比用左右腿前後跨步走得更快。

Patient utilizes swing through gait for ambulation. She uses the crutches to support the body and both lower limbs were swung forward. This can move faster than reciprocating gait.

M 017



痙攣性腦癱

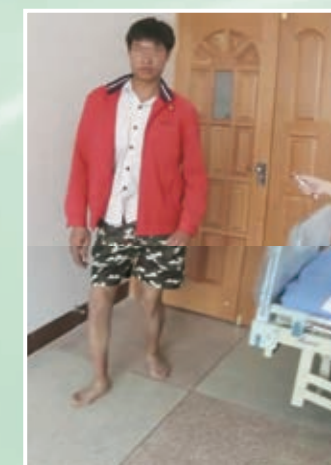


Spastic Cerebral Palsy

一位 18 歲自幼患痙攣性腦癱大理男子，下肢肌肉緊張，走路時髖關節及膝關節彎縮，不能伸直，跟腱收縮，腳跟不能著地負重，步行非常吃力（左圖）。

經過肌腱鬆解及延長手術後，雙側髖關節及膝關節比以前伸直更多，腳跟亦可著地負重，站立及走路都比以前輕鬆，能走的距離也長了（右圖）。

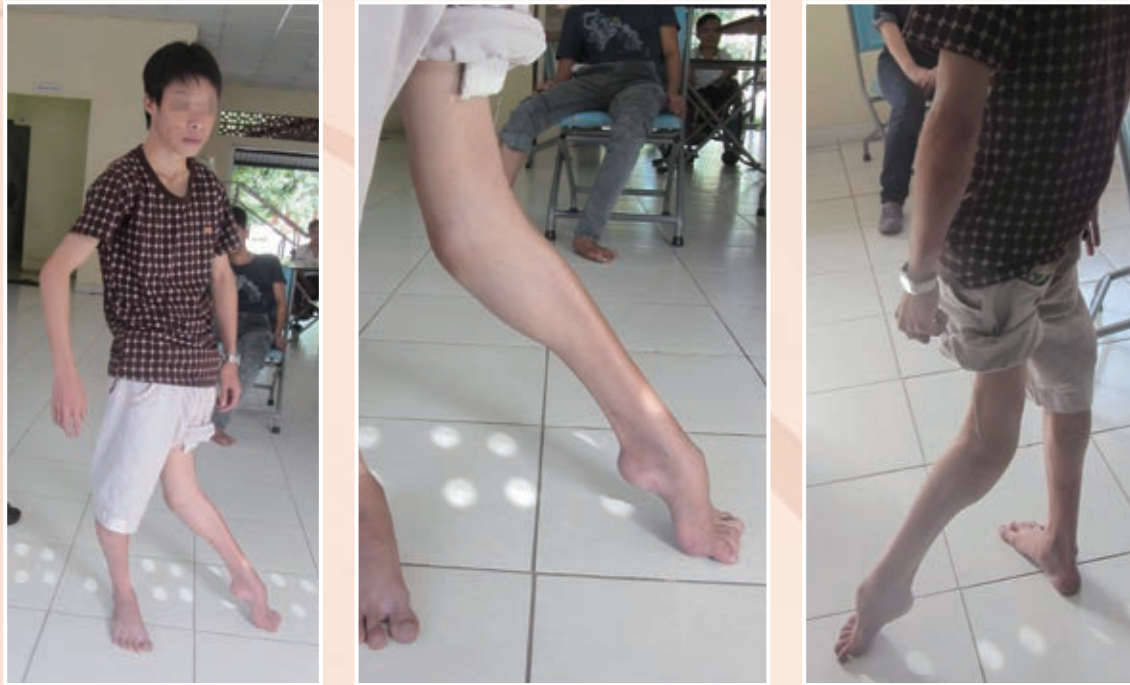A 18-year-old male spastic cerebral palsy patient from Dali. He had spasticity in both lower limbs. On walking, both hips and knees were in flexion. The heelcords were tight and the heels could not bear weight. Walking was difficult (left pictures).

After soft tissues releases and lengthening, both hips and knees can extend more. The heels can reach the floor and bear weight. Patient can stand and walk better. Walking tolerance also increased (right pictures).



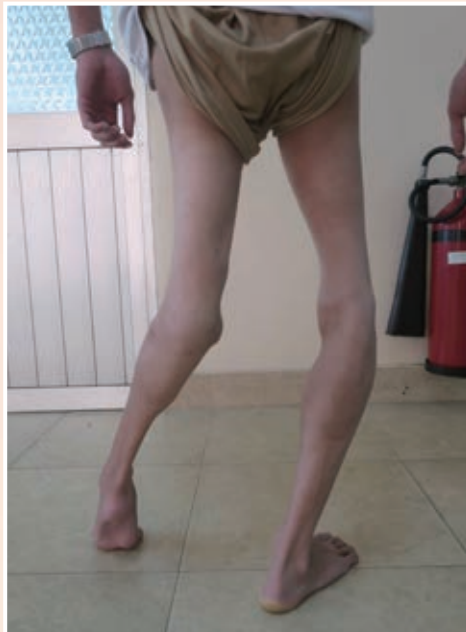手術後
After Surgery

M 018



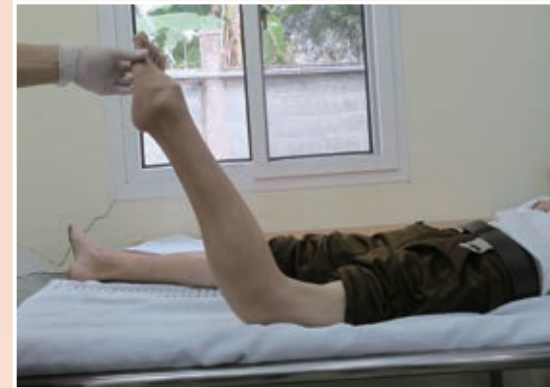左膝反曲、左馬蹄足

Left Genu Recurvatum, Left Equinus



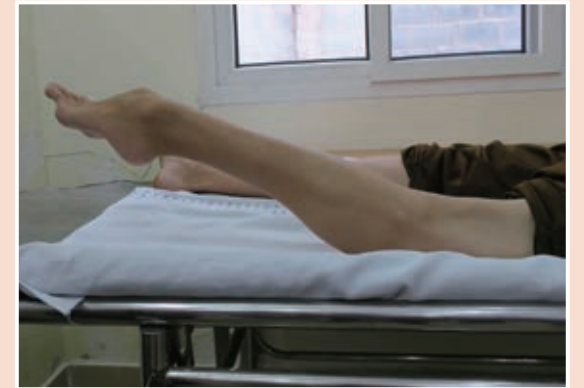一位 26 歲的越南男子，自幼左膝有反曲現象，相信是先天性左膝脫位，而且情況因著成長，變得越來越嚴重。同時左足成馬蹄狀，不能平放地上。

A 26-year-old man from Vietnam. He had genu recurvatum of the left knee since early childhood, probably due to congenital dislocation of the knee. The deformity became worse with growth. At the same time, equinus deformity developed in the left foot making it impossible to put the foot flat on the ground.



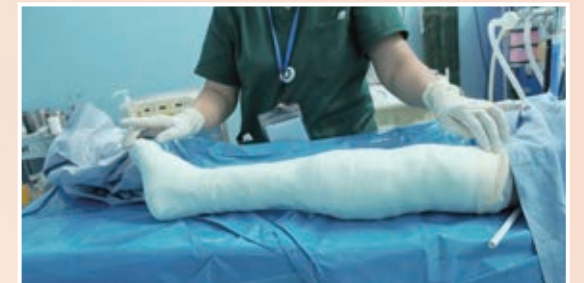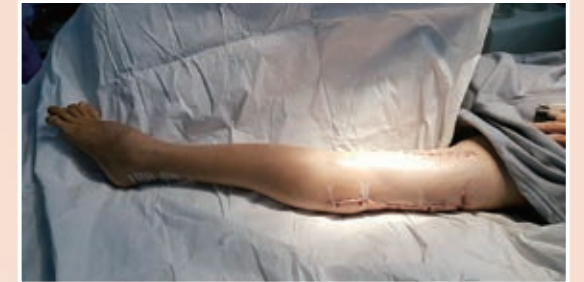手術前，當患者平躺，左膝可以向前不正常地屈曲，但不能伸直平放。

Before surgery, when the patient is supine, the left knee can bend forward abnormally but cannot be kept flat on the bed.



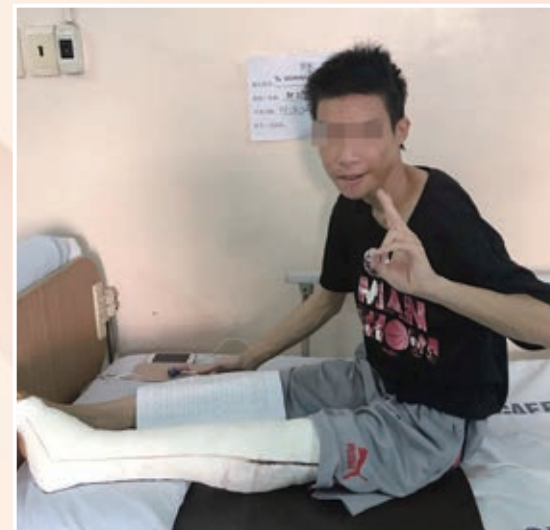經過韌肌鬆解和截骨手術後，左膝可以放平，接着打上石膏以保持位置。

In surgery, after soft tissues release and osteotomy, the left knee could be put flat on the table. A plaster cast was applied to maintain the alignment.

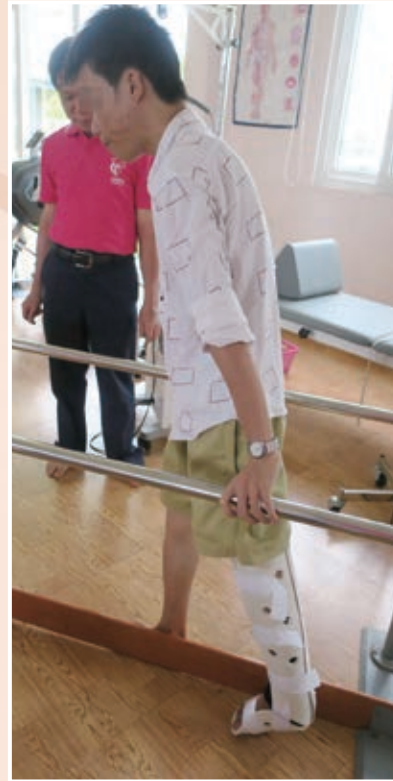
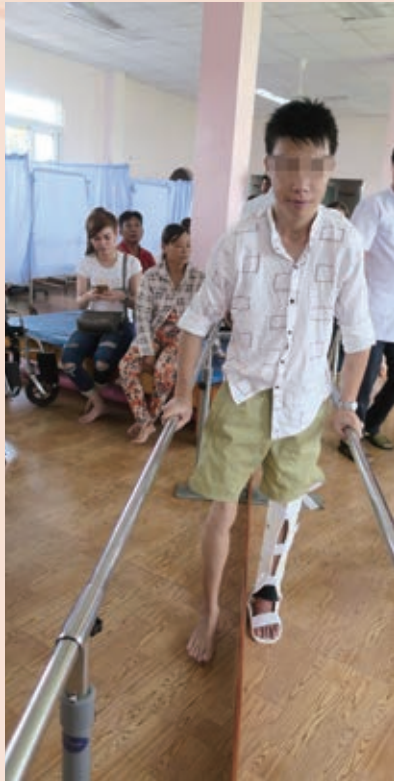
手術後患者在病房休息，石膏暫時切開以免手術後腫脹引致不適。

Patient was resting in bed after surgery. The plaster cast was split temporarily to allow for postoperative swelling which can be uncomfortable.

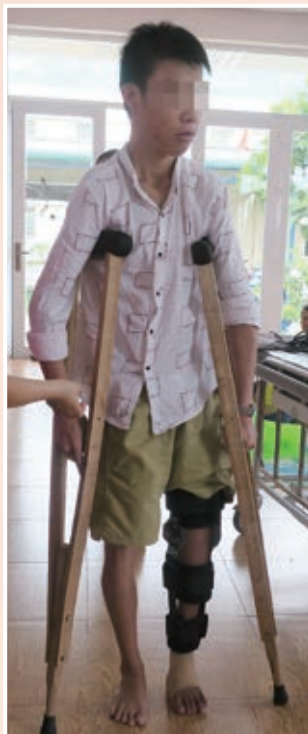

M 019



兩個月後，石膏拆了，患者配上長支具，做物理治療，學習走路。

Two months later, the plaster cast was removed. Patient was fitted with a long leg brace and started physiotherapy. He relearned walking.



一段時間後，患者改用膝部支具，用拐杖走路。左腳已經矯正，可以平放地上負重。

Later, patient changed to use a knee brace and walked with crutches. The left foot was corrected and was able to bear weight flat on the floor.

再過一段時間，患者可以不用支具，只用拐杖走路。

Later, patient was able to walk with crutches without brace.



M 019

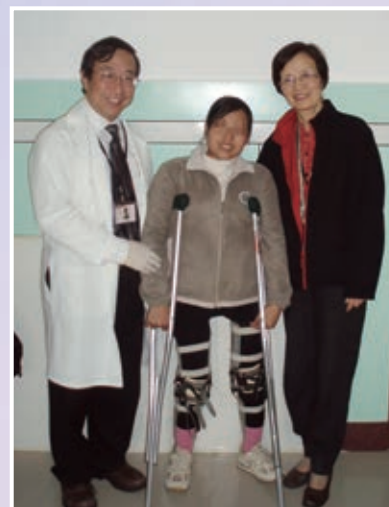


兒麻後遺症、兩側髖關節及膝關節攣縮

Post-poliomyelitis Deformities Bilateral Hip and Knee Contractures

21 歲河南女子，幼年患小兒麻痺症，令下肢部份癱瘓，軟弱無力，雙側髖關節及雙側膝關節攣縮，不能站立，不能走路，只能蹲著，用手固定及移動雙足向前。

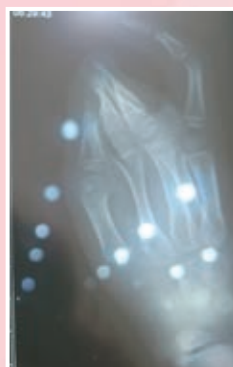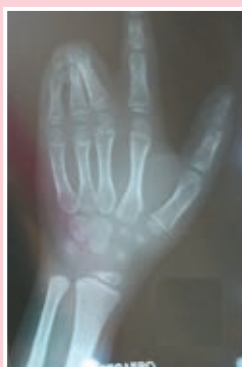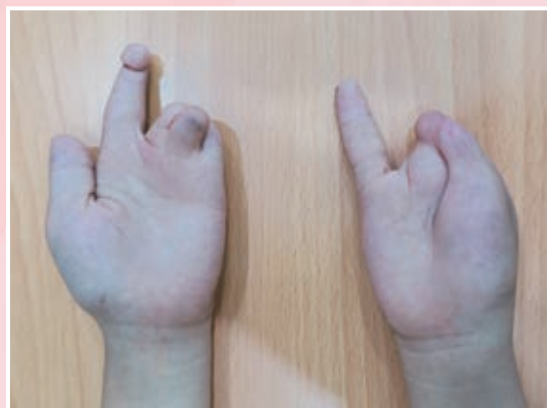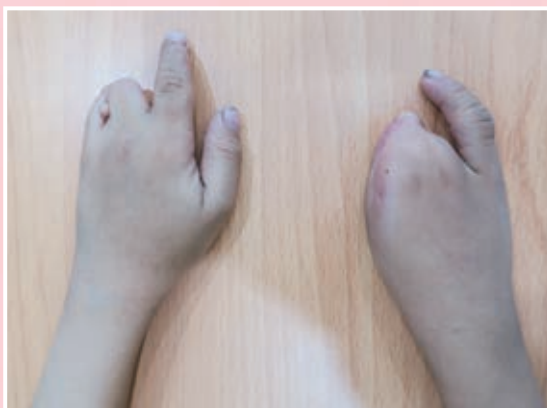A 21-year-old lady from Henan. She had poliomyelitis in early childhood leading to partial paralysis of both lower limbs. She had severe flexion contracture of both hips and both knees. She was unable to stand or walk. To move forward, she squatted down and used her hands to stabilize and move the feet forward.



病人接受了鬆解及截骨手術，把髖關節及膝關節矯正了，配上長支具，就可以站立，又可以用拐杖走路。

Patient had soft tissues releases and osteotomy surgeries for correction of flexion contracture of both hips and knees. She was fitted with bilateral long leg calipers. After fitting of bilateral long leg calipers, she can stand and walk with a pair of crutches.

M 020

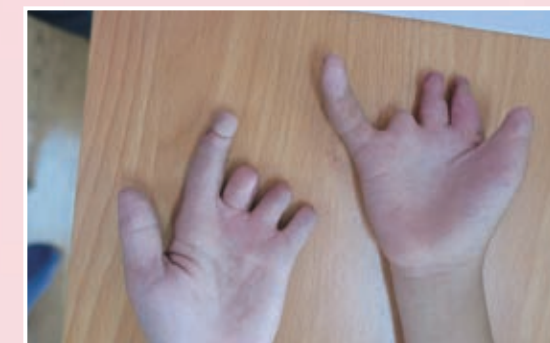
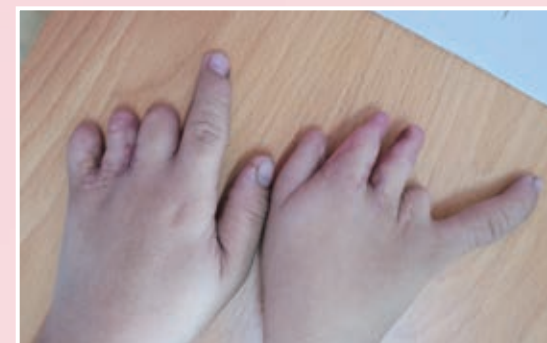
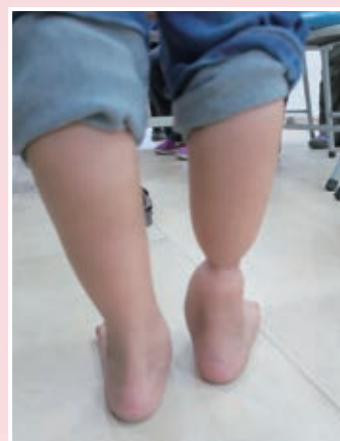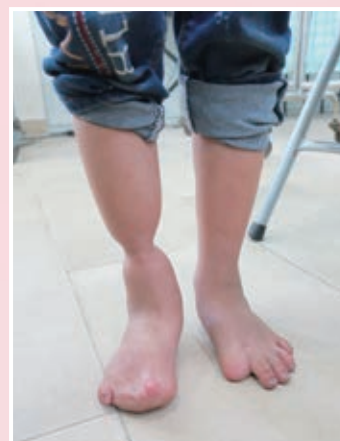先天性狹窄帶徵候簇

Congenital Constriction Band Syndrome

一位 10 歲的越南男童，患有先天性狹窄帶徵候簇，出生前部分手指和腳趾已經截肢，而且多隻手指及腳趾有併指畸形，X 光顯示手指骨頭連在一起。此外，右側小腿有一狹窄帶，將會影響右腳的發育及血液循環。

A 10-year-old Vietnamese boy. He was born with congenital constriction band syndrome. Many fingers and toes were lost by autoamputation before birth. He had syndactyly of fingers and toes. X-ray examination showed that several finger bones were fused together. Also, a constriction band over the right leg was very tight causing concerns about future growth and circulation of the right foot.

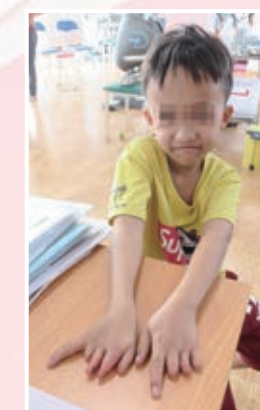
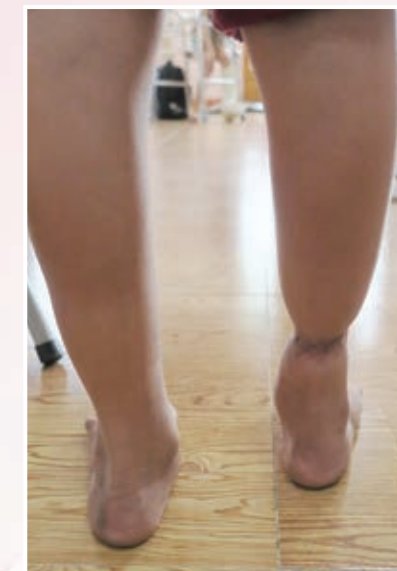
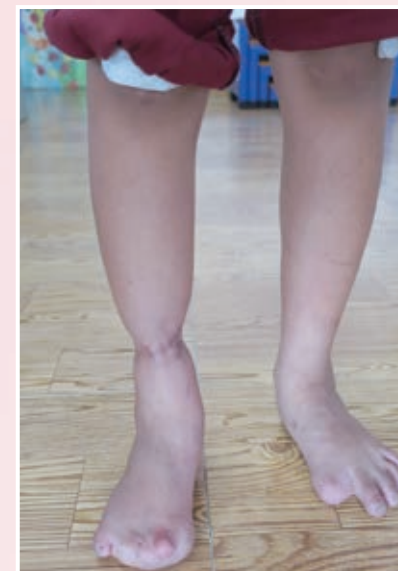天鄰手外科醫生為病人治療，男孩連續三年接受了多項手術，把雙手連在一起的手指釋放及重組，最後每隻手均有分開及可活動的五隻指頭。手部功能大大提高，外觀亦有明顯改善。

Patient received multiple surgeries three years in a row. Both hands were released and reconstructed. Eventually each hand has five separate and moveable digits. The appearance and function of both hands are much improved.

右側小腿的狹窄帶經過兩次鬆解手術後已經改善，避免了日後對發育和血液循環的不良影響。

After two surgical releases of the constriction bands of the right leg, the condition is improved. This avoids future harmful influence on growth and circulation.




M 021

右側膝上截肢、右側大姆指截肢
左側小指截肢
左側前臂開放性骨折
左側手腕硬化

Right Above Knee Amputation
Amputation of Right Thumb
Amputation of Left Little Finger
Open Fracture Left Forearms
Ankylosis of Left Wrist.

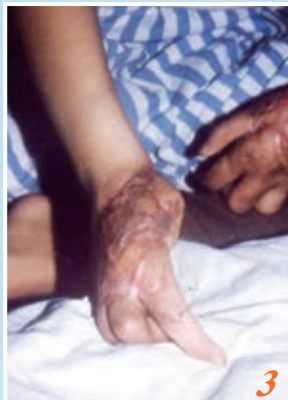(1) 一位 19 歲河南少女，因為火車意外，令三肢殘廢。曾住院 88 天，卻因未能支付醫藥費，醫院停止治療。病人曾多次試圖絕食自殺。

(1) A 19-year-old lady from Henan was a victim of train accident. Three of her limbs were badly maimed. She was hospitalized for 88 days. However, treatment was stopped because the family was unable to pay. She attempted suicide by fasting several times.



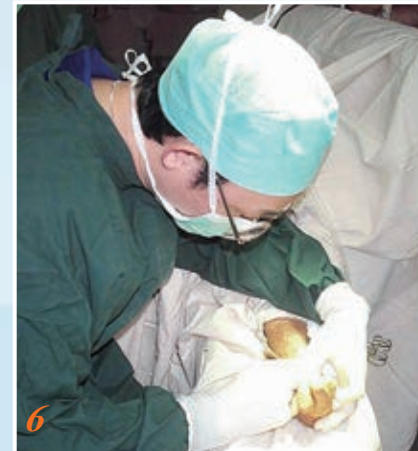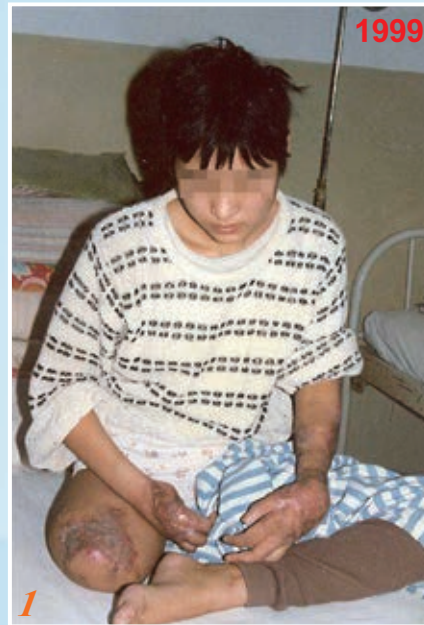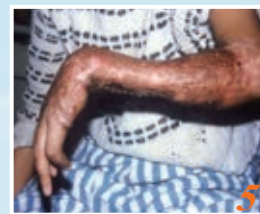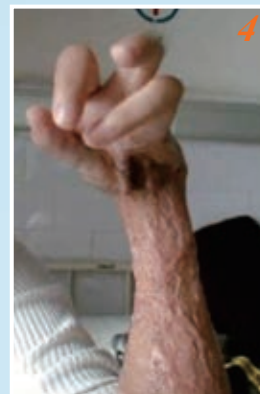
(2,3) 右大姆指截肢，中指及環指關節硬化。手背疤痕嚴重。

(2,3) Right Thumb was amputated. The right middle and ring fingers were ankylosed. Bad scars over dorsum of right hand.



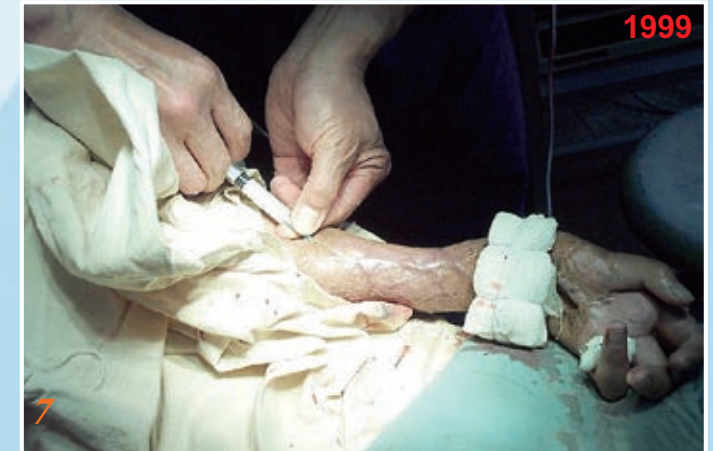
(4,5) 左手失去小指，因為左前臂開放性骨折曾受感染，令左手腕關節硬化，不能活動。前臂及手部疤痕嚴重。

(4,5) Left little finger was amputated. Due to infection of open forearm fracture, the left wrist became ankylosed. Bad scars over the forearm and hand.



(6,7) 天鄰手外科醫生為病人做手術，矯正左側手腕，整形外科醫生注射藥物，以軟化疤痕。

(6,7) Hand surgeon operated to correct the left wrist. Plastic surgeon injected medicine to soften the scars.



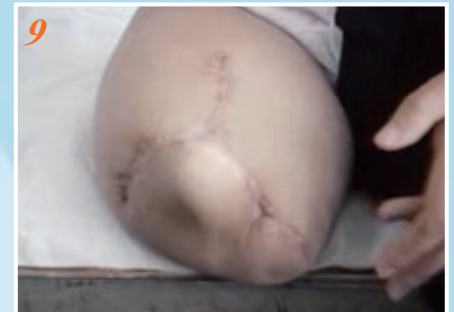(8) 左手腕配上支具以保持術後位置。

(8) A wrist brace was fitted to maintain the alignment of the left wrist.



(9) 右腿殘肢修改了，以便配上義肢。

(9) The right thigh amputation stump was revised in preparation for fitting of prosthesis.

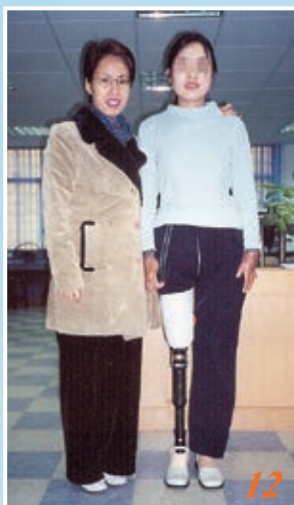

(10,11) 殘肢傷口癒合後配上臨時義肢，病人便可以開始走路。

(10,11) A temporary prosthesis was fitted after the amputation stump was healed. Patient was then able to walk.



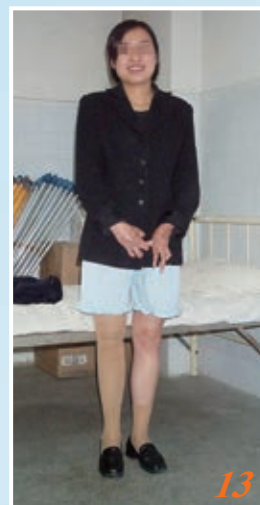M 022



2000-2003

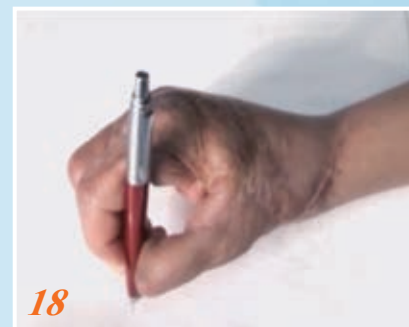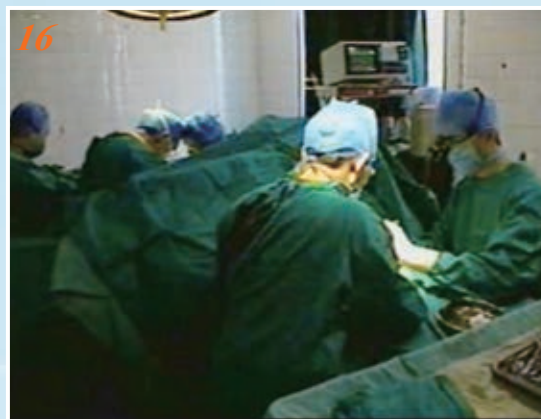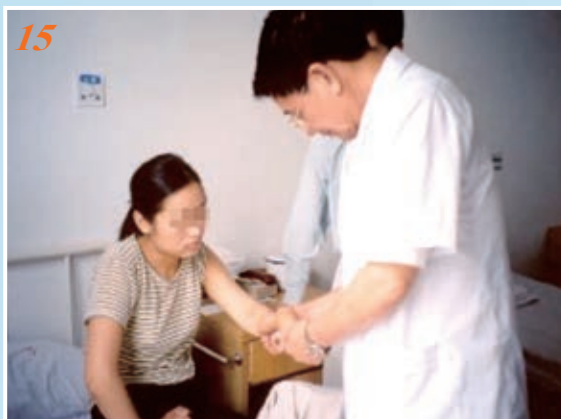(12-14) 病人由天鄰護士陪同下，到武漢一間義肢中心，裝配永久義肢。義肢配上後走路步姿及外觀均良好。

(12-14) Patient was escorted by a nurse from HIS Foundation to a prosthetic center in Wuhan. After fitting of permanent prosthesis, the gait and the appearance of the limb are very good.



(15,16) 天鄰安排病人到無錫手科專科醫院接受右手手指轉移手術。同時，天鄰安排香港中文大學骨科部教授，到無錫醫院做左側手腕重組手術。兩台手術同步進行，費用由天鄰基金會承擔。

(15,16) HIS Foundation arranged patient to have finger to thumb transplant surgery at a hand center in Wuxi. At the same time, HIS Foundation arranged an orthopaedic professor from the Chinese University in Hong Kong to perform reconstructive surgery on the left wrist simultaneously. All treatment were paid by HIS Foundation.



2003

(17,18) 右手環指被轉移作為大姆指，活動及功能良好。

(17,18) The right ring finger was transplanted to become the new thumb. It has good movement and function.

(19) 屈曲的左側手腕被矯正了。

(19) The flexion deformity of the left wrist was corrected.

患者醫治的經歷，讓她相信耶穌基督，她曾在聖經學院修讀，並協助農村的傳道人，事奉教會。她於 2003 年結婚，丈夫是農村醫生。

Patient became a Christian after experiencing various healing. She studied in a bible college and became an assistant to a pastor, serving the local church. She was married in 2003. Her husband is a village doctor.

(20,21) 2012 年家訪，病人已育有兩名子女，她協助丈夫診所的工作。

(20,21) Home visit in 2012. Patient is a mother of two. She serves as her husband's assistant in the clinic.



2018



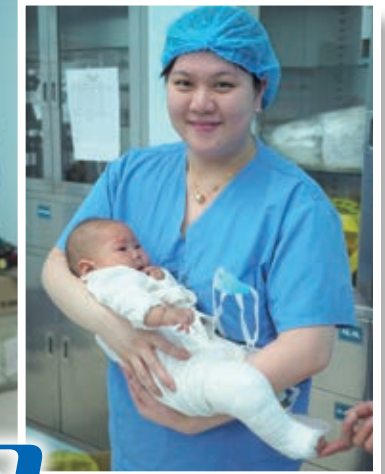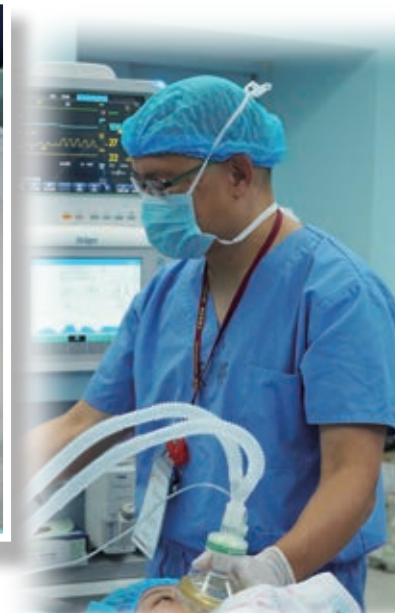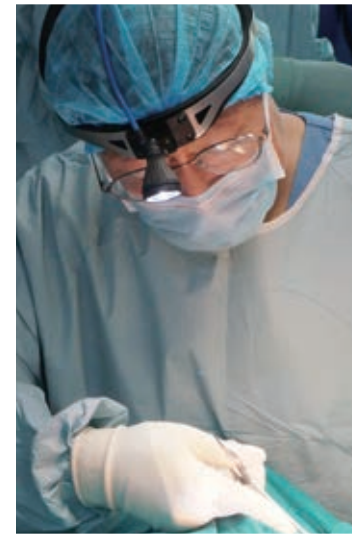
(22,23) 天鄰醫療隊於 2018 年再次探訪病人。她右手大拇指的功能非常好，走路的姿勢亦良好。醫療隊員與病人及家屬一起拍照。

(22,23) Members of surgery team paid another home visit in 2018. Patient's right thumb functions very well and her gait is good. Team members had pictures with patient and her family.

病人說：「回想過去的一切治療，其實我是不配，都是神的恩典。天鄰基金會就好像東方的一顆大救星，他們是神派來的使者，將我們一班殘障的病人，從黑暗中引去光明。主呀！我很感謝祢，我願意一生一世都跟隨祢。我雖然沒有靈巧的手，亦沒有動聽的歌喉，但是我依然要唱，耶和華的大愛，去傳揚主的福音。」

Patient says: "On thinking back all the treatments I received, I did not deserve them. They were all God's grace. HIS Foundation is like a big salvation star in the East. Their volunteers are ambassadors sent by God. They lead the handicapped people like me, from darkness to brightness. Dear Lord! I really thank and appreciate you. I would like to follow you for the rest of my life. Although I do not have a pair of skillful hands and I do not have a pleasant voice. I still would like to sing about the Lord's great love. I will go and proclaim the Gospel."

M 022



骨科手術數目

Data of Orthopaedic Surgeries



歷年骨科隊出隊記錄

Record of Orthopaedic Missions

香港天鄰基金會於 1992 年在香港註冊為非謀利組織，英文名稱 HIS Foundation Ltd.。美國天鄰基金會於 1998 年在美國獨立註冊為非謀利團體，正式名稱為 Holistic Integrated Services Foundation（又簡稱 HIS Foundation）。澳洲天鄰基金會隸屬美國天鄰基金會，於 2018 在澳洲註冊為非謀利組織，正式名稱為 Holistic Integrated Services (HIS) Foundation Australia Incorporated.

三個組織的宗旨都是一樣，是藉醫療、教育、救災及扶貧，來彰顯耶穌基督的大愛和福音的大能。歷年來，很多服務隊都有香港、美國和澳洲的隊員共同參與。

以下是歷年的骨科隊出隊記錄，其中早年的紀錄並不完整，如有錯漏，請原諒並敬請提出，以便修正。

HIS Foundation Ltd. was registered as a nonprofit organization in Hong Kong in 1992. Holistic Integrated Services Foundation, also known as (DBA) HIS Foundation was independently registered as a nonprofit organization in the United States in 1998. Holistic Integrated Services (HIS) Foundation Australia Incorporated is under HIS Foundation in the United States and was registered as a nonprofit organization in Australia in 2018.

All three organizations have the same mission which is to witness the love of Christ and the power of the Gospel through medical and health care, education services, relief of natural disasters, and helping the poor. Throughout the years, volunteers from Hong Kong, the United States, and Australia served side by side in many teams.

The following is the record of orthopaedic missions. The reports of earlier years are incomplete. Please pardon us for any mistakes and inform us so that we can update the record.

年份 Year	日期 Date	人數 member	地點 Location	合作醫院 Partner hospital	門診 Clinic	手術人數 Surgery patient	肢具及義肢 Brace & Prosthesis
1995	Nov 24	14	河南省 Henan	許昌市中醫院 Xuchang Chinese Hospital		21	40
1996	Nov 1 - 10	30	河南省 Henan	許昌市中醫院 Xuchang Chinese Hospital		42	
	Dec 26 - 29	7	河南省 Henan	許昌市中醫院 Xuchang Chinese Hospital	40		
1997	Oct 26 - Nov 9		河南省 Henan	許昌市中醫院 Xuchang Chinese Hospital		20	
1998	Apr 24 - May 3	11	河南省 Henan	許昌市中醫院 Xuchang Chinese Hospital			
	Oct 21 - 31	29	河南省 Henan	洛陽市第一人民醫院 Luoyang No.1 Remin Hospital	100	48	11
1999	Mar 14 - 24	22	河南省 Henan	洛陽市第一人民醫院 Luoyang No.1 Remin Hospital	120	20	
	Oct 20 - 31	27	河南省 Henan	洛陽市第一人民醫院 Luoyang No.1 Remin Hospital	110	23	
2000	Mar 26 - Apr 5	25	河南省 Henan	安陽市二人民醫院 Anyang No.2 Remin Hospital	400	21	
	May 26 - 28	7	河南省 Henan	安陽市二人民醫院 Anyang No.2 Remin Hospital	21		
	Oct 22 - Nov 1	27	河南省 Henan	洛陽市第一人民醫院 Luoyang No.1 Remin Hospital	96	31	42
2001	28 Mar - 8 Apr	29	河南省 Henan	安陽市二人民醫院 Anyang No.2 Remin Hospital		30	
	Jun 1 - 3	8	河南省 Henan	安陽市二人民醫院 Anyang No.2 Remin Hospital	35		91
	Oct 24 - Nov 4		河南省 Henan	洛陽市第一人民醫院 Luoyang No.1 Remin Hospital	120	29	30
2002	May 13 - 24	29	河南省 Henan	洛陽市第一人民醫院 Luoyang No.1 Remin Hospital	114	33	60
	May 19 - 21		河南省 Henan	洛陽市第一人民醫院 Luoyang No.1 Remin Hospital	33		50
	Oct 16 - 27	29	河南省 Henan	安陽市二人民醫院 Anyang No.2 Remin Hospital		30	
	Dec 13 - 15		河南省 Henan	安陽市二人民醫院 Anyang No.2 Remin Hospital	30		45
2003	Mar 23 - Apr 4	29	河南省 Henan	洛陽市第一田人民醫院 Luoyang No.1 Remin Hospital	108	35	70
	June	1	河南省 Henan	洛陽市第一人民醫院 Luoyang No.1 Remin Hospital	35		
2004	Mar 7 - 19	32	河南省 Henan	洛陽市第一人民醫院 Luoyang No.1 Remin Hospital	154	41	70
	May 21 - 23	6	河南省 Henan	洛陽市第一人民醫院 Luoyang No.1 Remin Hospital	46		77
	Jun 27 - Jul 9	29	河南省 Henan	安陽市二人民醫院 Anyang No.2 Remin Hospital	129	28	57

2004	Aug 18 - 22	4	河南省 Henan	安陽市二人民醫院 Anyang No.2 Remin Hospital	135		84
	Oct 19 - 29	12	河南省 Henan	駐馬店市中醫院 Zhumadian Chinese Hospital	68	12	37
	Dec 25 - 27	3	河南省 Henan	駐馬店市中醫院 Zhumadian Chinese Hospital	14		24
2005	Mar 6 - 12	20	河南省 Henan	駐馬店市中醫院 / 宜陽縣愛德醫院 Zhumadian Chinese Hospital/ Aide Hospital	232	26	97
	May 14-16	4	河南省 Henan	駐馬店市中醫院 Zhumadian Chinese Hospital	26		38
	Aug 14 - 24	19	河南省 Henan	安陽市二人民醫院 Anyang No.2 Remin Hospital	115	53	101
	Oct 9 - 11	7	河南省 Henan	安陽市二人民醫院 Anyang No.2 Remin Hospital	137		
	Oct 23 - Nov 2	21	河南省 Henan	沁陽市紅十字會醫院 Qinyang Red Cross Hospital	50	24	51
	Dec 25 - 27	3	河南省 Henan	沁陽市紅十字會醫院 Qinyang Red Cross Hospital	24		
2006	Mar 26 - Apr 5	20	河南省 Henan	沁陽市紅十字會醫院 Qinyang Red Cross Hospital	126	26	72
	May 19 - 21	3	河南省 Henan	沁陽市紅十字會醫院 Qinyang Red Cross Hospital	25		67
	May 21 - 28	19	河南省 Henan	安陽市二人民醫院 Anyang No.2 Remin Hospital	213	54	41
	July 14 - 16	8	河南省 Henan	安陽市二人民醫院 Anyang No.2 Remin Hospital	229		97
	Oct 8 - 12	10	河南省 Henan	安陽市二人民醫院 Anyang No.2 Remin Hospital	105	7	59
	Oct 22 - Nov 1	21	河南省 Henan	駐馬店市中醫院 Zhumadian Chinese Hospital	116	31	35
	Dec 2 - 3	3	河南省 Henan	安陽市二人民醫院 Anyang No.2 Remin Hospital	9		41
	Dec 24 - 26	4	河南省 Henan	駐馬店市中醫院 Zhumadian Chinese Hospital	31		
2007	Jan 5 - 7	1	河南省 Henan	安陽市二人民醫院 Anyang No.2 Remin Hospital	10		17
	Mar 25 - Apr 4	22	河南省 Henan	沁陽市紅十字會醫院 Qinyang Red Cross Hospital	181	33	89
	May 13 - 20	14	河南省 Henan	安陽市二人民醫院 Anyang No.2 Remin Hospital	29	16	
	May 25 - 27	4	河南省 Henan	沁陽市紅十字會醫院 Qinyang Red Cross Hospital	34		
	May 27 - Jun 3	34	河南省 Henan	安陽市二人民醫院 Anyang No.2 Remin Hospital		31	63
	July 28 - 30	12	河南省 Henan	安陽市二人民醫院 Anyang No.2 Remin Hospital	147		30
	Oct 14 - 24	20	河南省 Henan	駐馬店市中醫院 Zhumadian Chinese Hospital	107	33	61

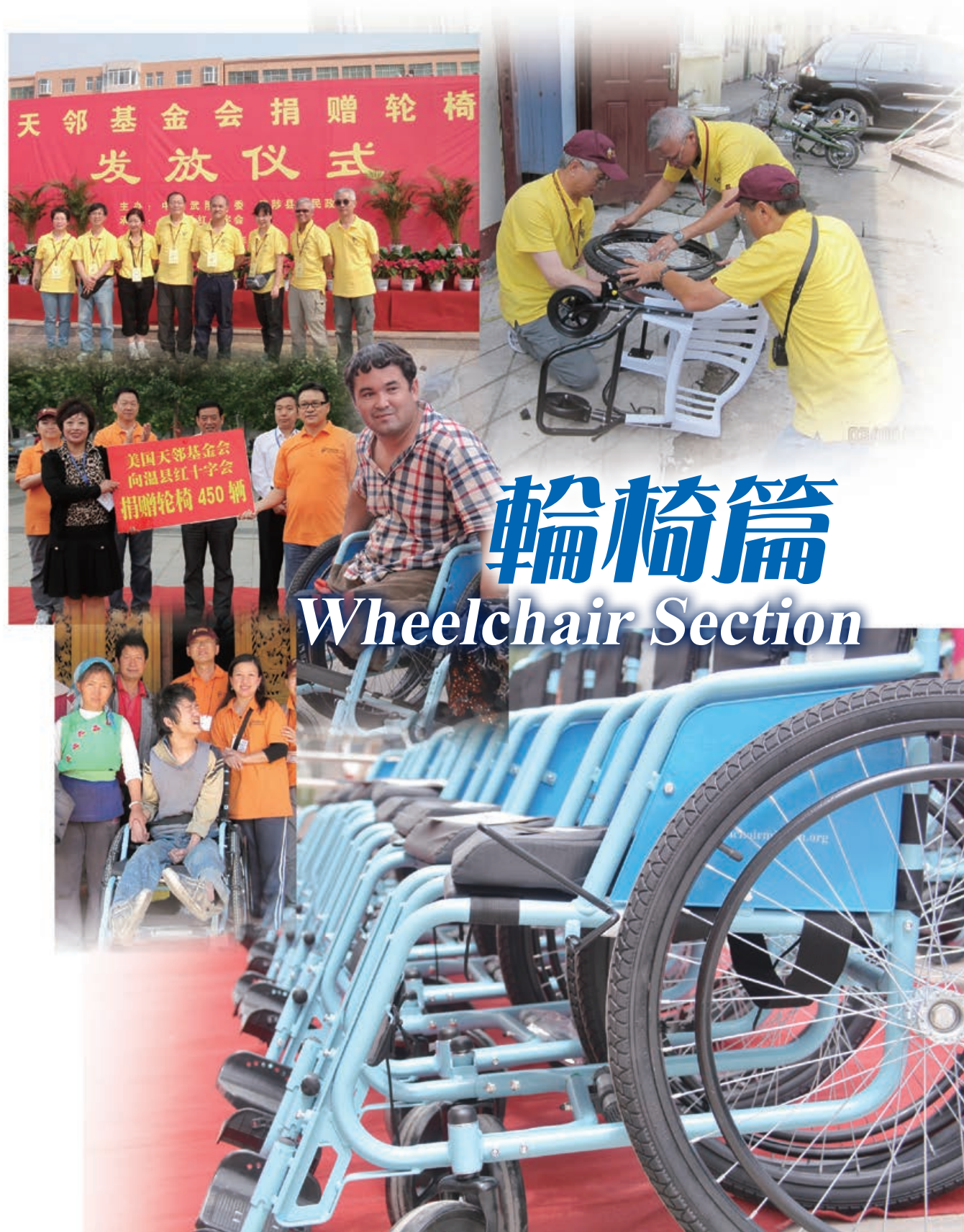2007	Dec 14 - 16	4	河南省 Henan	駐馬店市中醫院 Zhumadian Chinese Hospital	40		
2008	Jan 19 - 26	13	河南省 Henan	安陽市二人民醫院 Anyang No.2 Remin Hospital		21	
	Mar 21 - 24	7	河南省 Henan	安陽市二人民醫院 Anyang No.2 Remin Hospital	100		37
	Mar 30 - Apr 6	16	河南省 Henan	安陽市二人民醫院 Anyang No.2 Remin Hospital	47	21	
	May 18 - 29	20	河南省 Henan	沁陽市紅十字會醫院 Qinyang Red Cross Hospital	179	35	
	May 29 - 30	5	雲南省 Yunnan	永平縣人民醫院 Yongping County Remin Hospital	60		
	May 31 - Jun 1	6	河南省 Henan	安陽市二人民醫院 Anyang No.2 Remin Hospital	21		79
	July 19 - 20	4	河南省 Henan	沁陽市紅十字會醫院 Qinyang Red Cross Hospital	38		
	Sept 21 - 28	26	河南省 Henan	安陽市二人民醫院 Anyang No.2 Remin Hospital	45	28	118
	Oct 12 - 23	27	河南省 Henan	駐馬店市中醫院 Zhumadian Chinese Hospital	156	22	76
	Oct 25 - Nov 2	22	雲南省 Yunnan	永平縣人民醫院 Yongping County Remin Hospital	41	17	28
2009	Nov 8 - 9	13	河南省 Henan	安陽市二人民醫院 Anyang No.2 Remin Hospital	108		51
	Dec 12 - 14	8	河南省 Henan	駐馬店市中醫院 Zhumadian Chinese Hospital	24		
	27-Dec	6	雲南省 Yunnan	永平縣人民醫院 Yongping County Remin Hospital	38		
	Mar 1 - 7	12	河南省 Henan	安陽市二人民醫院 Anyang No.2 Remin Hospital		12	18
	Mar 15 - 26	19	河南省 Henan	沁陽市紅十字會醫院 Qinyang Red Cross Hospital	140	45	83
	Apr 26 - May 3	16	河南省 Henan	安陽市二人民醫院 Anyang No.2 Remin Hospital	47	15	19
	May 1 - 3	9	河南省 Henan	安陽市二人民醫院 Anyang No.2 Remin Hospital	36		16
	May 15 - 17	4	河南省 Henan	沁陽市紅十字會醫院 Qinyang Red Cross Hospital	41		83
	Jun 6 - 7	5	河南省 Henan	安陽市二人民醫院 Anyang No.2 Remin Hospital	24		9
	Sept 20 - 26	24	河南省 Henan	安陽市二人民醫院 Anyang No.2 Remin Hospital	76	21	62
	Oct 10 - 23	25	雲南省 Yunnan	永平縣人民醫院 Yongping County Remin Hospital	88	22	22
	Oct 5 - Nov 5	20	河南省 Henan	駐馬店市中醫院 Zhumadian Chinese Hospital	104	39	80
	Nov 7 - 8	10	河南省 Henan	安陽市二人民醫院 Anyang No.2 Remin Hospital	137		73
	Dec 19 - 20	5	河南省 Henan	駐馬店市中醫院 Zhumadian Chinese Hospital	43		5

2010	Jan 14 - 16	5	雲南省 Yunnan	永平縣人民醫院 Yongping County Remin Hospital	51		1
	Mar 21 - Apr 1	21	河南省 Henan	沁陽市紅十字會醫院 Qinyang Red Cross Hospital	156	38	111
	Apr 11 - 17	20	河南省 Henan	安陽市二人民醫院 Anyang No.2 Remin Hospital		23	17
	Apr 18 - 25	16	河南省 Henan	安陽市二人民醫院 Anyang No.2 Remin Hospital	44	27	
	May 22 - 30	38	雲南省 Yunnan	永平縣人民醫院 Yongping County Remin Hospital	95	16	12
	May 29 - 30	6	河南省 Henan	沁陽市紅十字會醫院 Qinyang Red Cross Hospital	32		
	Jun 5 - 6	5	河南省 Henan	安陽市二人民醫院 Anyang No.2 Remin Hospital	23		
	Jun 12 - 13	7	河南省 Henan	安陽市二人民醫院 Anyang No.2 Remin Hospital	67		23
	Aug 5 - 9	9	雲南省 Yunnan	永平縣人民醫院 Yongping County Remin Hospital	90		1
	Aug 10 - 11	5	雲南省 Yunnan	大理市第二人民醫院 Dali No. 2 Remin Hospital	102		5
	Sept 12 - 18	24	河南省 Henan	安陽市二人民醫院 Anyang No.2 Remin Hospital		21	65
	Oct 30 - 31	9	河南省 Henan	安陽市二人民醫院 Anyang No.2 Remin Hospital	78		18
2011	Apr 2 - 8	20	雲南省 Yunnan	永平縣人民醫院 Yongping County Remin Hospital	75	13	13
	Apr 9 - 16	32	雲南省 Yunnan	大理市第二人民醫院 Dali No. 2 Remin Hospital	22	13	21
	Apr 10 - 16	22	河南省 Henan	安陽市二人民醫院 Anyang No.2 Remin Hospital		22	59
	May 15 - 26	30	河南省 Henan	沁陽市紅十字會醫院 Qinyang Red Cross Hospital	148	35	124
	Jun 19 - 22	9	雲南省 Yunnan	大理第二人民醫院 Dali No. 2 Remin Hospital / 永平縣人民醫院 Yongping County Remin Hospital	29		
	July 15 - 17	5	河南省 Henan	沁陽市紅十字會醫院 Qinyang Red Cross Hospital	32		
	Sept 12 - 18	19	河南省 Henan	安陽市二人民醫院 Anyang No.2 Remin Hospital		12	17
	Oct 9 - 16	17	河南省 Henan	安陽市二人民醫院 Anyang No.2 Remin Hospital	34	17	9
	Dec 11 - 19	10	河南省 Henan	安陽市二人民醫院 Anyang No.2 Remin Hospital	125		54
	Dec 11 - 19	4	河南省 Henan	安陽市二人民醫院 Anyang No.2 Remin Hospital	20		
2012	Mar 10 - 21	35	雲南省 Yunnan	大理市第二人民醫院 Dali No. 2 Remin Hospital	220	33	38
	Apr 15 - 21	24	河南省 Henan	安陽市二人民醫院 Anyang No.2 Remin Hospital	57	29	74

2012	May 13 - 20	19	河南省 Henan	安陽市二人民醫院 Anyang No.2 Remin Hospital	65	24	19
	Sept 2 - 13	30	河南省 Henan	沁陽市紅十字會醫院 Qinyang Red Cross Hospital	168	40	72
	Sept 16 - 22	20	河南省 Henan	安陽市二人民醫院 Anyang No.2 Remin Hospital	90	11	42
	Nov 3 - 5	6	河南省 Henan	沁陽市紅十字會醫院 Qinyang Red Cross Hospital	40		
2013	Apr 14 - 21	13	河南省 Henan	安陽市二人民醫院 Anyang No.2 Remin Hospital	49	22	5
	Apr 21 - 27	18	河南省 Henan	安陽市二人民醫院 Anyang No.2 Remin Hospital		16	29
	May 19 - Jun 1	44	雲南省 Yunnan	大理市第二人民醫院 Dali No. 2 Remin Hospital	104	44	67
	Aug 2 - 4	4	雲南省 Yunnan	大理市第二人民醫院 Dali No. 2 Remin Hospital	42		
	Sept 1 - 12	34	河南省 Henan	沁陽市紅十字會醫院 Qinyang Red Cross Hospital	110	51	98
	Sept 22 - 28	20	河南省 Henan	安陽市二人民醫院 Anyang No.2 Remin Hospital		20	21
2014	Nov 1 - 3	6	河南省 Henan	沁陽市紅十字會醫院 Qinyang Red Cross Hospital	54		
	Feb 18 - 28	12	馬達加斯加 Madagascar	陸軍醫院 Soavinandriana Hospital Centre	38	14	
	Mar 16 - 28	40	雲南省 Yunnan	大理市第二人民醫院 Dali No. 2 Remin Hospital	119	45	57
	Mar 30 - Apr 5	17	河南省 Henan	安陽市二人民醫院 Anyang No.2 Remin Hospital		19	25
	May 18 - 25	13	雲南省 Yunnan	大理市第二人民醫院 Dali No. 2 Remin Hospital		9	
	Sept 14 - 20	20	河南省 Henan	安陽市二人民醫院 Anyang No.2 Remin Hospital		35	70
	Oct 9 - 23	40	河南省 Henan	沁陽市紅十字會醫院 Qinyang Red Cross Hospital	193	38	61
2015	Dec 27 - 29	5	河南省 Henan	沁陽市紅十字會醫院 Qinyang Red Cross Hospital	40		
	Mar 15 - 28	34	雲南省 Yunnan	大理市第二人民醫院 Dali No. 2 Remin Hospital	156	49	73
	Apr 12 - 18	14	河南省 Henan	安陽市二人民醫院 Anyang No.2 Remin Hospital		14	15
	Apr 19 - 26	15	雲南省 Yunnan	大理市第二人民醫院 Dali No. 2 Remin Hospital	37	15	3
	Sept 6 - 12	20	河南省 Henan	安陽市二人民醫院 Anyang No.2 Remin Hospital		11	12
	Sept 13 - 24	39	河南省 Henan	沁陽市紅十字會醫院 Qinyang Red Cross Hospital	181	45	51
	Nov 3 - 16	8	馬達加斯加 Madagascar	陸軍醫院 Soavinandriana Hospital Centre		16	
	Nov 29 - Dec 5	16	河南省 Henan	沁陽市紅十字會醫院 Qinyang Red Cross Hospital	47	11	24

2016	Mar 13 - 26	29	雲南省 Yunnan	大理市第二人民醫院 Dali No. 2 Remin Hospital	163	39	68
	Mar 3 - 19	25	河南省 Henan	安陽市第二人民醫院及 滑縣新區醫院 / Anyang No.2 Remin Hospital & Hua New Area Hospital	88	22	39
	May 15 - 22	12	雲南省 Yunnan	大理市第二人民醫院 Dali No. 2 Remin Hospital	55	13	
	Sept 4 - 10	20	河南省 Henan	滑縣新區醫院 / Hua County Hospital	81	7	14
	Sept 13 - 26	12	馬達加斯加 Madagascar	陸軍醫院 Soavinandriana Hospital Centre	31	23	
	Sept 18 - 29	33	河南省 Henan	沁陽市紅十字會醫院 Qinyang Red Cross Hospital	125	32	38
	Sept 20 -23	4	越南胡志明市	胡志明市韓國醫院 / Long An Segaero Hospital	25		
	Nov 27 - Dec 3	16	河南省 Henan	沁陽市紅十字會醫院 Qinyang Red Cross Hospital	13	19	13
2017	Mar 3 - 12	14	雲南省 Yunnan	大理市第二人民醫院 Dali No. 2 Remin Hospital	24	5	
	Mar 25 - 31	10	越南胡志明市	胡志明市韓國醫院 / Long An Segaero Hospital	37	9	11
	Mar 26 - Apr 1	16	河南省 Henan	滑縣新區醫院 / Hua New Area Hospital	18	10	9
	May 16 - 29	9	馬達加斯加 Madagascar	陸軍醫院 Soavinandriana Hospital Centre		16	
	Jun 11 - 17	7	青海省 Qinghai	青海福利慈善醫院 Qinghai Charity Hospital	10	5	8
	Aug 13 - 24	26	河南省 Henan	沁陽市紅十字會醫院 Qinyang Red Cross Hospital	101	31	34
	Aug 23 - 25	3	青海省 Qinghai	青海福利慈善醫院 Qinghai Charity Hospital	8		
	Sept 3 - 9	11	河南省 Henan	滑縣新區醫院 / Hua New Area Hospital		8	13
	Sept 17 - 29	23	雲南省 Yunnan	大理市第二人民醫院 Dali No. 2 Remin Hospital	135	23	55
	Oct 15 - 22	13	河南省 Henan	沁陽市紅十字會醫院 Qinyang Red Cross Hospital	19	11	7
	Nov 11 - 19	5	雲南省 Yunnan	大理市第二人民醫院 Dali No. 2 Remin Hospital	23	1	
	Dec 15 - 17	4	河南省 Henan	沁陽市紅十字會醫院 Qinyang Red Cross Hospital	20		
2018	Jan 28 - Feb 3	14	越南 Vietnam	胡志明市韓國醫院 / Long An Segaero Hospital	19	7	6
	Mar 18 - 24	12	青海省 Qinghai	青海福利慈善醫院 Qinghai Charity Hospital	9	5	
	Mar 26 - Apr 1	12	河南省 Henan	滑縣新區醫院 / Hua New Area Hospital	3	11	12
	Apr 6 - 8	8	越南 Vietnam	胡志明市韓國醫院 / Long An Segaero Hospital	14		

2018	Apr 10 - 13	1	庫爾德斯坦 Kurdistan	扎胡急症醫院 Emergency Hospital in Zakho	7		
	Apr 15 - 28	27	河南省 Henan	沁陽中醫院東院 / Qinyang Chinese Hospital	106	35	69
	May 8 - 21	9	馬達加斯加 Madagascar	陸軍醫院 Soavinandriana Hospital Centre		16	
	Jun 10 - 17	12	河南省 Henan	沁陽中醫院東院 / Qinyang Chinese Hospital	36	5	
	Sept 9 - 15	15	河南省 Henan	滑縣新區醫院 / Hua County Hospital		10	14
	Sept 9 - 21	22	雲南省 Yunnan	大理市第二人民醫院 Dali No. 2 Remin Hospital	134	26	58
	Nov 17 - 19	6	雲南省 Yunnan	大理市第二人民醫院 Dali No. 2 Remin Hospital	26		
2019	Jan 6 - 12	14	越南 Vietnam	胡志明市韓國醫院 / Long An Segaero Hospital	90	12	6
	Jan 13 - 25	22	庫爾德斯坦 Kurdistan	扎胡急症醫院 Emergency Hospital in Zakho	237	24	19
	Mar 5 - 18	14	馬達加斯加 Madagascar	陸軍醫院 Soavinandriana Hospital Centre		14	
	Mar 22 - 23	4	越南 Vietnam	胡志明市韓國醫院 / Long An Segaero Hospital	11		
	Mar 24 - Apr 4	27	河南省 Henan	沁陽中醫院東院 / Qinyang Chinese Hospital	98	39	66
	Apr 5 - 10	5	庫爾德斯坦 Kurdistan	扎胡急症醫院 Emergency Hospital in Zakho	37		
	Apr 7 - 13	11	河南省 Henan	滑縣新區醫院 / Hua New Area Hospital	42	12	13
	May 24 - 26	5	河南省 Henan	沁陽中醫院東院 / Qinyang Chinese Hospital	35		
	May 5 - 27	4	河南省 Henan	滑縣新區醫院 / Hua New Area Hospital	62		12
	Jun 9 - 15	14	Sichuan 四川省	瀘州市福音醫院 / Luzhou Gospel Hospital	8	6	2
	Sept 3 -16	9	馬達加斯加 Madagascar	大學醫院 Soavinandriana Hospital Centre	29	15	
	Oct 6 - 18	21	庫爾德斯坦 Kurdistan	扎胡急症醫院 Emergency Hospital in Zakho	108	21	27
	Dec 8 - 11	7	庫爾德斯坦 Kurdistan	扎胡急症醫院 Emergency Hospital in Zakho	32		
Total		2491			10639	2476	4625



天鄰輪椅事工之源起

HIS Foundation Wheelchair Ministry: How the Dream was Formed and Came True

劉漢杰 小兒骨科醫生
天鄰基金會主席

James Lau Pediatric Orthopaedic Surgeon
Chairman, HIS Foundation

作為骨科醫生，我經常思考的問題之一就是病人的活動能力（mobility）。好的活動能力讓人可以盡情享受生活的樂趣，例如可以上學、上班、參加社交活動、去旅行等等。試想一個人若失去活動能力，

As an orthopaedic surgeon, I frequently think about mobility of patients. Someone with good mobility is more able to enjoy life fully. This includes attending school, going to work, joining social gatherings, and traveling etc. On the other hand, imagine someone



很多不良於行的患者，因為沒有能力負擔輪椅，需要在地上爬行。

Many handicapped patients with difficulty in walking had to crawl because they cannot afford a wheelchair.



這位殘障人士，走路時用兩張凳子來支撐身體走路。

This handicapped patient used two stools to support the body on walking.

只能經常困在家中，他的生活圈子會變得狹窄，對身、心健康都有不良影響。

最好的活動能力當然是自由獨立地行走，其次是用支具、拐杖或助行器等輔助工具行走，再其次就是用代步工具包括輪椅和手動三輪車等。

with limited mobility. He/she is confined at home and the social circle is restricted. This has harmful effects to the physical and mental health of the person.

The best mobility is independent walking. Next will be walking with braces, crutches, or walkers. Then, there are those that need to use wheelchairs or hand-operated tricycles.

Over half of my patients have difficulties walking. Many have physical deformities. Orthopaedic surgeries can correct deformities and restore or improve the mobility of patients. However, many orthopaedic surgeries are major operations that include tendon release, tendon transfer, osteotomy, and internal fixation. Most patients need postoperative casting and physical therapy. A successful orthopaedic treatment, from surgery to rehabilitations, can take many months. For more complicated cases, surgeries have to be done in stages. The time spent on treatment can be several years.



殘疾患者往往要依賴父母扶抱。

Handicapped patients frequently need family members to carry them.



我的病人中有一半以上是不良於行的。不少病人有肢體殘疾，可以通過骨科手術把變形的肢體矯正，恢復或增加活動的能力。但畢竟骨科手術不少是複雜的手術，可能包括鬆解、肌腱轉移、截骨、內固定等步驟，而且手術後一般要打石膏和做物理治療。一個成功的骨科治療由手術到康復完成往往要幾個月，若果是更複雜的個案，可能要分階段做幾個手術，花上的時間可能數年之久。

天鄰骨科隊每次出隊的時間約兩星期，其中要花上兩天在旅途中，能夠做手術的日子不超過十天。即使有足夠的骨科醫生、麻醉科醫生和護士，每次能夠接受手術的患者約 20 至 40 位，面對眾多需要手術治療的貧困病人，實在是僧多粥少。

Each orthopaedic service team spend about two weeks in the mission field. About two days are spent on traveling. So, the time left for surgery is less than 10 days. Even with enough orthopaedic surgeons, anesthesiologists, and nurses, the number of patients that can be operated in each mission trip is between 20 to 40. In face of the huge number of physically disabled orthopaedic patients in poverty, this is like a drop in a bucket of water.

Besides, there are patients that are not suitable for surgery due to underlying health issues. There are also patients who do not want to have operations. Therefore, an alternative treatment is much needed besides surgery.



一位幼年因為嚴重感染而做了截肢手術之病人。

A man with hip disarticulation done due to severe infection in early life.



病人接受了手動三輪車之捐贈，與物理治療師及作者合照。

Patient received a donation of hand-powered tricycle. He had photo with physiotherapist and author.



550 張輪椅安裝完成，等候發放。

550 wheelchairs were assembled, ready for distribution.



天鄰第一隊輪椅隊，由羅省聖經宣道教會會友組成。

The first wheelchair team of HIS Foundation. It was formed by members of Chinese Bible Mission Church of Los Angeles.

此外，有不少病人的健康症狀不適宜做手術，也有些病人不願意接受手術，所以必須在手術治療以外尋求其他解決方案。

在美國，行動不便的患者都經常有輪椅代步，但縱觀在中國大陸，很多病人都沒有輪椅，不少病人要在地面上爬行，孩童則依靠家人背負。在追究原因之後，發現國家的醫療保險中不包括輪椅，而不少病人也負擔不起輪椅。

一次，一位只有一條腿的病人來找我，原來他一歲的時候因為嚴重感染，從髖關節起切去左下肢，多年來，他就靠一條腿一跳一跳般走路。他要求我們送他一輛手動三輪車，他得到三輪車時，面露滿足的微笑，這又加深我為病人尋找代步工具的構思。

如果能夠令更多的患者得到輪椅，輪椅必須價廉物美，這樣才可以大量捐贈，在中國購買不大可行，因為資

In the United States, when there is a patient with difficulty walking, a wheelchair will be provided. In China, on the other hand, I frequently see patients crawling on the ground. Children with disability are often carried by their parents. After looking into the problem further, I found out that the government healthcare insurance does not include wheelchair. Many patients are also not able to afford a wheelchair.

Once, a man with only one leg came to see me. This gentleman had a serious infection when he was only one year old. It ended with left hip disarticulation. He had been hopping on his one leg all the time wherever he went. He requested a hand-powered tricycle. When he received the tricycle, he showed a satisfying smile in his face. This reminded me again to seek solution for people with difficulties in ambulation.

If we want to donate large number of wheelchairs, then the wheelchairs must be affordable and durable. To purchase

金有限。我接觸了多個在美國捐贈輪椅的基督教事工，雖然他們是願意捐贈，但很快就發現運送輪椅到中國是一個大問題，因為入口時會徵收關稅，令成本增加。我曾通過中國紅十字會向中國海關要求豁免入口稅，可惜紅十字會最後的答覆是辦不到。這就令大量捐贈輪椅的想法擱置起來。

一次，我閱讀到美國有一個新的基督教組織，稱為免費輪椅事工（Free Wheelchairs Mission），而且其總部距離我家不遠。我馬上與該組織聯絡，並且前去拜訪。我發現他們的輪椅是自發研製的，他們用上海的工廠來製造，那麼如果在中國使用，就不用經過海關。商談之後，很快就與他們結成伙伴，開展了在中國捐贈輪椅的事工。

wheelchairs in China was not a good solution because our funding was limited. I contacted several Christian organizations that donate wheelchairs in the United States. Some were willing to donate wheelchairs to China. However, I soon found out that shipping wheelchairs to China was a problem. The custom in China would apply an import tax and thus the cost of delivering wheelchair could be high. I contacted the Red Cross Society in China who in turn contacted the Custom Department in China. We asked for tax exemption. The final reply from Red Cross was that it could not be done. So, the thought about mass donation of wheelchairs was put on hold.

One day I read about a new Christian non-profit organization called Free



經過一年多的預備，終於在 2006 年在河南省駐馬店市舉行了第一次的輪椅捐贈大會，捐出的輪椅共 550 張。美國羅省華人聖經宣道教會與天鄰合作，派出一隊五人的輪椅隊，負責組裝輪椅，他們工作效率非常高，能夠在指定時間內提早完成。當時取輪椅的病人及家屬，都展示出燦爛的笑容。此外，輪椅隊又將部分輪椅，送到病人府上，這份禮物令不少人意出望外，喜極而泣。於是，第一次捐贈輪椅的成功，奠定了日後輪椅事工的發展，令數以萬計的患者受惠。



第一次輪椅捐贈發放大會，在河南省駐馬店市舉行。

The first wheelchair distribution ceremony was held at city of Zumadian, Henan.

Wheelchairs Mission. Their headquarter is fairly close to my home. I contacted them and paid them a visit. I found out that they designed their wheelchairs and used the factories in Shanghai, China to manufacture them. If these wheelchairs are being used in China, then they do not have to go through custom. After discussion, we soon formed a partnership to donate wheelchairs in China.

After more than a year of preparation, the first wheelchair donation ceremony was held at city of Zhumadian, Henan Province in 2006. The number of wheelchairs donated was 550. The Chinese Bible Mission Church of Los Angeles partnered with HIS Foundation. They sent a five-member wheelchair team to assemble the wheelchairs. They were so efficient that they finished ahead of time. When patients and families came to collect their wheelchairs, they all had brilliant smiles on their faces. The wheelchair team also delivered some wheelchairs to patients' homes. Many could not help but cried in tears when they received the surprise gifts. The success of the first mass donation of wheelchairs was the foundation of subsequent wheelchair ministry which benefitted tens of thousands of patients.



輪椅心

A Passion for Wheelchairs

劉安群 美國輪椅隊隊長

Sol Lau US Wheelchair Team Leader

Translation by James Lau

2008 年，我第一次在河南地區廣場派發輪椅，看到不少殘疾人，在遠處緩緩爬行而來（圖 1-2），當時真不敢相信自己的眼睛，人竟然活得如此沒有



圖 1 Photos 1



圖 2 Photos 2

一些殘疾人士不能站立和行走，只能蹲著或爬行。

Some handicapped people are not able to stand or walk, they can only squat and crawl.

In 2008, in an open square in Henan Province, when I first participated in wheelchair distribution, I saw many handicapped people crawling slowly toward the distribution center (photos 1-2). I could hardly believe the scene before me. People were living in such an undignified way! My heart sunk and tears began to swell in my eyes. When the handicapped people came closer, breathing heavily, I saw their faces covered with sweat. But in fact, they were elated (photos 3-5). Their eyes scanned the surroundings, looking for the wheelchairs that were going to change their lives. Suddenly I realized the importance of a wheelchair. Its significance to a handicapped person far exceeded what I had imagined. As I saw their excitement, my sadness vanished. I understood that we are doing something very important.

In tears, I thanked God that I have no disability. I could move around freely. I could even serve by distributing the wheelchairs which would change the lives of the recipients. I wished that the wheelchairs would bring new strength into their lives, and my passion for wheelchairs became deeply seeded in my heart.

Home visits were part of the service program of our wheelchair team. We wanted to find out how the wheelchairs were being used at home. Unexpectedly, the home visits gave me a much better understanding of the poor and the helpless situation of the disabled. We met a single mother taking care of a handicapped child unable to walk. She was exhausted and had little hope. An old

圖 3-6 Photos 3-6



接受了輪椅捐贈的傷殘人士展示出燦爛的笑容。

Some handicapped people showed brilliant smiles after receiving wheelchair donation.

尊嚴！我的心立刻沉了下來，眼中也忍不住流下淚水。當他們努力爬到了近處，看到他們雖然滿面汗水，但卻散發着興奮的表情，噴發著緊張的呼吸氣息，充滿着希望的眼神，四處張望，期待着那張可以改變他們生命的輪椅。突然之間，我深深感覺到原來一張輪椅對這些人的影響，是遠遠超乎我們平時想像的，看到了他們興奮而帶喜樂的表情（圖 3-5），我當時內心立刻從悲傷中提升了起來，覺得輪椅的意義竟然是如此的大！

我在淚中感謝天父我是一個四肢健全的人，可以自由行動，而我有能力付出一點點，送上輪椅，可以帶給殘疾人們生命的改變，為他們送上盼望，使他們重新得力！「輪椅心」就在當天烙印在我的心內！

輪椅隊開始的時候做家訪，原則是觀察輪椅的使用情況，

couple, one bedridden (photo 6) and the other walking with difficulty, lived alone in a broken house with little help from others. The couple seemed to be waiting for the end of their lives. People in poor villages endure a harsh existence filled with loneliness and pain. Handicapped people need more than wheelchairs; they need encouragement, comfort, and the healing of their psychological trauma.

I took part in 10 wheelchair teams. In addition to the mass distribution of wheelchairs in cities (photos 7-9), we donated wheelchairs to hospitals, elder-care homes, orphanages, and remote villages (picture 10-11). We tried to care for the handicapped. Sometimes we prayed together (picture 12), and we shared the gospel and God's love with them.

As we cared for the disabled people, we mixed sweat and tears of joy. Not only the handicapped people but also the local volunteers and party leaders were deeply moved by our actions.

In 2014, we traveled to many cities and villages in Inner Mongolia to donate wheelchairs to the poor

但意想不到，在家訪中能更深體會到殘障人的可憐無助，有母親孤單照顧殘疾不能行動的孩子，心力交瘁，看不到一點希望。有老人家只剩下老伴，一個殘疾在床（圖 6），一個行動不便，只有相依為命，在殘破的屋子內默默等待着生命的結束。在貧困的農村特別生活困苦，心靈極度孤單及傷痛，殘疾人除了需要輪椅幫助行動之外，更需要關懷安慰及鼓勵，去醫治他們心靈上的創傷。

10 次出隊的過程中，輪椅隊除了在城市集體送出輪椅外（圖 7-9），還多次去到偏遠的農村（圖 10-11）、醫院、老人院及孤兒院等等，向需要愛心關懷的殘障人，送上輪椅及關懷，甚至在適當的時候與殘障人祈禱（圖 12），將福音及天父的愛介紹給他們。

在關懷及互動時，經常淚水與歡笑都混在一起，不單止殘障人深深受到感動，當地的志願者及幹部往往都被觸動。



圖 7-9 Photos 7-9

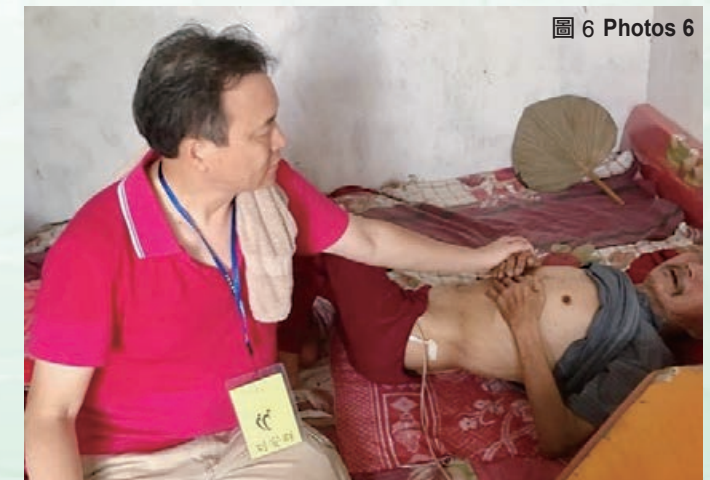

圖 6 Photos 6

一位殘疾在牀的年老病人。

A bed-ridden old man.



輪椅隊到不同城市發放大批輪椅。
Mass donation of wheelchairs in different cities.

圖 10-11 Photos 10-11



輪椅隊把輪椅送到病人家中。

Home delivery of wheelchairs.

我們在 2014 年去到內蒙古，走訪了多個城市及農村，把輪椅送到貧窮無助的殘疾人中。其中有一個農村男人，因為冬雪凍壞了雙腳，手術割除了雙腳後，只可以癱瘓住在一個破爛的土穴中（圖 13），心灰意冷，

and crippled people. A man in a village suffered frostbite during a blizzard. Both legs became gangrenous and had to be amputated. This man, so severely handicapped, had a motionless face and lived in a cave (photo 13). Deeply disappointed and frustrated, he refused to leave home and was waiting for death. He also refused to accept

圖 13 Photos 13



一位雙下肢做了截肢手術的貧困患者。

A bilateral lower limb amputee lived in poverty.

圖 12 Photos 12



輪椅隊隊員與病人一起禱告。

Wheelchair team members prayed with patients.



目無表情。他拒絕出門，只想在裏面等待生命的結束，我們把輪椅送到，他也拒絕接受。後來我們對他作出將近 1 小時的安慰關懷，他終於答應讓我們抬他出洞穴，幫他爬上了輪椅，推著他在村路上走動。他凝望着天空，慢慢將自己再次融入環境中，心扉開始慢慢放開（圖 14）。在我們離開的時候，他竟然露出了笑容（圖 15），用力握著我們的手，捨不得我們離開。藉著送上一張輪椅，附上愛心關懷，令他對生命重拾信心，再次激發起他的生活意志。

一位婆婆及公公，住在農村一所殘破屋中，兒女為生活都去了外省工作，缺乏人照顧（圖 16-18）。公公不能行走，每天



圖 14 Photos 14



圖 15 Photos 15

接受了輪椅捐贈的截肢患者喜出望外。

The bilateral amputee smiled after receiving the wheelchair donation.

the wheelchair. We spent about an hour trying to comfort him. Eventually, he agreed to let us carry him out of the cave and put him in the wheelchair. We pushed him around to see the village. He looked at the sky and enjoyed the environment. He gradually opened his heart (photo 14). By the time

圖 16-18 Photos 16-18



輪椅隊探訪一對年長寂寞的公公婆婆，並捐贈輪椅給卧病在牀的公公，婆婆很受感動。

Wheelchair team visited a lonely old couple and donated a wheelchair to the bedridden gentleman. The wife was deeply touched by the donation.

只可躺在床上。老婆婆也沒有能力去領取輪椅，於是我們把輪椅送到他們家中，婆婆流淚滿面，不停說着她的孤單故事，就像要將多年的苦楚，一瞬間盡數說出來。到最後她還依依不捨，用力握我們的手，流着淚卻帶著笑容，捨不得讓我們離開！有人去探望了解他們，實在不比獲得一張輪椅的份量輕，藉著輪椅加上關懷，他們感覺到原來世界上還是有人關心他們的。

2015 年，我們去到新疆送出輪椅，新疆面積廣大，民族繁多，人口分布極不平均，是殘障人士最被遺忘的地方。很多人根本沒有能力去領取輪椅，我們於是把輪椅運到不同的地點組裝，再分發出去。有一個維族的婦女，中風在家躺臥多年，也說不出話，只有丈夫工作後可以照顧她。當我們去到的時候，她非常激動地沙啞著大叫，全身發抖不停，只是緊握着我們的手，不停的哭，內心的抑鬱苦澀，一時之間全都釋放出來。

在新疆，除了到不同民族的家庭送輪椅（圖 19），還去了一所殘疾兒童的孤兒院。這孤兒院非常簡陋及缺乏物資，沒有輪椅，這些殘疾孤兒都是要在地上爬行，令人非常痛心。他們基本是腦癱所以沒有言語能力，幾十個孤兒只有幾個工作人員及志願者日常照顧，工作壓力非常大。我們除了為他們送上輪椅外，也為他們帶去面彩劃筆及魔術遊戲，和孩子們互動，為這些平時沒有笑容的孩子，帶來歡樂，讓

we were about to leave, he smiled and shook our hands (photo 15). He did not want us to leave. By donating a wheelchair, we showed our passion and care, and thus rekindled his will to live.

We met an old couple living in a dilapidated village house. Their children had all gone far away to work, and no one was left to care for the old couple (photos 16-18). The man could not walk, so he sat on the bed the whole day. Because the wife was not able to pick up the wheelchair, we delivered it to their home. She was so grateful that she started to cry. We listened to her stories of a bitter and lonely life. As we left, the old woman shook our hands; crying, she implored us to stay longer. Visiting the village people was almost as important as donating a wheelchair. In doing so we showed that there are people who care.

In 2015, we went to Xinjiang to donate wheelchairs. Xinjiang is a vast area with many different ethnic groups. The population is unevenly distributed, and handicapped people are often forgotten. Because they usually do not have the ability to pick up the wheelchairs, we sent

圖 19 Photos 19



輪椅送到一個小數族裔家中。

Wheelchair was delivered to home of a minority group.

他們重拾一下孩子的天真。工作人員對我們說，孩子從來沒有這樣笑過，甚至不知道他們是會笑的。現在孩子有了輪椅，除了孩子可以多點出來曬太陽，也大大減輕了工作人員每天的工作壓力，他們都非常感恩（圖 20-24）！

我們送輪椅到過幾個相信基督的殘疾人家庭（圖 25），他們在疾病的壓迫下，幾十年來仍然堅守相信耶穌基督。我們一同握手祈禱，互相鼓勵，相擁而哭

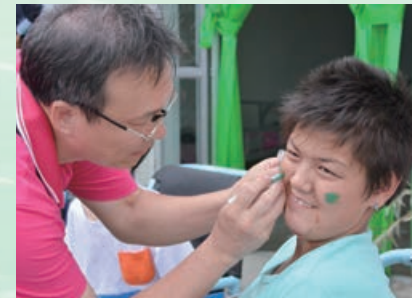

圖 20-24 Photos 20-24

the wheelchair parts to different locations and assembled them on site before delivery. We met a Uighur lady who had had a stroke and spent most of the time lying in bed at home. She was not able to speak. Only the husband was available to take care of her after work. The woman became very emotional during our visit; she screamed with a hoarse voice and her body trembled. She held our hands and cried ceaselessly. We could feel her bitterness, built up over many years, releasing.

In Xinjiang, besides delivering wheelchairs to families (photo 19), we also visited an orphanage for crippled children. The orphanage was crude, lacked many supplies, and had no wheelchair. The sight of handicapped children crawling around filled me with sadness. Many children had cerebral palsy and could not speak. Only a handful of workers



輪椅隊探訪一個為殘疾兒童而設的孤兒院，除了捐贈輪椅外，還舉辦有趣的活動，令孩子非常開心。



Wheelchair team visited an orphanage for crippled children. Besides donating wheelchairs, fun activities were conducted. Children were filled with joy.

(圖 26)，再次向他們確定，基督的愛沒有離棄他們，他們都受到很大的鼓舞，知道神還是愛他們的！

結語

每次出隊送輪椅回來，身體都很疲勞，但心靈卻充滿喜樂。希望在輪椅隊離開之後，留下給殘障人的不單止是一張輪椅，而是天父偉大的愛，像溫暖的火花，能把貧窮殘障人的生命，再次燃點起來，讓他們重新得到盼望。

祈禱求望神，將生命火種，藉着各種方法，去繼續安慰燃點殘疾人。

圖 25 Photos 25



輪椅隊探訪有殘疾人士的基督徒家庭。

The wheelchair team visited a Christian family with disabled person.



圖 26 Photos 26

and volunteers were present to care for scores of children. Their workload was dauntingly high. We interacted with the children with fun activities such as face painting and magic tricks to bring back some of the joy of childhood. We saw sullen children begin to smile. The local workers spoke to us in surprise because they had thought that the handicapped children were unable to smile. With the wheelchairs, children could be brought outside for a sun bath. The wheelchairs reduced the workload of the staff, and they were very appreciative of the donation (photos 20-24).

We donated wheelchairs to several Christian families with handicapped people (photo 25). Even under the crushing pressure of disability, they maintained their belief in Jesus Christ. We held hands and prayed together. We embraced and cried together (photo 26). We encouraged each other and confirmed the belief that Christ's love never ceases.

Epilogue

Following each a wheelchair donation trip, my body felt tired, but my spirit filled with joy. I sincerely hoped that after we left not only did the disabled and poor gain a wheelchair but that they also recognized the love of God. The love is like a spark of fire; it rekindles the hope for life.

May God continue to use different methods to spread this hope for life. May the hope shine bright among the handicapped people.

輪椅隊隊員與當地基督徒相抱而哭。
Wheelchair team member embraced and cried with a local Christian.

一張輪椅、一份愛心

A Wheelchair: A Gift of Passion

馮美蓮 美國輪椅隊隊長

Katherine Fung US Wheelchair Team Leader

十年前是我第一次參加輪椅事工，我當時帶著十多位弟兄姊妹首次踏足雲南大理。這古城十分美麗。

由於組裝的是新一代輪椅，各組員在出發前已經花上不少時間去練習。這個新設計的座位及背部都是綁繩的，製作需時，所以整個組裝過程就變得更有感情和意義。

這次總共要發放 500 張輪椅，分別送到不同的教會。然後他們會幫忙發放到個別家庭。獲贈者大部分是患有腦癱或小兒麻痺症，由於他們缺乏適當的治療，日常生活都是依靠家人來照顧，嚴重的連吃飯及如廁都要幫忙，實在為家人帶來沉重的負擔。

除了教會幫忙，我們亦有親身把輪椅送到天鄰的病人家中，他們非常貧窮，住在偏遠的地方而且家徒四壁，看到他們的貧困，我心裏非常難過，讓我更加體會到自己的生活是何等豐富呢！

我看見每個被探訪的家庭都充滿著感恩，因為這張簡單的輪椅能夠帶給他們無限的方便。病人也因此可以在家中自由走動！

Ten years ago, I participated in a wheelchair ministry for the first time. During that trip, I led over ten brothers and sisters to visit Dali, Yunnan. I marveled at the beauty of this ancient city.

Since the wheelchair we brought with us that year had a new design, each team member spent a lot of time learning and practicing the assembly instructions before we embarked on our travels to China. Ropes tied together the newly designed seat and back, so the entire assembly process required additional time, but our efforts became more sentimental and meaningful.

We needed to distribute a total of 500 wheelchairs to different churches. Each church in turn would help distribute the wheelchairs to families in need. Most of the recipients suffered from



輪椅隊隊員在安裝輪椅。

Wheelchair team members are assembling wheelchair.

其中最難忘是探訪一位獨居女士，年約四十，患有肌肉萎縮症。她的雙手和腳都已經萎縮，以致她不能活動或走路。當時我在她的門前拍了好幾次門，然後她慢慢地一步一步從屋裏爬出來。看見她的境況，我和幾位姊妹都忍不住落淚……

由於她的親人都因此病過世，剩下她一個人過著孤獨痛苦的生活。幸好附近教會有些姊妹會到來送食物和照顧。雖然她不能自己推動輪椅，但姊妹們可以帶她在附近散步，若要出門看病就更方便了。

當時她四肢無力，我們要三個人才能把她抱到椅上。坐在輪椅上的她，非常感動，因為她不需要抬起頭來跟我們對話。這張簡單的輪椅為她拾回一份寶貴的尊嚴！又代表著一份從天父而來的愛！



一位患有肌肉萎縮的病人從她家中慢慢爬出來。
A patient with muscular dystrophy slowly crawls out of her house.



接受輪椅的患者中包括腦癱病人。

Cerebral palsy patients are among those received wheelchair donation.

cerebral palsy or poliomyelitis; they lacked proper treatment and therefore had to rely on their family members for daily care. In some of the more severe cases, the family had to help with feeding and going to the toilet, creating a heavy burden for the whole family.

Besides working with local churches, we also personally delivered wheelchairs to the homes of several surgery patients. They were extremely poor and lived in remote areas in houses tightly surrounded by four walls. Seeing their impoverished environment, I felt deeply saddened, and I reflected on how rich my own life was.

I remember how each family we visited was full of gratitude because this simple wheelchair

我非常幸運，因為第二年我又有機會再參與這事工。當時我帶領十位弟兄姊妹首次探訪極少人關懷的麻瘋村。

麻瘋村的位置非常偏僻而且大部分都在崎嶇的山上，每次車程約三小時，來回就需要六小時。我們分成兩隊，由當地的基督教團體或傳道人帶我們上山，這次探訪了好幾個不同的麻瘋村。每條村的人數都是從本來有一百多人到剩餘十幾人。因為這個病早就有醫治的藥物及方法，所以不會再有新病人入住，而且很多人因年老已過世。病人大多是幾十年前發病時被送入村，從此就和家人隔絕，過著孤獨痛苦的人生。

由於山路非常危險，我們只



病人坐在輪椅上。
Patient was seated on the wheelchair.



病人與輪椅隊員合照，作者是左邊第三位。

Patient had a photo with the wheelchair team members. The author is the third one from the left.

brought them unlimited convenience, and, most importantly, these patients could now move around freely at home!

One of our most unforgettable visits was to a lady living alone. She was about forty years old and suffered from muscular dystrophy. Her hands and feet were atrophied so much that she couldn't move or walk. I knocked on her door many times before she crawled slowly out of the house, step by step, to let us in. Seeing her situation, a few sisters and I couldn't hold back our tears.

Because all her relatives had died of the same illness, the lady was left alone to lead a solitary and painful life. Fortunately, some sisters from nearby churches would come to deliver food and provide care for her. Although she could not push the wheelchair by herself, the wheelchair did make it easier for the sisters from church to move her around or take her for doctor's visits.

She had weakness in all her limbs, so we



病人因麻瘋病而失去了手指。 Autoamputation of fingers in a leper.

能坐最小的貨車上山，並且就在當場安裝輪椅。這是我人生第一次接觸到麻瘋病人，說真的，我當時的確有點害怕，因為他們大部分都沒有手指和腳趾，有些傷口或疤痕是比較難看，但我記起聖經曾記載主耶穌去擁抱麻瘋病人，所以我便效法基督，用愛去服侍有需要的人。當我抱著他們的時候，恐懼就隨即消失了。其實他們跟我們沒有什麼分別，而且非常友善。



needed three people to hold and carry her onto the wheelchair. She was very touched when we seated her in the wheelchair, as she no longer needed to raise her head to talk to us anymore. This simple wheelchair was like a gift and allowed her to regain dignity, which was so precious! It also represented a love from our Heavenly Father!

I felt very lucky when, in the following year, I successfully applied for time off from work so that I could join the wheelchair ministry again. On this second trip, I led ten brothers and sisters on a visit to a leprosy rehabilitation village, a place not many people would venture into out of a desire to extend care to the inhabitants.

The Leprosy Villages were located in remote, rugged mountains. Each car ride took about three hours, so six hours for a round-trip. We divided into two teams, and the local Christian group took us up to the mountains. We visited several different villages and discovered that the number of people in each village had fallen from over 100 originally to less than a dozen. The advent of treatment with



一些麻瘋病人因為足部破損嚴重而失去走路的能力。

Some lepers have serious damage to their feet and lost the ability to walk.

他們當中有一位男士年約60歲，他走路時是用膝蓋的，原來麻瘋病令他失去腳趾和腳掌，看著他每天在地上跪著行路，我心裏為他很難過！我們真的要為我們所擁有的去感恩。

感謝主！讓我有機會和一班已經康復的麻瘋病人一起傾談，唱詩，跳舞和禱告。雖然他們身上有殘疾加上被人遺棄，但籍著一張簡單的輪椅，使他們相信上帝並沒有遺棄他們。

我喜愛輪椅事工，因為它讓我親身經歷到別人生命的改變。誠意邀請你一起“讓愛走動”！



一位截肢的麻瘋病人接受了輪椅捐贈。

A leper who is an amputee received a wheelchair donation.

leprosy drugs and therapies meant that no new patients would be sent to the villages, and many lepers had already passed away due to old age. Most of the patients had arrived in the villages decades ago after becoming ill. Since then, these patients have been isolated from their families and living a lonely life in pain and suffering.

The mountain roads leading to the villages were dangerous, so we could take only the smallest truck up the mountains. Because of this, the wheelchairs had to be assembled on the spot. This was the first time in my life I had met a leper. To be honest, I felt apprehensive, a little scared, when I saw that most of the lepers did not have fingers or toes, and some had disfiguring wounds or scars difficult to look at. Then I remembered that the Bible says the Lord Jesus went to hug the leper, so I was reminded to follow the example of Jesus Christ and serve those in need with love. When I hugged them, my fear went away immediately. In truth, the lepers are really no different from us, and they are very friendly.

We met a man about sixty years old in one of the villages. He walked on his knees because his feet had been amputated due to leprosy. Watching him kneeling on the ground every day, I felt very sad for him! We truly must be grateful for what we have.

Thank God! He gave me the opportunity to talk, sing, dance, and pray with a group of lepers who have recovered. Although they have disabilities and were abandoned by others, a simple wheelchair made them believe that God had not forsaken them.

I love the wheelchair ministry because it allows me to experience changes in other people's lives. I sincerely invite you to join the ministry and "Let love overflow"!

輪椅事工分享

吳國華 香港輪椅隊隊長
Condor Ng Wheelchair Team (Hong Kong) Leader

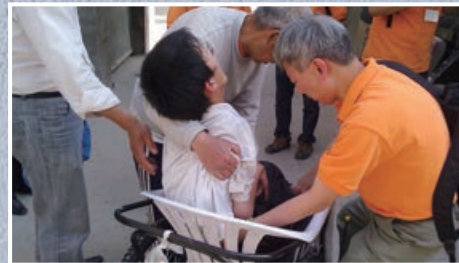希伯來書 13:5 下，因為主曾說：「我總不撇下你，也不丟棄你。」因著這句神的話，我堅持參與天鄰輪椅事工已有 8 年，這 8 年裡也親眼看見神沒有丟棄身體殘疾並需要輪椅的病患者。我經常分享說：「我能夠出隊，不是我的能力強，而是上帝的恩典，祂給我機會與祂同行，經歷祂的作為，讓我學習謙卑及信靠祂！」每當我回顧這些走過的日子，神經常提醒我在祂那裡沒有難成的事，但小信的我總是難免擔憂，感謝上帝的慈愛和信實，祂帶領我一步一步地建立了對祂的信心。

大約 20 年前，教會肢體邀請我和太太參加天鄰基金會醫療事工 10 周年感恩會，因此，我們開始認識了天鄰的工作。當時我心裡十分感動，受助者臉上的歡欣喜悅和義工們無私奉獻的精神等，都深深刻在我心。由於我和太太工作都十分忙碌，加上要照顧孩子，因此一直無法參與天鄰的服侍。



「由消極變為積極」2014 年 5 月河南省安陽市輪椅發放大會受助者。

"changed from negative to positive". Recipients of the wheelchair distribution ceremony in Anyang City, Henan Province. May 2014.



「藉輪椅的幫助，追求理想人生」2012 年 5 月家訪受助者。

"With the help of a wheelchair, I can pursue my dream" said the wheelchair recipient. May 2012.



「由悲哀變為歡欣」2014 年 5 月河南省安陽市家訪受助者。

changed from sorrow to joy". Recipients of home visit in Anyang City, Henan Province. May 2014.



「坐著輪椅快樂地回家」2016 年 6 月在河南省周口市輪椅發放大會。

"Go home happily with wheelchair". Wheelchair Distribution ceremony in Zhoukou City, Henan Province. June 2016.



2018 年 4 月 22-24 日焦作市輪椅發放大會，「母子同心」。

"Mother and Child with same heart". Jiaozuo City Wheelchair Distribution ceremony. April 22-24, 2018.

Wheelchair Ministry Sharing

Hebrews 13:5b, God said, "Never will I leave you; never will I forsake you." ". Because of these words from God, I have been persistent in serving the HIS Foundation Wheelchair Ministry for 8 years. In these years, I witnessed that God did not forsake patients who are physically disabled and in need of wheelchairs. I often share that "I am able to join the mission team, not because of my strong ability, but by the grace of God. He gives me the opportunity to walk with Him, experience His actions, and learn to be humble and trust Him!" Every time I look back these past years, God often reminds me that there is nothing impossible in Him, though I am always worried due to little faith. Thank God for His love and faithfulness. He has led me to build up my faith on Him step by step.

About 20 years ago, one member of our church invited my wife and I to attend the 10th Anniversary Thanksgiving Dinner of HIS Foundation Medical Ministry. Then, we started to know the ministries of HIS Foundation. I was touched by the sharing that evening. The joy on the faces of the wheelchair recipients and the spirit of selfless dedication of the volunteers impressed me deeply. Since my wife and I were very busy at work and had to take care of our child, we were unable to join the service of HIS Foundation.

At the beginning of 2012, our child went to study in the UK, then my wife and I had some free time. My wife and I decided to join the wheelchair team that served Huaxian and Neihuang County of Henan Province in May. At that time, the volunteers were mainly members from the United States. I was amazed when I heard their sharing. Some members had joined



「無言的感激」2016 年 10 月 23-29 日
河南省駐馬店市西平縣家訪。

"Speechless Gratitude". Home visit in Xiping County, Zhumadian City, Henan Province. October 23-29, 2016.

2012 年初，孩子到英國留學去了，我和太太才有些餘閒時間，太太便約我一起參加 5 月河南省滑縣和內黃縣輪椅隊。當時的義工主要是來自美國天鄰的隊員，聽他們分享時我呆住了，有些隊員已是第四年參加輪椅隊，我心裡充滿敬佩之情，因而問他們什麼原因會多次參加輪椅隊，他們說輪椅活動完結後我便得到答案。及後知道，天鄰輪椅事工是從 2006 年開始，美國天鄰基金會與美國一間基督教機構「免費輪椅事工」（Free Wheelchair Mission，下稱 FWM）合作，捐贈輪椅到河南、雲南及四川等省份，為貧困殘疾人士擴張活動空間，改善生活質素，也減輕了家人照顧的負擔。

抵達目的地的第二天，在組裝場地我和太太合作組裝輪椅，平常缺少運動的我，完成一天輪椅組裝後，雖然筋疲力竭，全身痠痛，但心靈卻是滿足。到了第四天，我們把組裝好的輪椅送到受助者的家裡；其中一個家庭有一位當門衛的長者，他收養了一個被拋棄的腦癱少年，這少年人說有了這張輪椅後，養父便不用那麼辛勞地照顧他，可以輕鬆地推他到外面走走，還可以上課學習……。我聽後頓時明白「老」隊員多次參加輪椅隊的原因，原來受助者可以透



「破舊立新」2017 年 6 月 11-16
日河南省安陽市滑縣家訪。

"Shabby and New". Home visit. Hua County, Anyang City, Henan Province. June 11-16, 2017



2014 年 5 月在河南省安陽市與太太一起組裝 FWM 第一代輪椅。

Assembled the first-generation FWM wheelchair with my wife in Anyang, Henan Province. May 2014.



2018 年 4 月 22-24 日焦作市，隊員組裝印有天鄰標志的輪椅。

Team members assembled wheelchairs with the HIS Foundation logo. Jiaozuo City. April 22-24, 2018.



2016 年 6 月在河南省周口市與香港義工一起學習組裝 FWM 第二代輪椅。

Learned to assemble the FWM second-generation wheelchair with Hong Kong volunteers in Zhoukou City, Henan Province. June 2016.

the wheelchair mission for four years. I deeply admired their perseverance. I asked them why they had participated in the wheelchair mission for so many times. They said that I would get the answer at the end of the wheelchair mission. Later, I learned that the wheelchair ministry started in 2006. HIS Foundation (USA) partnered with an American Christian organization Free Wheelchair Mission (FWM) to donate wheelchairs to Henan, Yunnan, and Sichuan provinces for the poor people with disabilities so as to expand their space for activities, improve their quality of life, and reduce the burden of family care.

On the second day of arrival, my wife and I worked together to assemble the wheelchairs at the assembly site. Due to lack of exercise, I was exhausted and had aches all over after completing the wheelchair assembly for a day, but I felt so rewarded spiritually. On the fourth day, we delivered the assembled wheelchairs to the recipients' homes. Among the families we visited, an elderly working as a front gate guard adopted an abandoned teenager with cerebral palsy. The teenager said that with this wheelchair, his adoptive father would not have to take care of him so hard because his adoptive father could easily push him outside, and he could also attend school... After hearing this, I immediately understood the reason why the "old" team members participated in the wheelchair mission many times. Recipients can get help through the wheelchairs, they could have the freedom to live and socialize, regain their dignity and even pursue their dreams.

After joining the wheelchair mission in May 2014, four like-minded volunteers and I organized the core group of the Hong Kong wheelchair team. On July 30 of the same year, Hong Kong Wheelchair Team was formally established to

過小小的輪椅得到幫助，有了生活和社交的自由，重拾做人的尊嚴，甚至更可追尋理想。

在 2014 年 5 月出隊後，我與四位志同道合的義工組織了香港輪椅隊核心小組，同年 7 月 30 日香港天鄰輪椅隊正式成立。輪椅隊成立目的是讓我們從神而來的愛心，透過我們親自組裝的輪椅，直接地傳遞到中國內地的貧困受助者。他們藉著輪椅的幫助，加大活動的範圍，擴寬生活圈子，重建自信，心靈得到舒展，使生活更為積極，同時感受到人和神的關愛，與及天涯若比鄰的情誼，確信人間有愛。參與的義工們是與神同工，用愛心和行動，為上帝作美好的見證。我作為組長便先後到一些我們認識的教會、學校作宣傳、推廣及招募香港輪椅隊義工。



2015 年 5 月 17-23 日隊員合影，香港輪椅隊第一次出發。

Group photo of the first Hong Kong HIS Foundation wheelchair team. May 17-23, 2015.



2017 年 6 月 11-16 日河南省安陽市滑縣再度合作的本地義工，「人走情仍在」。

"Friendship forever."
Cooperated with local volunteers again in Hua County, Anyang City, Henan Province. June 11-16, 2017.



2018 年 5 月 21-26 日河南省安陽市滑縣輪椅隊探訪殘障兒童護理中心，「打成一片」。

"Mingled together".
Wheelchair members visited the handicapped children's care center. Huaxian County, Anyang City, Henan Province. May 21-26, 2018.

2012 年 5 月 13-20 日隊員合影，第一次參加輪椅隊。

Participating in the wheelchair team for the first time. May 13-20, 2012.

share God's love with the impoverished recipients in Mainland China through the wheelchairs we personally assemble. With the help of wheelchairs, they can expand the scope of activities, broaden their living circle, rebuild their self-confidence, soothe their hearts, and make their lives more active. At the same time, they feel the love of man and God, the friendship between neighbors in the world, and they are convinced that there is love in the world. Participating volunteers are co-workers of God. With love and action, they give a touching testimony for God. As the team leader, I went to some churches and schools in Hong Kong to promote the wheelchair ministry and recruit volunteers for the Hong Kong Wheelchair mission team.

On May 17-23, 2015, we started for the first time under the name of the Hong Kong HIS Foundation Wheelchair Team. We went to Lankao County of Kaifeng City and Runan County of Zhumadian City in Henan province. There were 28 team members, and a total of 550 wheelchairs were distributed at the two locations. However, the development of wheelchair ministry was not all the time smooth. Since 2017, FWM no longer supplied wheelchairs to HIS Foundation. Thanks to God's Grace and with our efforts, the core team finally found a manufacturer in Henan to produce the wheelchairs. In 2017, we started to distribute wheelchairs with the HIS Foundation logo. Between 2015 and 2019, HIS Foundation Hong Kong team made 8 trips, together with 133 volunteers, and 4,350 wheelchairs were donated.

Recalling the past 8 years, I was deeply amazed at His wonderful deeds in the wheelchair missions. God took care of my health, work, and family matters many times before I went for mission. God always provided sufficient numbers of volunteers who served passionately to assemble a good number of wheelchairs; we still reached Henan safely under Typhoon Signal No. 8; heavy rain suddenly stopped before the wheelchair distribution ceremony started; volunteers under the leadership of God worked smoothly as one body and completed the work early each time; the lost items suddenly were found. Unfortunately, due to the ongoing Covid-19, Qinghai Wheelchair Mission in 2020 had to be postponed. We pray that God could continue to lead, and we look forward to His blessings to everyone afar in the future!



2019 年 5 月 20-25 日河南省開封市蘭考縣輪椅隊，「精誠合作」。

"Sincere cooperation".
Lankao County Wheelchair Team. Kaifeng City, Henan Province. May 20-25, 2019.

2015 年 5 月 17-23 日，我們第一次以香港天鄰輪椅隊名義出隊，地點是河南省開封市蘭考縣和駐馬店市汝南縣，隊員有 28 位，分別在兩個點發放共 550 張輪椅。可是輪椅事工的發展並不是一帆風順，2017 年開始 FWM 不再供應輪椅給天鄰。感謝神的恩典及在我們努力下，核心小組終於找到河南的廠家訂製輪椅，2017 年開始便分發印上天鄰標誌的輪椅。2015-2019 年 5 年裡香港天鄰共出隊 8 次，出隊義工共 133 人次，合共捐贈了 4,350 張輪椅。

回想 8 年來，我深深地驚歎祂奇妙的作為，神在出隊前多次為我處理好我的健康、工作和家裡事宜，也預備好足夠數量的輪椅和熱心愛祂的義工；我們在 8 號風球下仍然平安到達河南；在輪椅發放大會前大雨忽然停止；義工們在神的帶領下如同一人，合作無間，每次都提早完成組裝；遺失的物件，突然又重現，失而復得。可惜由於新冠肺炎疫情持續，2020 年青海輪椅隊被迫延後，我們祈求上帝繼續帶領，期待將來和大家一起再把祝福送到遠方！

吳國華 (Condor)
2021 年 5 月 10 日



2017 年 6 月 11-16 日河南省安陽市滑縣輪椅隊出發前祈禱會，「堅心倚靠，求主引帶！」
“Pray for God’s guidance and we rely confidently.” Prayer meeting at Hong Kong Airport before departure. Hua County Wheelchair Team, Anyang City, Henan Province. June 11-16, 2017.

輪椅型號演變 Wheelchair Model change



FWM 第一代
FWM First Generation



FWM 第二代
FWM Second Generation



天鄰第一代
HIS Foundation First Generation



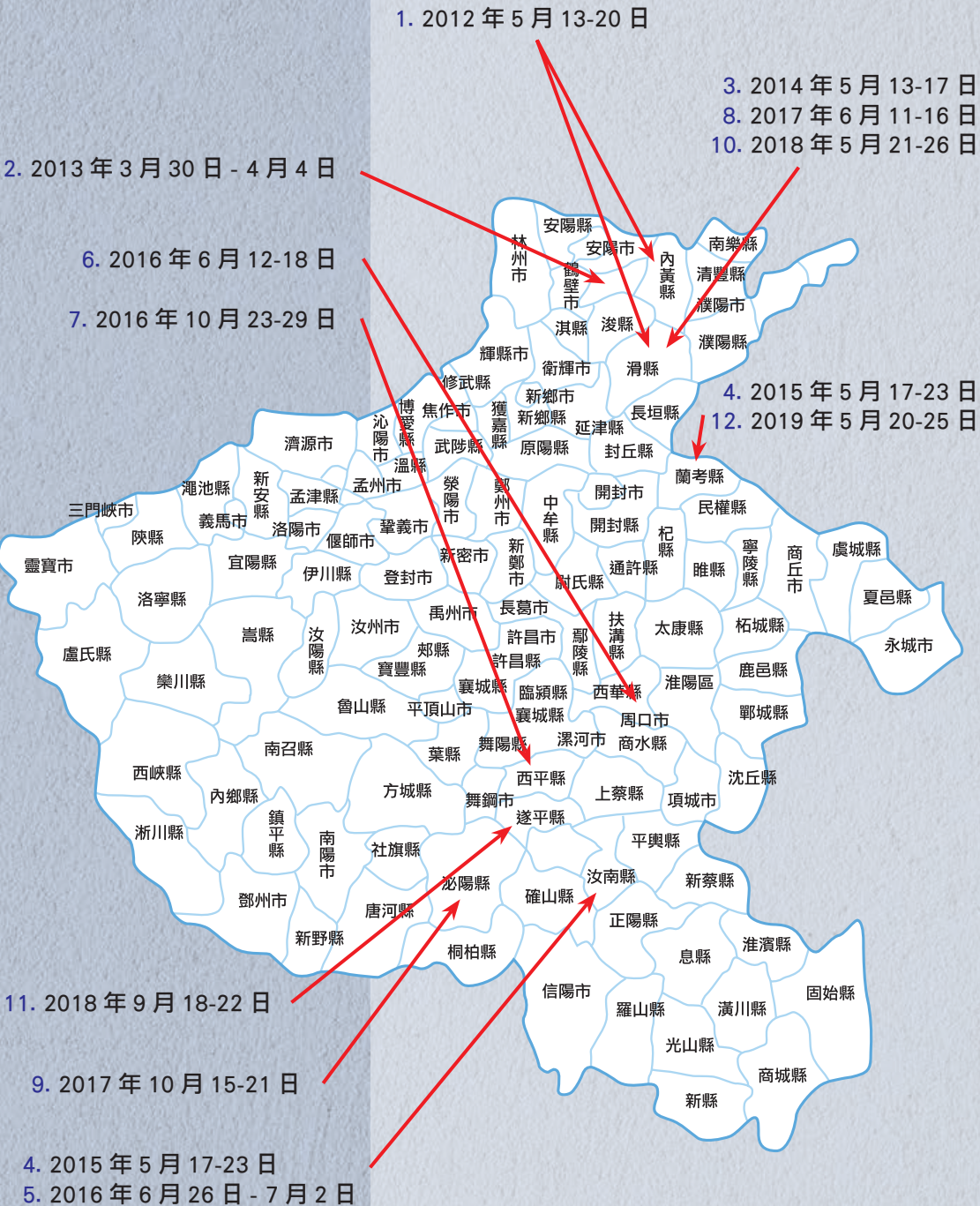
天鄰
第二代 A 型
HIS Foundation Second Generation Model A



天鄰第二代 B 型
HIS Foundation Second Generation Model B



輪椅隊出隊日期與地點 Wheelchair mission date and location



河南省縣級地圖
Henan Province County Map

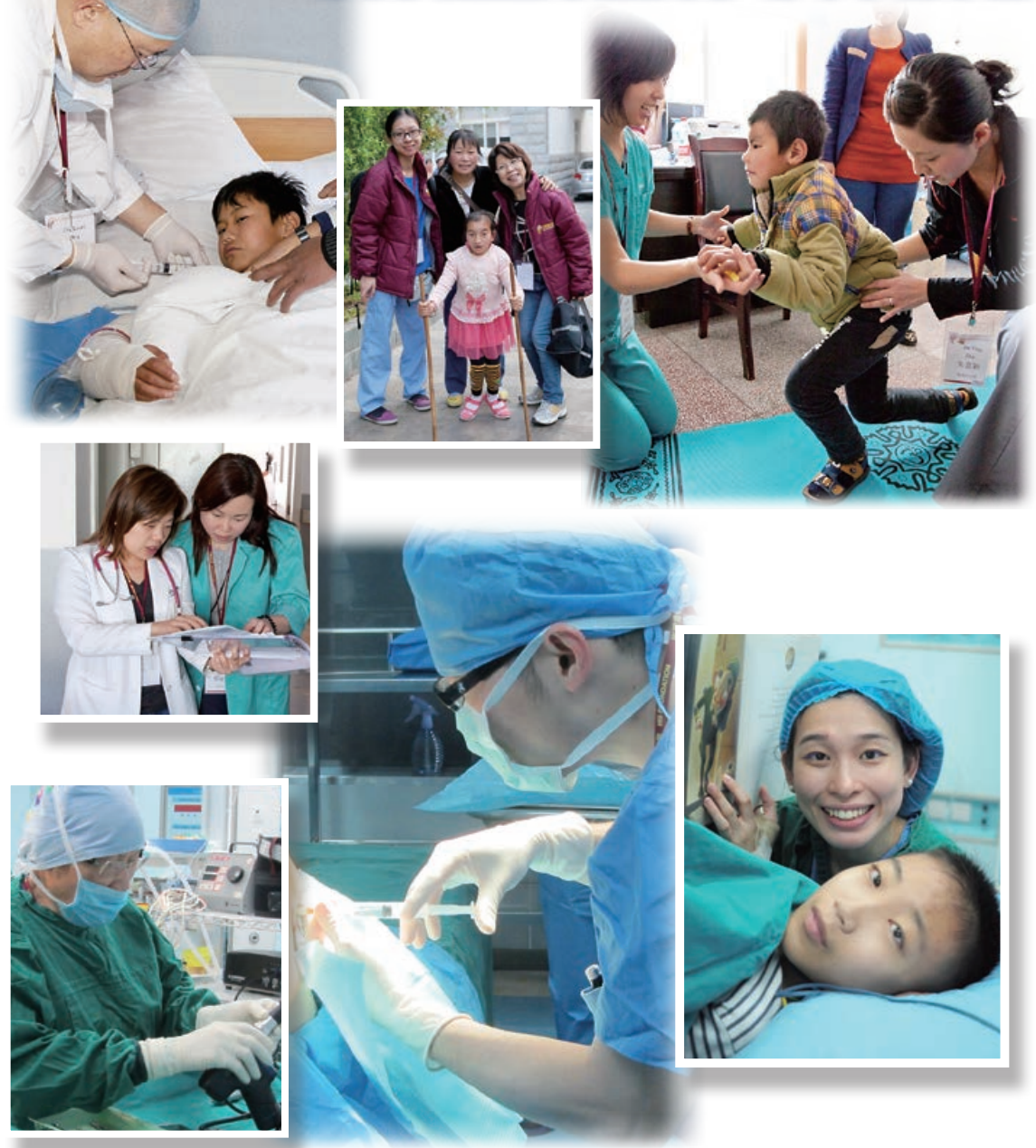輪椅捐贈紀錄

Wheelchair Donations Record

	日期 Date	地點 Location	數量 QTY
2006	10/22 to 10/29	河南駐馬店 Zhumadian, Henan	550
2008	5/18 to 5/24	河南沁陽 Qinyang, Henan	550
2008	June	四川 Sichuan	4400
2009	3/15 to 3/22	河南沁陽 Qinyang, Henan	550
2009	10/18 to 10/25	雲南大理 Dali, Yunnan	550
2009	10/25 to 11/1	河南駐馬店 Zhumadian, Henan	1100
2009	December	河南駐馬店 Zhumadian, Henan	30
2010	3/21 to 3/28	河南沁陽 Qinyang, Henan	550
2011	4/2 to 4/10	雲南永平 Yong Ping, Yunnan	550
2011	4/9 - 4/17	雲南大理 Dali, Yunnan	550
2011	5/15 - 5/22	河南沁陽 Qinyang, Henan	1100
2012	3/10 -3/17	雲南昆明 / 大理 Kunming & Dali, Yunnan	550
2012	5/13 - 5/20	河南安陽 Anyang, Henan	550
2012	9/2 - 9/9	河南沁陽 Qinyang, Henan	1100
2013	3/30 - 4/4	河南安陽 Anyang, Henan	550
2013	9/1 - 9/7	河南濟源 / 沁陽 Jiyuan/Qinyang, Henan	550
2013	9/2 - 9/8	河南安陽 Anyang, Henan	550
2014	5/18 - 5/24	河南安陽 Anyang, Henan	1100
2014	7/18 - 7/26	內蒙 Inner Mongolia	550
2014	10/12 - 10/18	河南濟源 / 登封 Jiyuan/Dengfung, Henan	550
2015	5/17 -5/23	河南汝南 / 蘭考 Runan & Lankao, Henan	1,100
2015	26/7-7/8	新疆巴州 Bazhou, Xinjiang	550
2015	9/13 - 9/19	河南沁陽 / 博愛 Qinyang, Henan	550
2015	9/13 - 9/19	河南武陟及解放區 Wuji (Qinyang), Henan	550
2015	9/13 - 9/19	河南新鄉 Xinxiang, Henan	550
2016	6/12 - 6/18	河南周口 Zhoukou, Henan	550
2016	6/27 - 7/2	河南汝南縣 Runan, Henan	550
2016	9/22 - 9/29	河南新鄉 Xinxiang, Henan	550
2016	10/23 - 10/29	河南西平縣 Xiping, Henan	550
2017	6/11 - 6/17	河南滑縣 Hua Xian, Henan	200
2017	8/2 - 8/8	河南駐馬店市 Runan, Henan	402
2017	10/15 - 10/21	河南泌陽縣 Biyang, Henan	500
2018	4/22 - 4/28	河南沁陽 Qinyang, Henan	200
2018	5/20 - 5/26	河南滑縣 Hua, Henan	500
2018	9/9 -9/14	河南駐馬店驛城區 Zhumadian, Henan	400
2018	9/16 - 9/22	河南駐馬店 Zhumadian, Henan	500
2019	5/20 - 5/25	河南蘭考 Lankao, Henan	500
總數			24682

手術隊員見證篇

Surgical Team Members Testimonies Section



改變生命的事工

A LIFE-CHANGING MINISTRY

關淑敏 物理治療師
May Kwan Physiotherapist

初次接觸天鄰基金會

2020 年，新冠狀病毒肺炎大流行，席卷全球，到 2021 年仍未有結束的跡象。有點吊詭的是當非典型肺炎於 2003 年在香港爆發時，是我認識及參與天鄰骨科隊的序幕。

從大學時期接受物理治療培訓以來，我一直在積極探索在中國服事的機會。畢業 6 年後，2003 年香港爆發的非典型肺炎為我打開了大門，讓我聯繫了天鄰的骨科隊。我從教會同工那裡得知了天鄰的事工，她是一位現職護士的天鄰義工隊隊員。由於香港非典型肺炎影響，香港的隊員無法前往工場，她不得不在短時間內由澳洲到河南加入天鄰的覆診隊。她回來後，給我帶來了天鄰的十週年紀念冊。讀完這紀念冊，我有了強烈的感動要成為天鄰隊員。雖然我不知道河南在哪裡，但我卻申請了 2005 年 3 月出發的河南駐馬店骨科隊。

2005 年 3 月，我被取錄為駐馬店骨科團隊的新隊員，我感到很興奮，但是當我發現我是團隊中唯一的理療師時，我變得非常緊張。在去河南駐馬店的路上，劉漢杰醫生和陳志偉醫生告訴我，我須要參與篩查病人是否適合手術。我的心怦怦直跳，因為我不知道工作程序以及如何“篩選”病人。

My first encounter with HIS Foundation

The Covid-19 global pandemic swept through 2020 and shows no sign of ending so far in 2021. Ironically, the SARS outbreak in Hong Kong in 2003 was the prelude which led me to the HIS Foundation orthopaedic mission.

Since I underwent physiotherapy training at university I was always looking for and actively exploring opportunities to serve in China. Six years after I graduated, the 2003 SARS outbreak in Hong Kong opened the door and paved my connection to the HIS orthopaedic teams. I learned of HIS ministry from my church co-worker, a nurse who had been serving HIS Foundation. She had to join HIS follow-up team on short notice as volunteers from Hong Kong could not go due to the SARS outbreak there. After she returned from HIS mission, she brought



作者（左一）與病人及醫療隊員合照。

Author (left) had photo with patient and medical team members.

我一直在澳洲悉尼的制度下修讀及任職物理治療的工作。我所認識的骨科大多是關節置換、骨科癌症手術和骨折相關手術，我也不是骨科物理治療師。我對天鄰短宣醫療隊所服事的病者狀況所知甚少。因此，在第一次出發參與天鄰骨科隊前，我努力地溫習骨科有關的疾病，及嘗試學習了一些基本的普通話。

從我第一次出隊到今天已超過十年，在天鄰骨科隊服事確實是令我大開眼界。許多在出隊中所接觸的病例及嚴重畸形的狀況，以往只是從教科書中簡單地了解到，在澳洲更從未聽過。

天鄰基金會骨科短宣是改變生命的服侍

讓我分享在天鄰骨科隊中三位病人的故事。

我在澳洲工作中遇到的脊柱裂患者，通常有幾種方法走路，能獨立行走、穿著支具、用拐杖或助行器行走，嚴重那些是坐在輪椅上。除了偶爾的骶骨壓瘡之外，我從未遇到過任何有嚴重壓瘡問題的人。

我在河南沁陽骨科有好幾天是負責支具覆診和篩查舊病人，一位當時只有 7 歲的女孩，患有脊柱裂。她走進來時，沒有穿支具，步伐只有輕微的異常。我最初的想法是只需要快速的覆查一下就可以了，但是我觀察到她看起來很傷心。由於語言障礙，我聽不懂她媽媽在說什麼。最後終於明白，我要她脫掉鞋子和襪子。她的腳外側緣有兩個很深的潰瘍，裡面塞滿了

me HIS 10th year anniversary memorial book. After reading the book, I had a strong conviction to become a volunteer. In March 2005, I applied for the orthopaedic team at Zhumadian in Henan province, even though I had no idea where Henan was.

As a first-time volunteer, I felt excited to be accepted for the orthopaedic team at Zhumadian; however, when I found out that I would be the only physiotherapist on the team, I became very nervous. On our way to Zhumadian, Henan, I was informed by Dr. James Lau and Dr. William Chan that I had to be involved in screening patients for suitability for surgeries. My heart was pounding as I had no idea what to expect or how to 'screen' patients.

I had had my physiotherapy training and had been working in Sydney, Australia. All I knew about orthopaedics were joint replacements, orthopaedic cancer surgeries, and fracture-related surgeries. I am not even an orthopaedic physiotherapist. I had no idea about the types of patient conditions on HIS trips. So I studied fanatically about orthopaedic conditions and diseases, at the last minute learning some basic Mandarin prior to my first mission trip with HIS Foundation.

Many of the conditions and deformities are either only briefly learned from textbooks or never heard of in Australia. Serving at HIS orthopaedic teams is an eye-opening experience, and that's true from my first encounter till today.

HIS Foundation orthopaedic mission is a life-changing mission

I would like to share the stories of three of our patients from my journey with HIS orthopaedic team.



昔日脊柱裂的女病人已是一位亭亭玉立的少女。

The spina bifida girl is now a beautiful young lady.

紙巾。我將她傷口內的紙巾一張一張慢慢地取出。傷口很深，我可以看到第五跖骨。我們的團隊非常關心她，立即安排她入院。在那次診治過程中，她進行了三次手術，包括清創術和清洗傷口。在上帝的祝福下，有一名從美國來的護士計劃在團隊離開後，在中國停留一段時間。他去了這個女孩家，不僅做了傷口檢查及包紮，還進行了家居教育，教她和她的家人關於傷口護理和預防未來傷口的破裂。女孩於2015年到門診來見我們，她已成長為一位亭亭玉立的美麗少女，在廣州工作。這一次，她的臉上多了些笑容，不再是悲傷的樣子。

Spina bifida patients that I had met in Australia usually were either walking without any aid, walking with braces, crutches, or a walker, or using wheelchairs, depending on the severity of their condition. I never met anyone with major problems from pressure ulcers apart from occasional sacral pressure ulcers.

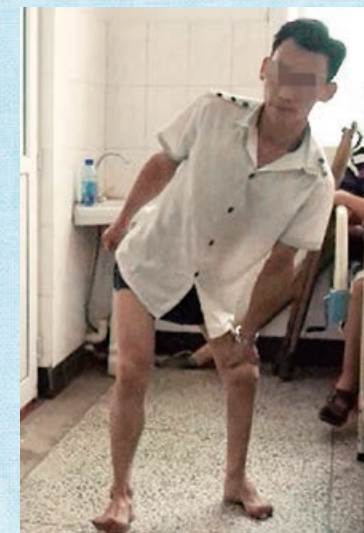When I reviewed and screened patients at the brace clinic at the Qinyang orthopaedic mission, I met a 7-year-old girl with spina bifida. She walked in with a slightly abnormal gait and without a brace. My initial thought was that she required only a quick screening visit; however, I observed that she looked sad. I could not understand what her mother was saying due to the language barrier. Eventually I managed to ask the girl to take her shoes and socks off. I found two deep ulcers on the lateral border of her foot stuffed with tissue paper. I slowly removed the tissues one by one from her wounds. The wounds were so deep that I could see the fifth metatarsal bone. Our team was so caring that she was admitted to the hospital immediately. She had three surgeries including debridement and wound cleanings during that trip. With the blessing from our LORD, one of the nurses from the U.S. would stay in China for a bit longer after the rest of the team had departed. The nurse went to this girl's home, not only dressing her wounds, but also providing community education to teach the girl and her family how to care for the wounds and how to prevent future wounds. The girl visited our outpatient follow-up clinic in 2015, and she grew up to become a gorgeous young adult who now works in Guangzhou. Today she has a smile on her face and no longer looks sad.

What a change in her life after all that care! In hindsight, if she had not come to the brace clinic

這次的經歷後，她的生命確是有很大的改變！事後回想，如果她沒有來支具覆診或沒有醫療隊的照顧及手術，到現在她還能走路嗎？她可以離家工作嗎？她的臉上會掛著笑容嗎？

好幾年後，我遇到了一位25歲的男子，他年輕時感染了脊髓灰質炎（小兒麻痺症）。他長大後左腿非常軟弱及畸形。他每走一步，都需要彎腰用手按著左膝支撐才不會倒下來。

當我第一次見到他時，他已經接受了左腿矯形手術，顯然他的手術傷口仍很痛。他看起來很“酷”，所以使我感到很難與他交談。然而，他對康復運動的安排非



兒麻後遺病者手術前需要手按著大腿才能够走路。

Post-poliomyelitis patient had to use the left hand pressed onto the thigh for support on weight bearing.

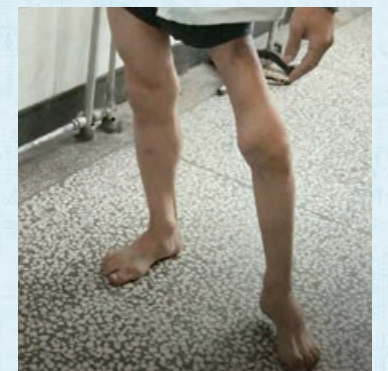or if the team had not taken care of her during her admission and her education afterwards, would she still be able to walk? Would she be able to work away from home? Would she have a smile on her face?

Later on, I met a 25-year-old man who contracted poliomyelitis when he was young. He grew up with severe weakness in his left leg. When walking, he needed to bend down with his left hand pushing and supporting the left knee on every single step.

When I first met him after he had had surgery on his leg, his surgical wound was causing lots of pain. It was difficult to engage in any conversation with him, as he appeared very 'cool'! However, the man was extremely compliant with the rehab program. Most patients did not want to see a physiotherapist in the early days after an operation, but this man never declined any physiotherapy sessions. He demonstrated great pain tolerance during all the rehab mobility and exercises. He had to lie on his stomach for

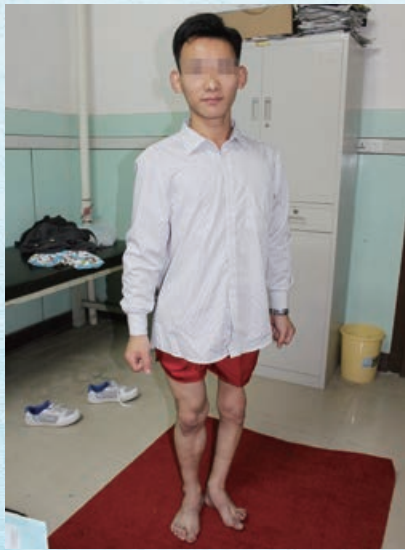

病人走路姿勢。
Patient's gait.



病者大腿肌肉萎縮，膝關節不能完全伸直。

Patient's left thigh is wasted, and the knee joint cannot be fully extended.



手術後，左膝能够完全伸直。

Patient is able to stand with the left knee in full extension.

常合作。大多數患者在手術後的初期都不想見物理治療師，但他從未拒絕過任何物理治療療程。在所有康復活動和鍛鍊期間，他忍痛力很強。手術後，他每天需要趴著躺下幾個小時，但他遵守了所有的指示，沒有任何抱怨。

第二年，我有機會訪問及錄影他走路，在走樓梯已不需要扶手，上落自如。採訪過程中，看了他術前走路的錄影，我才體會到他以往面對腳的畸形和行動不便，是多麼痛苦。

我見證了他變成另一個人。他可以昂首挺胸，顯得平易近人，充滿自信，生活上有一份不錯的會計工作，而且很快將要結婚了。他對自己的新生命滿有感恩的心，我反思時明白到是上帝給了我們一個機會，成為祂醫治的工具，不僅是身體的醫治，亦是一個全人的醫治。



手術後一年，病人可以只用左腳站立。

One year after surgery, patient is able to stand on the left leg alone.

many hours during his post-operation regime, but he adhered to all the instructions without any complaints.

The following year, I had an opportunity to interview him. I watched a video of him walking, and he showed an amazing ability to navigate stairs without grabbing the rail, using a reciprocal gait. During the interview and after reviewing the video how he walked before the operation, I came to realize just how much he had to suffer and endure because of his deformity and the difficulties with mobility it caused him.

I witnessed this man become a different person. He could now keep his head up, appeared very approachable and full of confidence, with a good job in the accounting field, and was soon to get married. He was grateful for his new life. I reflected that God was giving us an opportunity to be HIS vehicle of healing, not only physical healing, but also a whole-person healing.

近年我們在伊拉克北部的庫爾德斯坦開始了骨科團隊工作。在庫爾德斯坦的難民營內，有許多雅茲迪難民住在帳篷裡。他們是在2014年被伊斯蘭國（ISIS）種族屠殺的倖存者。這些難民遭受了巨大的創傷，若有殘疾的情況就更糟了。在2019年，我遇到了一個雙腳嚴重馬蹄足的女孩，但是幾乎不可能與她進行任何交談。顯然，她



一位庫爾德斯坦的雅茲迪女子，患有嚴重雙側先天性馬蹄內翻。

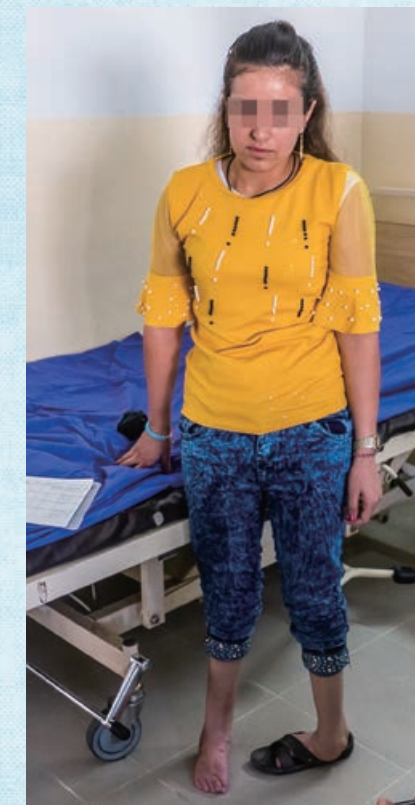A Yazidi lady in Kurdistan was suffering from bilateral congenital clubfoot.



雙腳嚴重變形，站立時用腳的背部負重。

Both feet were severely deformed. Patient was bearing weight on the dorsum of her feet on standing

In recent years, we commenced an orthopaedic team in Kurdistan, Northern Iraq. Many Yazidi refugees lived in tents inside displacement camps in Kurdistan. They were survivors of a genocide carried out by the Islamic State group back in 2014. These refugees had endured tremendous trauma, a situation made even worse by disability. In 2019, I met a girl with severe bilateral club foot. It was almost impossible to engage in any conversation with her, and, apparently, she also suffered some sort of somatosensory symptoms which made the process of rehabilitation even more difficult and complicated. On the first two visits, my heart went out to her because the emotional pain she had experienced was beyond my imagination. I had been learning to be gentler with her during rehab trainings, and I tried to encourage her during physiotherapy sessions. Her last visit in December 2019 was with a follow-up team for



第一次手術後，右腳已經矯正。

The right foot was corrected after the first operation.



兩次手術後，雙足已經矯正，可以穿鞋子走路。

After two surgeries, patient's feet are corrected. She is able to wear shoes on walking.

亦患有因創傷引致的某種軀體感覺症狀，這使整個康復過程變得更加困難和複雜。在前兩次出隊遇見她時，我內心為她難過，因為她那麼年輕又經歷這樣的情感痛苦，是超出我能想像的。我一直嘗試在對她的康復訓練中比較溫和，並在理療期間嘗試鼓勵她。在2019年12月一個短期覆診隊，要在數天內為兩個月前手術病人進行密集式康復鍛鍊。這次我終於看到了她珍貴的笑容，不止一次，而是多次。我猜想，她身體上的改善可能讓她從生活中所經歷創傷和困難中，獲得了希望。

我能夠參與及見證上帝透過天鄰骨科隊短宣事工，改變了許多人



病人收到紀念品，心情開朗。

Patient was happy on receiving a souvenir.

patients who had had surgery to receive intensive training for few days. Finally, I saw her precious smile, not only once, but on multiple occasions. I guessed that her physical improvement might have given her some hope out of all the trials and trauma in her life.

I am so blessed to have witnessed the many lives changed through HIS orthopaedic missions. These people were once neglected by society and looked down upon by others. But amazing changes in their lives occurred through God's mission to them. Thanks to God's love and mercy towards people. To participate in HIS orthopaedic missions is, in a way, to form a partnership with our Almighty God. I am extremely blessed in witnessing this life-changing ministry. These are humbling and joyful experiences in my life.

From a personal perspective, my life has been changed through HIS ministry. First, I had to overcome my biggest barrier. I do not enjoy long-haul flights, as I experience motion sickness on flights longer than four hours. Nonetheless, it was unbelievable that I was able to take a 26-hour, one way trip to Kurdistan, three times within a year!

的生命，是上帝給我的祝福。這些病人曾經在社會上被忽視，被人們看不起。透過上帝差派祂僕人的服事，她/他們的生命起了很多驚人的變化。感謝上帝對人的愛和憐憫，我們藉著參與天鄰骨科短宣隊，得以與全能的上帝合作，我有幸能見證了這個改變人生命的事工。這些都是令我謙卑和喜樂的經歷。

從個人的層面來看，我的生命也因著天鄰的事工而改變。首先，我必須克服我最大的障礙——我不喜歡長途飛行，因為每每飛行時間超過四個小時，我就會出現暈車症狀。儘管如此，令人難以置信的是，我能夠在一年內進行了三次26小時的庫爾德斯坦旅程！

其次，在骨科隊中遇到很多病

Second, many of the patient conditions we encountered in our orthopaedic teams were not the conditions I had been dealing with in my everyday work. It certainly opened my eyes to realise that the needs are tremendous, but I also learned how to problem-solve with limited resources and by thinking creatively.

Third, I met many volunteers from all over the world. A number of them have become my good friends, serving together with the same faith, same objectives, and same desire. We all are looking forward to seeing smiles on our patients' faces as well as bringing a smile to God's face through service.

We are responding to HIS calling and committing to partnership in HIS plan. As Roman 8:28 says, "And we know that in all things God works for the good of those who love him, who



庫爾德斯坦手術隊隊員在醫院大樓前合影。

Surgery team members had a group photo in front of the main building of the local hospital.

人的狀況，並不是我在日常工作中遇到的。這無疑讓我大開眼界，意識到這世界的確有很大的需要，我同時也學習到如何利用有限的資源來解決問題，並跳出框框思考。

第三，我遇到了很多來自世界各地的同工，其中一些已經成為我的好朋友。我們都懷著相同的信念、相同的目標和相同的願望一起服事。我們都期待看到我們的病人臉上洋溢著笑容，也期待著在服事中讓上帝的臉上露出笑容。

我們只是回應上帝的召命，並委身在上帝的計劃中，與上帝同工。正如羅馬書 8:28 「我們知道上帝使萬事一同效力，讓那些愛上帝，又按他旨意蒙召的人得益處。」在許多地方公開宣講福音是不容易的，甚至不被允許。然而，上帝的計劃和祂的工作是不受限制的。我祈禱主耶穌基督的愛，透過隊員的生命成為活的見證，讓我們所遇到或服事的每一個人都能感受到。

have been called according to his purpose.” It is not easy and sometimes not even allowed to openly proclaim the Gospel in many places. However, God’s plan and HIS work are not restricted. I pray that Jesus’s love spreads widely through the lives of our volunteers and to every individual we meet or serve.



在資源短缺的情況下，常常找到特別的解決方案。把拖鞋加在鞋子底部就可以加高鞋子。In face of shortage of supplies, creative ideas can be found for problem solving. By adding a slipper onto the bottom of a shoe, a shoe lift is created.

庫爾德斯坦手術隊成員合照。

Group photo of team members of Kurdistan Surgery Team.



主愛福澤 Jesus' Blessings

吳迪生 麻醉科醫生
譚瑞玲 中文翻譯

天鄰基金會的醫療宣教隊的事工，是主耶穌的大愛遍蓋各地病人的福澤。

世上很多受疾病折磨的病人可能早被遺忘棄置，但主耶穌絕不輕看。通過天鄰的醫療服務，祂看顧了這些病者的肉體需要。奉主的名，天鄰為病者帶來逆轉生命的肢體矯正、面頰整型及灼傷重整等手術。

主耶穌傾覆之愛不但觸動病人的心靈，更令家屬深為感動。我見證著天鄰同

Dickson Wu, MD Anesthesiologist

HIS Foundation's medical mission trips have been an extension of Jesus' love to indigent patients around the world.

Many of the patients are forgotten by others, but not by Jesus. By treating their physical needs with medical care, Jesus' love for them is made manifest. HIS Foundation has done much life-changing work in the name of Jesus, correcting extremity problems, facial problems, and burns.

The love of Jesus affects not only the patients but also their families. I am amazed at the scope of the interactions among the teams, the patients, and the families; I see the love and the joy in having their physical needs met and knowing the presence and love of the Lord is there.

I recall one incident that shows God at work in HIS Foundation. We had a patient who had a cardiac arrest in the operation room; he went into asystole (no heartbeat) for an unknown period of time. We prayed that he would come back with cardiopulmonary resuscitation (CPR). God answered us, Praise God!



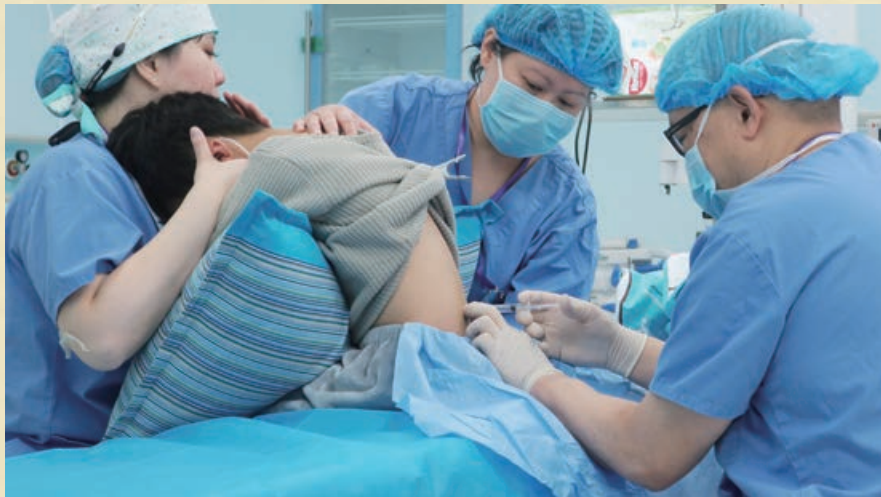神眷顧的孩子。

A child blessed by God.

His heartbeat was restored, but when he awoke, he was a little sluggish for a

作者在施行脊髓麻醉。

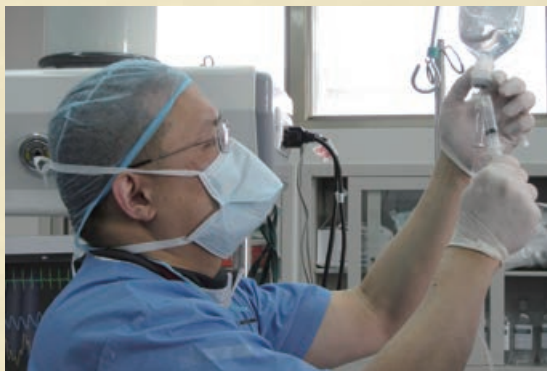Author was performing spinal anesthesia.



工對病者和家人的關懷憐愛，令他們不但身受醫治，也經歷到神愛的臨在。

我猶記得神恩手賜醫治大能的一件感人往事。那時一位天鄰病人在手術室中突然心臟驟停，沒有了心跳一段時間。我們立時禱告，祈求主在我們施予急救後能挽回病人的性命。

神果真回應了我們的祈禱，感謝讚美主！病人的心跳恢復了。可是，他的反應有點遲緩，我們及病者家人都擔心會是腦部受損的後遺症。我們整個團隊都投入禱告，再次懇求神的憐憫和醫治，神也再次回應了我們所求，病人不但最後無恙，還是班上最聰慧的孩子（見圖）。他的家人亦由當初的憤怒轉為欣慰，並且對我們的醫療服務滿心感謝，充滿著喜樂。自始，



while. We worried about this, and so did the family, about whether the boy would experience any residual effects, like brain damage. Our whole team prayed to God, and God answered our prayers.

As it turned out, the patient was fine; in fact, he became one of the brightest pupil in his school class (see photo). His family went from anguish to joy; they were extremely grateful and happy.

In the following years, the boy came for subsequent surgeries, and today he is a fine-looking young man. This was a miracle of God's healing! Thanks be to God!

Many surgeries are miracles: when people can walk who could not walk before or use their hand when they could not do so before, or when they look different than before. This miracle

作者工作情形。

Author is working.



作者（左二）與醫療隊隊員在大理第二人民醫院內合照。

Author (left second) had photo with other medical team members at the Dali Hospital.

reminded me that I have to totally depend on God for everything, as we could do nothing but pray and ask God for his mercy and grace and help. And He was merciful to us, thank God again!

I feel as long as we are willing to serve God and do our best with His love for others, He will watch over us and bless our work as we yield things to Him. People coming to know the Lord, experiencing His love, witnessing medical miracles, delighting in interacting with others, rejoicing in the Lord: this is what HF is all about.

We hope to continue God's work, show the Love of Jesus and praise Him and thank him for all He has done.

他連續在幾年間再接受多項手術，如今他已長大成一位俊美少年了。真是神偉大的奇蹟！滿心讚美主！

上主賜予天鄰病人的神蹟何其多，不少人本來是癱腿用手爬地的，現在卻站起來走路，翻了人生之篇。但是神在上述病人所行之奇蹟，在在提醒我凡事靠主而成，單靠己力只會一無所就，藉著向祂的祈求，助力、憐恤、恩典沛然降下。神如此恩待我們，怎不再三歌頌主恩！

我深信只要我們擺上，藉神之愛盡全力服事他人，並全然依仗祂，祂定必看顧，保守我們的事工。

天鄰的事工就是：認識神、經歷祂、醫療神蹟、各人喜樂的互動、主內的喜樂。

祈盼我們能繼續作主工，彰顯神的愛，滿心讚美和感恩祂所作的美事。

充滿喜樂的事奉

Joy in Serving

孫枝潔 天鄰隊員

Grace Yeh HIS Foundation Volunteer
Translation by James Lau

2009 年 10 月初剛從洛杉磯退休搬到中國雲南的大理時，在美國的麻醉科醫生吳國威先生就邀請我參加 10 月底在大理州永平縣的醫療事工，我欣然接受。那時是參加組裝輪椅贈予殘疾患者的工作。當時對天鄰的醫療事工還不甚瞭解，只知道所有的組員都是志願自費參與的義工。看到每位

In October 2009, I retired from my job in Los Angeles and moved to Dali, Yunnan. Dr. Stephen Eng, an anesthesiologist in the United States, invited me to join a medical mission team to be held in Yong Ping Province, Dali, at the end of October. I gladly accepted the invitation. My duty was to assemble wheelchairs for donation



作者（前坐）與病人和母親（後中、左）及天鄰護士（後右）在大理醫院合照。
Author (front) had photo with a patient (second row, center), the mother, and a nurse (second row, right) at the Dali Hospital.

義工每天都盡心盡力的把輪椅組裝完美，尤其是在贈送輪椅的那天，看到患者及家屬又歡喜又感激的帶走輪椅時，心裡是又憐惜他們、又感謝天父給我這樣的機會能服侍他們，這就堅定了我繼續服侍的心。沒想到當年劉醫生就問我是否可能幫忙找到更多可服侍的患者，那時我就想，我在一個人生地不熟又初來乍到的地方，去哪兒找機會呢？

我不能，神能！

在 2010 年初，透過一位鋼琴老師 Mari 介紹了她學生的父親（是在昆明的醫生），再通過由這位父親介紹的大理醫生，輾轉認識了殘疾人聯合會（國家幫助殘疾人的機構）的副理事長。奇妙的天父將所有的不可能都變成可能！從此天鄰就順利的在大理的 12 個縣展開了 10 年的醫療義診！

在服侍中遇見神

（一）在醫院中

當地的醫院由最初的不適應，到後來完全無條件的配合。院方不單單

to handicapped people. At that time, I knew very little about HIS Foundation. I only knew that all team members were self-funded volunteers.

I saw how the volunteers tried their best every day to ensure the wheelchairs they assembled were perfect. I witnessed the joy and appreciation among the patients and families when they received the donated wheelchairs. My heart also filled with pity for the handicapped people. I thanked God for this opportunity to serve Him, and the experience strengthened my desire to serve. Unexpectedly, Dr. Lau asked me if I could find more handicapped people who needed help. I had just arrived in Dali, I thought, and I knew very little about the place. Where could I find disabled people?

I cannot, but God can!

In early 2010, Mari, a piano teacher, introduced me to her student's father, a doctor in Kunming. This father, in turn, introduced me to a doctor in Dali and the vice president of



作者（右）與天鄰護士合照。
Author (right) had photo with a HIS Foundation nurse.

提供了場地（門診、病房、病床、手術室、辦公室），醫療人員也從天鄰學到了怎麼真正的關心病患及家屬。感謝天父，這是祂作的工！

（二）在患者身上

1. 四忠——他是一位小兒麻痺的少年（圖 1），在地上爬著走了 18 年，靠著天鄰的幫助站了起來！他開了一間小小的雜貨舖，結了婚，生了個健康的兒子！當孩子滿月我去探望時，他說：「葉老師，你看，我兒子的雙腳是健壯的！」感謝天父！



圖 1
Photos 1

一位手術後的小兒麻痺病人，帶著健康的孩子及家人回來覆診。

A post-surgery poliomyelitis patient return to clinic with his healthy son and other family members.

Association for Handicapped People. What a wonderful way that God made things happen! This started the ten years of free medical services in Dali that served 12 provinces.

I met God during the services

(1) In Hospital

Initially, the local hospitals were not used to the practices of HIS Foundation. Later, they cooperated whole-heartedly. They provided the clinics, wards, hospital beds, operating rooms, and offices. They learnt from HIS Foundation how to care for the patients and their families. Thanks be to God; this is HIS work.

(2) With Patients

(a) Si Zhong. He is a young man with poliomyelitis (photo 1). He had been crawling for 18 years. After surgeries provided by HIS Foundation, he was able to stand up! He opened a small store, got married, and had a



作者（左）接受感謝證書。

Author (left) received a certificate of appreciation.

般。我感謝天父！我想天父是要讓她知道，她不是多餘的，她是神所保抱的！

（三）在隊員間

我從一開始就發現天鄰的隊員是那麼的不同！每個人（醫生、護士、行政）不單是用自己有限的假期、自費來到陌生的地方，又在神的面前，全身、心、靈甘心樂意的擺上！而且最讓我感動的是，雖然每天大家都是超時、超體力的在工作，但隊員之間就像家人一樣，互相安慰、鼓勵，每早為手術病人禱告，每晚為一切感恩。真的是一個在地如在天的大家庭之感受！

我深願天鄰的事工能夠有更多屬神的兒女加入，不單是幫助了有需要的人，也能夠在服侍中，享受神的同在及在屬神家庭中的喜樂！

healthy son! I visited Si Chung when his child was one month old. He said to me, "Look at my son, Ms. Yeh, his legs are strong!" Praise the Lord!

(b) Duo Yu (meaning leftover). She is an elderly lady with leprosy. When I saw her at the leprosy rehabilitation village, she had a gangrenous leg which emitted a strong, foul odor (photo 2). A surgeon from HIS Foundation performed an amputation. However, due to bedsores, Duo Yu had to stay in the hospital for a long time. When I visited her in the hospital, and she said that I was like her daughter. Thanks be to God. I think God wants to let her know that she is not a "leftover." She is someone God loves.

(3) Among Team Members

From the very beginning I noticed how HIS Foundation members were different. Everyone (doctors, nurses, administrators) was self-funded and used his or her vacation time to come to a strange place to work. They served with all their might, all their hearts, and all their souls! What impressed me most was that despite the overtime and hard work, the team members behaved like family. They encouraged and comforted each other, and they prayed for patients every morning. They also gave praise to God every evening. It was like a heavenly family living on earth!

I wish that more brothers and sisters would join HIS Foundation and serve together. Their service would help those in need. In addition, they would experience the presence of God and the joy of a spiritual family.

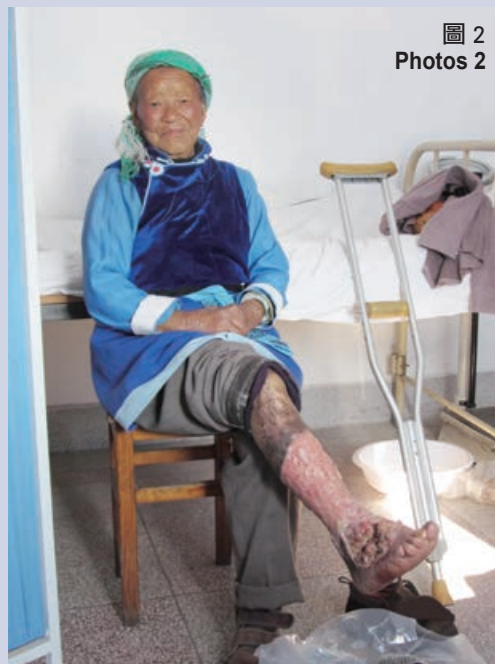

圖 2
Photos 2

一位右腿壞疽和潰瘍的年長村婦。

An elderly lady villager with ulcer and gangrene of the right leg.

天鄰事工——有福的事奉

Serving in HIS Foundation – A Blessing

蔣蘭芳 物理治療師

Lan Fong Chiang Physiotherapist
Translation by James Lau

我是 2003 年便開始參與天鄰在中國的醫療工作！

回想天父常在當中，讓我深深體會祂對我的愛和計劃。從小對生活沒有太大要求，感覺人生沒什麼意義，所以也不想重複爸媽每天辛勞地只為著糊口！既不想讀大學也不想工作，就想到去台灣生活，大概也受著當時的文藝小說所影響！最容易去的方法就是升學，在找資

Since 2003, I have been a member of the HIS Foundation's medical services team in China. As I think back on my experience, I can deeply feel God's love and plan for me.

I never had big dreams when I was young, and I felt that life was meaningless. I certainly did not want to live as my parents had to, working hard the whole day just to earn enough for food. I did not want to go to college, nor did I want to work. However, I did want to live in



作者（左二）與醫療隊員探訪雲南的病人。

Author (second from left) and other medical team members visiting a patient in Yunnan Province.

料時發現有一個科目是物理治療，我好像找到了人生的方向，也是第一次有這樣大的渴求想得到一樣東西，我居然向神說如果你賜給我想要的，我就會相信你的（當時還未信主）。

天父真的讓我可以到台灣升讀物理治療，大學的生活很充實很有趣，但我心靈仍然很空虛，一年過去，我再向神禱告，如果祂是真的，請讓我認識祂！奇妙的事再發生，不久我就透過一個陌生人分享四律而信主，我的生命也因此變得不一樣！

當初我計劃畢業後留在台灣，結果神讓我回到香港；我一直很不喜歡中國，結果神卻讓我漸漸喜歡上這片地土。祂透過不同的方法讓我接觸中國的農民和學生，官員或醫護人員，令我對中國人有更多的愛和認同，也認識了天鄰基金會，過程中讓我體會祂有多愛我們這些微小的受造物，不分國籍和身份！

第一次河南的出隊當然是最震撼的，包括隨隊帶去的大量醫療物資、與當地官員的接觸、數以百計的病人、殘障的嚴重、我們經驗和能力的缺欠……，還有來自五湖四海的弟兄姊妹，每年都讓我再一次的經歷祂的愛和信實！

這些年主要去河南安陽、駐馬店、沁陽，雲南大理和永平，四川瀘州等地。看著神怎樣揀選一些領袖，帶領大家在不同的地方展開醫療工作，我深受感動！我主要是參加美國天鄰基金會的醫療隊，當中要感謝劉醫生忠心回應神的帶領，

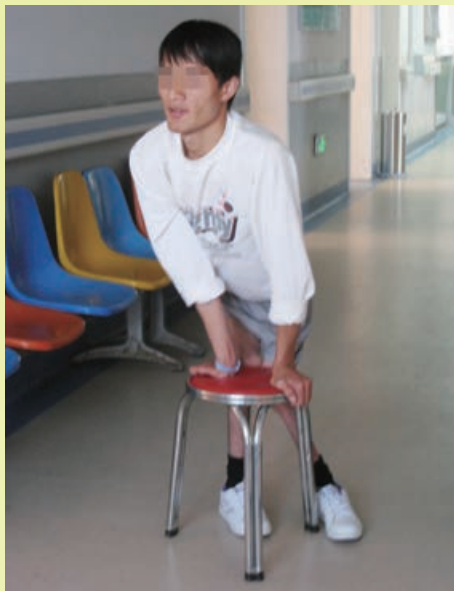Taiwan. Maybe this desire came from what I read in novels. The easiest way to go to Taiwan was to attend college, so I searched for subjects to study, and I came across physiotherapy. This interested me and gave me direction. For the first time in life, I wanted to achieve something. I prayed to God, imploring Him to grant my wish. If He did, I would believe in Him (at that time I was not a Christian).

God answered my prayer! While the study of physiotherapy was interesting, I still had a sense of emptiness. A year passed, and I prayed to God again. I asked God to let me know Him. Then something unexpected happened. Soon after my prayer, I met a stranger who explained the four spiritual laws to me. After this encounter, I believed in God, and my life forever changed!

My initial plan was to stay in Taiwan after graduation. However, God guided me back to Hong Kong. Although I had never liked China, God used different means to let me get in touch with peasants, students, government officers, and medical professionals from China. I also learned about HIS Foundation. I gradually developed an identity as Chinese and even came to love China. This change let me understand God's love for us even though we are small and insignificant. God's love transgresses all nationality and personal identity.

The experience of my first mission trip with HIS Foundation was overwhelming: the quantities of medical supplies we brought, the many government officials and medical professionals we met, the hundreds of patients, including severely handicapped patients, all pushed the limits of our experience and ability..... but also the many brothers and sisters from different parts of the world. Since then, I love to join HIS

他常常要比大家多辛苦一點，又要敏銳神的帶領，從零開始，尋找適合又願意合作的醫院，當中遇到的困難一定不少。例如和醫院磋商可行性 and 細節，招募義工，購買儀器物資，還有許多細節上的考慮安排，讓行程能夠順利，甚至要預先找出一些病人，讓醫療隊可以在有



一位小兒麻痺病人，不能站立，用凳子支持身體，慢慢把凳子推前移動。

A post-poliomyelitis patient was unable to stand. He used a stool to support the body and moved forward by pushing the stool.

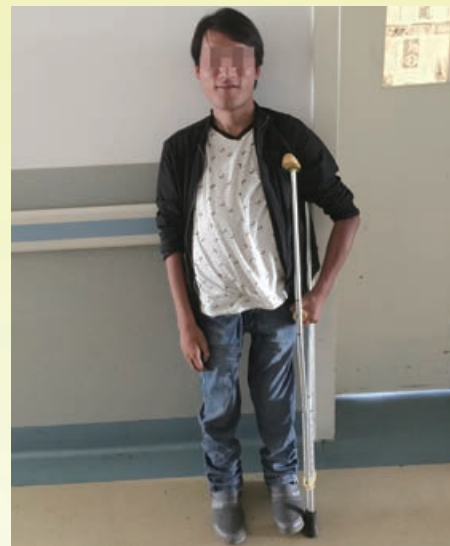

Foundation missions every year to experience God's love and faithfulness.

We were in Anyang, Zumadian, Qinyang, Dali, Yong Ping, and Luzhou. I felt deeply moved as I witnessed how God selected leaders to develop medical services in different places. Most of the time, I joined the United States team of HIS Foundation, and I appreciated Dr. Lau's faithful responses to God's calling. He worked harder than other team members and displayed keen leadership. Starting from ground zero, Dr. Lau overcame many obstacles as he searched for hospitals willing to cooperate with us. He negotiated with the hospitals to determine the details of contracts and the workflow. He also recruited volunteers, purchased medical equipment and supplies, and set the itinerary. Dr. Lau found patients, and he let the medical team maximize its time to treat as many patients as possible. All the efforts put in by Dr. Lau and others touched me deeply, and I treasured the opportunity to serve on the medical teams. I understand that many brothers and sisters must work hard to make the team successful.

I can recall many happy moments. Every year on follow up, I witnessed the improvement of our patients. Some who had been unable to walk were now walking. Some needed the support of braces or walkers, but others were able to walk independently, and some patients even walked normally. I could see the great benefits that medical treatment brought to these poor peasants living in the villages. Indeed, some of our patients had improved so much that they had already left the villages to work elsewhere and did not return for follow up.

During a mission trip, my daily routine includes participating in ward rounds and out-



手術後病人可以站立並且用一支拐杖走路。

The patient was able to stand after surgery. He was able to walk with a crutch.

限時間內處理更多有需要的病人，這都讓我深受感動，更珍惜每一次出隊的機會，因為背後有著同工和弟兄姊妹更多的付出。

開心的事很多，每年覆診都會遇到，看見病人從不能走路或走路困難，透過手術矯正或加上支具及助行器，可以自由行動，甚至行動接近正常，對生活在農村或貧困的人更是重要！也有不少病人甚至因為出去打工不能來覆診呢！

出隊每天的生活：門診或巡房看病人，等待病人完成手術，為困難的手術或手術不順利時禱告主，每天完成工作後可以好好一起吃晚飯，之後的分享和禱告會……，主日到教會崇拜，下午去旅遊，離別前與當地醫院員工的晚會和病人的惜別會都讓人難忘，很多時候都會觸動大家……

patient clinics, waiting for surgery patients to return from operating rooms, praying for difficult surgeries or surgeries that did not go well, enjoying a good meal with our team members after a day's work, sharing and prayer in the evening, attending church worship on Sunday, venturing out on local sight-seeing trips on Sunday afternoons, banqueting with local medical staff, and saying farewell with our patients. All these activities warmed my heart.

One vivid memory I have is how the Qinyang Hospital lacked elevators, so the families of different patients worked together to carry a patient on a mattress up and down the stairs to the operating rooms. This was a pathetic moment.

I went on home visits in remote areas in the Province of Yunnan. I also visited patients in a leprosy village, an unforgettable experience. Many of these patients lived up in the mountains. The roads were winding and difficult, and during the car ride of almost an hour I did not see any inhabitants. I know many patients had difficulties

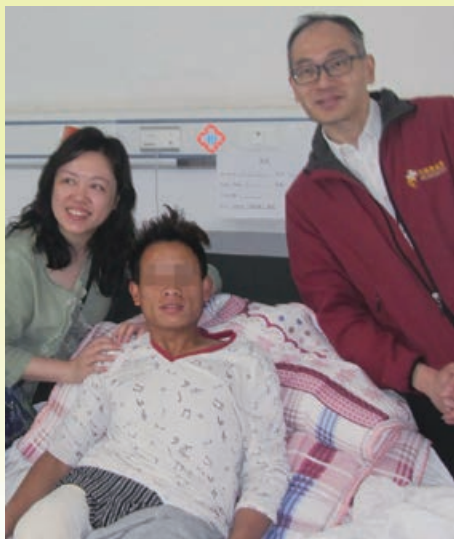

家訪一位雲南的病人。

Home visit of a patient in Yunnan.

特別的還有沁陽醫院是沒有電梯，手術前後都需要不同家屬合力抬著病人連著他的床褥上落樓梯來回手術室。

我們曾到麻瘋村探訪麻瘋病人，也曾經去雲南省永平縣探訪手術後的病人，他們住在山上，車子在山上也行了數十分鐘時間，放眼也沒有鄰居，想起曾經有不少病人因為不良於行而沒有有機會落山看病，更懸念到有不少還比較貧困和殘缺的病人，我們尚未有機會接觸！當日在庭園遠處便看到我們這位十多歲的小病人，她身形瘦小不良於行，只能坐在小凳上過日子，因為腦癱讓她活動緩慢，她也似乎沒有意識要趕走那些蒼蠅，手術雖然改善她行動的能力，但她面對的困難仍很大，庭園內高高的梯級及門檻，連扶手也沒有，也象徵她人



作者（左一）與病人及張宏恩醫生合照。

Author (Left) had a photo with an amputee and Dr. Warren Cheung.



醫院沒有升降機，病人家屬與醫護人員合作搬運病人。

The hospital has no elevator. Patient's relatives and medical staff worked together to transport patient.

in walking and thus could not come down the mountains to seek treatment. Unfortunately, I believe we were not able to reach out to some of these handicapped patients.

I also remember seeing one of our patients, a teenager with cerebral palsy. Slim and weak, she sat on a small stool most of the day due to her difficulties in walking. Numerous flies gathered around her head, but she did not bother to drive them away. Even though surgery improved her walking, the girl still faced many challenges. The doorstep was high, and the stairways had no handrails, symbolizing the struggles she faced every day. May God have mercy on her.

I frequently had opportunities to see patients in the clinics and before their surgeries. I saw many patients with disabilities. Some had become seriously handicapped from poliomyelitis. Their mental status was normal, however, some had to crawl on the ground, losing the dignity of a human being. After

生每天遇到的困難，求主親自幫助她！

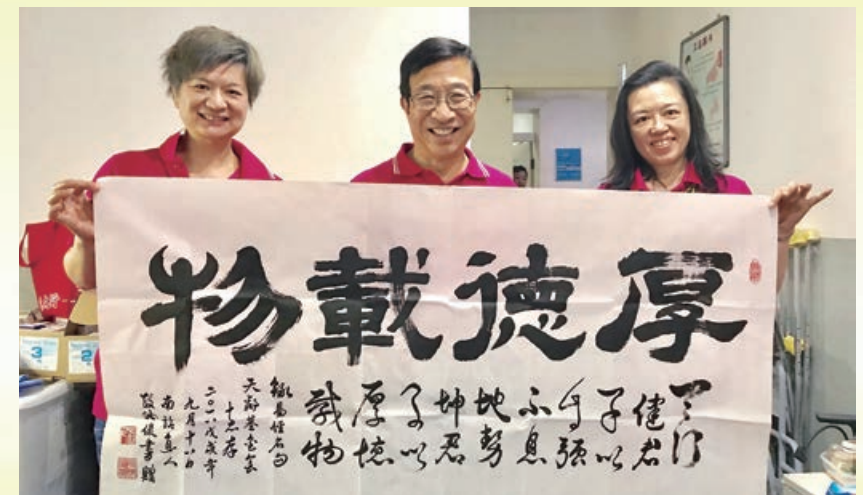我常常有機會在門診和病人手術前已經見到他們的殘障，有不少嚴重的殘疾是由於小兒麻痺症，他們智力正常，卻因肢體殘廢甚至在地上爬行，失去人的尊嚴，他們透過手術改善很大，可以自己行走，嚴重的情況就需要支具及拐杖幫助。

曾經有一個小病人的分享一直感動我，他說他不敢和哥哥吵架，因為怕他不肯背他上學，因為他不能走路。小小年紀已經沒有任性的自由，反觀自己卻任性又自我，如果我換作他的處境……

想到能夠去幫助別人，而不是受他人幫助，實在是何等幸福和蒙恩，我要更珍惜和分享擁有。近年中國已收緊政策，我們可以工作的空間減少了，加上疫情，再到中國的機會更渺茫，若神許可，我仍然希望天鄰可以繼續中國的醫療工作，也希望神容許我繼續參與，求主祝福！也願主祝福大家！

作者（右一）與醫療隊員接受病人贈送字畫。

Author (first from right) and medical team members accepting a gift of Chinese calligraphy from a patient.



surgeries, their conditions were much improved. Some walked independently while others used crutches and braces during ambulation.

A story from a boy who was unable to walk touched me deeply. He said he never quarreled with his older brother because he feared that his brother would refuse to carry him to school. This boy could not afford to be capricious. Thinking about myself, and how obstinate I was, I don't know what I would have done if I were put in that poor boy's position.

Today I know that providing help rather than receiving help is fortunate and a blessing. I treasure such opportunities. In recent years, as China tightens its policies, the room to serve in China gets smaller. And as the pandemic wages on, the chance for future medical missions in China shrinks further. If God is willing, HIS Foundation medical teams may continue to serve in China. I hope that I will be part of the team again.

May God bless all of you!

臨別「中」依依 Reluctant to Part

陳慧萍 病房護士

Doris Chan Ward Nurse
Translation by James Lau

近日我選擇告別一個我工作了差不多 34 年的醫院，原本以為自己一轉身就此告別，不用也不再回頭。說了再見、慶祝也完畢，我卻仍然戀戀不捨地一再回去。我問舊同事，我是否「陰魂不散」？這刻，我突然想到我在河南告別的病人。

那一年駐馬店醫療服務對象特別多二八年華的少女，麗娟是其中一位，人比較安靜。骨科矯正手術後，她不再一拐一拐走路，對她的外表的改善有重大意義。病人告別會上，我站在麗娟旁一起唱：「中國，祝福你，不用千言和萬語……」，我們竟然同步滴出淚水。一年後手術隊再次來到駐馬店，眼前出現了一個打扮入時的女生來覆診，我幾乎認不出那個便是去年那害羞、不苟言笑的麗娟。接著下來數天，麗娟也在病房出現，無所事事。我問她是否未找到工作？她微笑說已經找到在髮型屋的工作。我催她早點回去上班，不要在此浪費時間了。過了一天，她又出現，說是和我道別，之後就沒有再見面了。回想，一個青春活力的女生，外面世界多姿多彩，為何偏要逗留這狹窄的病房？

Recently I left the hospital where I had worked for 34 years. Initially I felt that I could just leave with no regrets. However, after saying good-byes and finishing all farewell gatherings, I returned to the old workplace. I asked my old colleagues, "Is my spirit hanging around like a ghost?" At this moment, I remembered the former patients I had said farewell to in Henan.

One year, there was a young girl in Zhumadian, a shy person. After the orthopaedic surgery, she could walk normally, without a limp. This made a great improvement in her appearance. She was standing by my side at the farewell ceremony as we sang: "China, bless you, with a thousand words . . ." Both of us cried at the same time. A year later in Zhumadian, she appeared in a fashionable dress. I could hardly recognize her, and she was no longer shy. She hung around in the ward, not doing anything, and I asked



顏兒在舅舅背上。

Yan was carried by her uncle.

在沁陽紅十字會醫院，開始的數天大家忙碌著門診覆診、收症、預備手術室等工作。這時，來了一個我非常熟悉的十二歲女孩顏兒，她一見我便笑容燦爛，我也急著把帶來的禮物給她，相聚一下，把她安置在她認識的病人身旁，她卻哭了起來。我見她並不能自主走路，理療師評估後發現她手術後是改善了一點，但力量不足，情況不算好，決定送她一個數量有限的助行架，並訓練她使用。在訓練期間，我上前鼓勵她，她卻因此分心，我只好離開，她又開始掉淚。我躲在一旁偷看她，觀察她一邊掉眼淚、一邊吃力的學行，令我很擔心她回家後的鍛練。待到傍晚，顏兒需要離開了，她卻不肯，苦苦哀求要多留一會。由於我感受到她不想和我分開，偏偏病房的工作使我無法抽空和她好好相聚，我決定放下工作，送她到醫院門口。和她道別，這時她哭得更厲害，看著長高了的她，哭成淚人兒伏在舅舅的肩背上，舅舅也一面愁容的帶走她，追趕回鄉的尾班車。她一轉身，我的淚水不斷掉下來，心中有點虧欠她對我的濃情，但願她記著我這個姨姨心中有她，不是想丟下她不顧，但也必須狠下心腸和她告別。

門診了一整天，手術名單確認了，知道他這兩天一直在等候，深怕他錯過了手術的機會，我跑下樓梯到門診部找他入院。他這位大學生哥哥



和延偉相識已久。

The author (left) and Yan Wei are old acquaintance.

her if she was working. She told me with a smile that she was working at a hair salon. I urged her to return to work and not to waste time. A day later, she returned. This time she came to say goodbye to me. That was the last time I saw her. I pondered. She was a young, energetic lady. There was an interesting world outside. Why did she come back to our small, crowded ward in the hospital?

One time, we were very busy working at the Red Cross Hospital in Qinyang. We had to take care of the out-patient clinics, hospital admissions, and preoperative preparations. I saw a familiar face of a 12-year-old girl, Yan. She had a brilliant smile. I gave her a present that I had prepared for her, and we chatted for a while. Then, I placed Yan among other patients that she knew. Suddenly she cried. I noticed that she still had difficulty walking, so Yan was evaluated by our physiotherapist. We discovered that even though she had improved after surgery, she was still weak. We decided to give Yan a walker and train her how to use it. At that time, we had a limited number of walkers. I tried to encourage her while she was being trained. However, this only distracted her, and she started to cry. I decided to step aside

阿忠，手術一點難不到他，順利康復翌年回來覆診。他覆診後一直沒有離開，天天早上巡房也見到他。他藉口說是陪去年認識的男生做手術，一起聊天。去年明明說不想耽誤學業急於做手術，今年卻遊手好閒。後來才知道他喜歡了一位女病人，想接近追求。他們看來挺相襯，卻遭到女方家人拒絕，指他未有任何成就。然而，他並沒有因此離開，只是面常帶著失落。一個傍晚，我問他為什麼仍然留在病房，他今次答不出來。過一會，他說真的要走了，我問他將來有甚麼打算？他笑言：「讀神學！」「真的嗎？」「肯定」。那夜風起了，快將下雨，我看著他衣衫單薄的走入黑夜的背影，真的告別了，願阿忠內心強大，勇敢走過迎向他的風吹雨打。

這個男生樣子端正，偏偏一隻腳掌內旋了九十度，走路異常。我問他名字，這位讀工商管理的大學生，充滿自信回答，「兵臨城下的兵、超乎常人的超」。說來，求診病人中，我從未遇上像兵超般自信的病人。他矯正手術後為了證明自己實力，完成攀爬高峰。我問他入院妨礙上課嗎？他滿不在乎說完全沒有難度，自學比上課重要。當別人都在喊我陳阿姨時，他堅持喊我做姐，也為我捎來很多病房的小情報。他做完第二次簡單手術之後可以早點出院但他沒有，說可以陪伴同鄉及出席病人告別

but peeked at her. Yan was trying very hard and was still crying. I was worried about whether she could continue with home exercises after she left. In the evening, it was time to leave, but Yan did not want to go and begged to stay longer. I felt that she was not willing to leave me. However, I had a lot of work to do in the ward and was unable to spend more time with her. I dropped everything that I was doing and took her to the front entrance of the hospital. When I said goodbye to her, Yan cried even more. I watched her, noticing that she had grown much taller, as she leaned against her uncle's back, crying (photo 2). Her uncle in a sad face carried her away. They had to hurry to catch the last bus home. As I turned around, I was unable to hold my tears. I felt sorry that I had to let her go. I hope that Yan will still remember me and understand that I was unable to keep her longer.

Chong was a college student. He had been waiting in the outpatient clinic for a couple of days. Once I knew that the operation list had been finalized and he was on it, I ran downstairs to find him for admission. I did not want Chong to lose the chance for surgery. He handled the surgery and rehabilitation very well. Next year, he came back for his follow-up. After the clinic, he did not leave. Next day, I saw him again during the ward rounds. Chong said he was staying behind to talk to a friend he knew from last year. I remember last year he was in a hurry to get the surgery done so as not to affect his studies. This year he hung around not doing anything. Later I found out that he wanted to get close to a female patient. They looked like a good match. However, the family of the lady rejected him, saying that he had not achieved anything yet. Chong was crestfallen but did not leave immediately. One evening, I asked him why he was still staying. Initially he did not answer. Later, he said he had to go. I asked him, what was his plan? He answered with a smile, "I will study in a theological seminary." I said, "Really?" "Yes, for sure,"



兵超認識了好兄弟阿忠。

Bing Chao and Chong became good friends.

會。這個大男孩出自低下階層，卻有與別不同的氣度，足踝修正了，他的人生將有更大的可能。後來，收到他寄給我的杭白菊，知道他已經在外闖天地了。兵超，姐想你呀！

有個同樣是二十出頭，農村長大的延偉從前走路必須用手支撐在膝蓋上，現在不用了。覆診完成後，他並沒有離開，兩天下來，他仍在覆診群中轉。每當我出入不同診症室，他都會和我握手，每一次也伸出手來要握手，我雖然並沒有拒絕，但也感覺不自在，兩天下來，和他握手了不下百次。當日結束門診時，他煞有介事告訴我他明天真的要走了。我不以為意，明明他一覆完診便早該走了，為何要特別宣告？我和理療師 May 說，覺得他是否奇怪，May 反而很平靜說延偉這番真的要走了，才這樣子。早上的門診，他特地

he answered. The wind was blowing, and rain was imminent. I saw him wearing a thin shirt and disappear into the darkness. I wish Chong's heart will get strong, bracing against the wind and rain that are coming.

He looked handsome. However, his foot was deformed and rotated 90 degrees, and he walked with an abnormal gait. He was a college student studying business management. He told me his name, Bing Chao, with confidence. Truly, he was one of the most confident patients I had met. After surgery he went

mountain climbing to show off his ability. I asked him if hospitalization interfered with his studies. He replied in a carefree manner that self-learning was more important than attending classes. While most patients called me madam, he liked to call me sister. He even brought me some interesting news in the ward. After his second minor surgery, he was discharged the next morning. However, he did not leave. He hung around until the farewell ceremony. This young man came from a lower social economic class, but he had a different manner. His foot deformity is corrected. Hopefully that will open more opportunities for him in life. Later, he sent me Hang baiju (white chrysanthemum of Hangzhou). I know he is developing his career. Bing Chao, sister is thinking about you.

Yan Wei was also in his twenties. He used to walk with a hand supporting his thigh (hand-knee gait). Now he can walk normally. After the clinic visit, he did not leave. Two days later, he was among the crowd in the clinic. As I went in and out of examination rooms, he offered me a handshake. I did not refuse the handshake, but I felt uneasy. We must have shaken a hundred times. That day, at the



作者與女病人合照。

The author was having a photo with a female patient.

進入診症室和我告別，再次握著我手說，我今天走了。我當然知道，因為他昨天已經告訴過我了。

今天，輪到我要告別一個地方和人。在疫潮中，我能和誰握手道別？我都很想煞有介事對這個地方說：我真的要走了，你知嗎？有人在乎嗎？一時之間，我不能說明心底的依依不捨，只能在臨別一刻徘徊不去，心中糾結，找些可以和這裡藕斷絲連的可能。我理性知道自己已經不再屬於這個地方、這個群體。直至有一刻，知道自己非走不可，就move on——必須前走下去，那裏遠方才是我的追求。想起這些徘徊不捨回去的病人，這醫院曾經有一群熱心為他們辛

end of clinic, he came to me saying that he was going to leave the next morning. I did not pay too much attention to what he said. After all, he should have left a long time ago. Why was he announcing his departure to me again? When I spoke to our physiotherapist May about his strange behavior, May told me calmly that Yan Wei did this because he really had to leave. In the morning clinic the next day, he specifically came into the examination room. He shook my hand once again and said that he was leaving. Of course, I knew; he told me yesterday.

Today, it is my turn to say farewell to my people and my workplace. In the pandemic, whose hand can I shake? I want to make a special announcement that I was about to leave. Do you know

that I am leaving? Do you care? I cannot explain this sense of reluctance to leave. I can only linger a bit longer at the farewell. I felt a knot tied in my heart as I searched for any possibility to maintain a connection with the departing place and its people, but I knew I no longer belonged to this place and this group of people. I stayed on until the moment came that I had to leave. I must move on. There is another place for me, far away. And I remember these patients who were reluctant to part. A group of volunteers once worked tirelessly and selflessly for them with no compensation. This group of volunteers walked side by side with the handicapped patients and supported them. They had fun together. They went through rehabilitation together. This was not a hospital. It was a place where the patients could put aside their self-pity and face the challenge of surgery. Through the challenge came the improvement of today. Members of the HIS Foundation teams are workers, and witnesses. I now understand why these patients kept lingering even when the medical personnel were

勞、關愛他們的團隊無償的奉獻醫治她／他，也曾在這裡和同樣承受殘障困苦生活的病人互相扶持、一起歡聚、一起康復。這個地方不是醫院，而是他們放下自卑、堅強去接受手術，迎來今天改變的地方。我們天鄰團隊既是隊友，也是見證人。對這些總是要在手術隊員忙碌中流連、遲遲不願離開的現象的謎題，我今天終於破解了。他們逗留不走並非在此浪費時間，而是想懷緬一下，練習說再見，並支取力量前行下去。「中」！（河南話：音總，好、能、可以的意思，近似講東話說「收到」。）此地一別，便是天涯海角，臨別衷情，不用千言萬語。

感謝主恩眷，差派我們行走在病人中間，願意我們把一份曾經相聚、同行的回憶擱（河南話：「在」的意思）彼此的心上，山河不阻。那不單是一般醫患的關係，而是信任、交托和忠誠、受托的互動，一份心應心的交流，因著醫療事工，成就了美事。

某年有一天，重返河南，晨光初現，我們先在醫院旁路邊小店，吃碗胡辣湯，開始一天的工作。不知將來會有這一天嗎？

「城闕輔三秦，風煙望五津。
與君離別意，同是宦遊人。
海內存知己，天涯若比鄰。
無為在歧路，兒女共沾巾。」
王勃《送杜少府之任蜀州》

busy. They did not consider that a waste of time. They wanted to enjoy the past once more and say goodbye again. They would draw strength to move forward. Once departed, we may never meet again. It was a moment of deep emotion, a moment beyond description with words.

Thanks to the grace of our Lord. He sent us among the patients. May we keep the memory of togetherness deep in our hearts. Nothing can stop this memory. This relationship is not simply a doctor-patient or nurse-patient relationship. It is trust, dedication, and devotion. A heart-to-heart interaction, it is the amazing work accomplished through volunteer medical services.

Someday, we will be back in Henan. First, we will stop by the roadside to enjoy a bowl of pepper soup before we begin our daily work. Will this day happen in the future?

*From the capital around which the old lands lie,
I gaze to the five ferry docks in haze;
The parting feels sad when we say goodbye,
For both left home and are on our post ways.
So long as there's a bosom friend for me,
The world's end seems the next door neighbor close;
At this fork road let us lovers not be,
To wet their handkerchiefs with tear outflows.*

*Vice-Magistrate Du Off to his Post in Sichuan
by: Wang Bo (650 – 675 Tang Dynasty)*

1/4 C

A Quarter of a Century

陳志偉 骨科醫生

Chan Chi Wan Orthopaedic Surgeon

人生有多少個四分世紀（1/4 Century, 1/4 C）？真是老土，卻又的確是貨真價實的將黃金 1/4 C 為天鄰獻上。

96 年初度踏足河南許昌，細小的門診外擠滿了純樸、充滿了泥土氣息的人群，熱切期待的眼神，呼喚著我們重覆又重覆地踏上這征途。中國六千萬肢體殘障人士，縱有千軍萬馬又能治癒多少？何況天鄰二三十人的小隊，在這大海中豈能泛起丁點漣漪？就此常被外人甚或隊員提出質疑；我在 97

How many quarters of a century do you have in your life? This question may sound trite, but some people have indeed spent the prime of life in the ministry of HIS Foundation.

Let's travel back in time to 1996, Xuchang city, Henan province. The entrance to the outpatient clinic is crowded with people, their dark skin, dark hair, and dark clothes greyed by a layer of dust. All jostle to get their illnesses treated, conditions left untreated for many years. Rustic faces and eager eyes keep beckoning to us, imploring us to take this beaten path year after year. With 60 million physically handicapped people in China, how much of a difference can we make? Even if we could mobilize thousands to join our work, would we even cast a ripple in this ocean



1996 年手術隊攝於啟德機場。

Surgical team group photo taken at Kai Tak Airport, 1996.

年早禱會就曾分享海星的故事，能多救一個就救一個，想來可能因祇是頭腦上的認知，欠缺說服力，幸而隊員未有被催眠。但每次覆診之時，病者及家人臉上的笑容，口中的感謝，身體上的改善，都鞭策著我們不再青春的身軀再踏黃土。有幸於 2011、2012 及 2018 年探訪河南舊病人，約二十年前動手術的病人重現於眼前，從前在地上爬行的貝貝，華麗變身成兩孩之母，開著拖拉車送小孩上學；嚴重傷殘求死欲絕的學紅，成為持家有道、相夫教子、協助丈夫事業的賢妻；要父親背負上學的芳芳，現今辦著小生意，育有一男孩……心中愉悅，千金不易。確實的，天鄰不祇是醫治身體，也改變他們破碎的心靈，讓她們重投社會成為有用的人，更有不少人在靈裡得救贖，身、心、社、靈，整個人改變過來。傷感的是可能今生也不能再親見他們的面，握著他們的手，唯有在遠方默默獻上祝福。

1/4 C 中國發生巨變，2020 年人均 GDP 約為 1995 年的 17 倍，數字也在病人身上反映出來，墨黑的皮膚換上光滑白皙的臉容；從前有些病人，家人借貸了數年收入的金額卻求醫失敗，終得天鄰救星出現面前，近年則有些病人在北京上海經專家診治後，也來找香港專家聽多一個意見。唉！有一次

of patients? This question lingers in the minds of many doubters and likely in not a few of our team members. When I share the story of the starfish during morning prayer--saving one more starfish certainly means a lot to the starfish saved!—perhaps I am just indulging my head knowledge; the team members do not seem convinced. But each time we follow up with our patients, we see the happiness on their faces and hear the words of gratitude. The signs of clear physical improvement in our patients goad us to keep our aging bodies climbing the mountain yet again.

We had precious opportunities to revisit some of our old patients three times, in 2011, 2012, and 2018. The patients had had operations about 20 years prior. Bei Bei previously was the little duck crawling on all fours. She did not become a beautiful swan, but she now walks well with crutches, and she drives a small tractor to take her two children to school. Xue Hong became suicidal when three of her limbs were severely mangled. She is now a pretty woman raising her two kids and helping run her husband's rural clinic. From the age of seven Fang Fang could not walk, and her father had to carry her to school. She now runs a small business and has a 3-year-old boy. To see how our former patients have flourished is a heavenly bliss we would not trade for a million shares of Apple. Indeed, HIS Foundation does not just treat patients physically, repairing their hands, legs, or lips. We touch their hearts, turning bitterness into happiness. Moreover, we help them to reintegrate into society and become useful members of the community. And quite a number have found spiritual solace in meeting the Christ we love. Although one sad note is that we may not meet them again face-to-face for the rest of our lives, we send our earnest blessings from afar.

In 1/4 C, the China we served has changed dramatically. GDP per capita in 2020 is about 17 times that in 1995. We find the surge in economic growth reflected in the patients: dark, sun-scotched faces were

在巡病房時拉小孩玩，爸爸拿出 Nikon 單反相機替我們拍照，我臉是笑著，心中卻是一沉。道別病人後在停車場碰上另一病人，爸爸開著小車接她回家。對，有錢人也需要福音，病人即或有錢也不易得到我們這水平的手術，但……我受不了！跟隊員商量後，撤出河南，尋找貧窮人的家鄉，在雲南大理過了幾年歡樂的日子。

與我們合作的醫院，天鄰也成為他們的祝福。有些醫院原有財政赤字，可能是天鄰為醫院增添名聲，病人增多，醫院也得到擴展。更加慶幸的是員工的改變，他們眼見天鄰隊員自掏腰包，千里迢迢，用自己的假期，早出晚歸地用心服務病人，無私奉獻感染了醫護及管理人員，他們更積極工作，對病人更有愛心，相信這也是醫院得以發展的主因。多年來很多醫院員工成為隊員的好友，可惜的是天鄰離開一個工作點後，便很難再回到原點與老友相聚，祈盼天鄰之火能在他們心中繼續熾熱。大陸的發展也令醫院發生轉變，初到河南時，合作單位對天鄰趨之若鶩；經濟猛飛之下，後來合作單位多是置天鄰為可有可無；固然中國還有貧困之人，但手術隊運作模式不能轉移到偏遠地域，近年很難接觸到貧民。2021 年大陸宣佈全面脫貧。

replaced with smooth tender faces. Previously, before they met their “savior,” HIS Foundation, patients might have borrowed several years of family income to pay for treatment that failed. In recent years, however, patients might have had consultations in Beijing or Shanghai before coming to us only to get a second opinion from overseas experts. Sigh! Once in Henan, as I played with a girl during a ward round, her father took out a Nikon SLR camera to capture the moment. My face smiled, but my heart sank. Later, after saying farewell to our patients, I ran into a family in the car park. The father was taking the girl home in his sedan. Well yes, affluent people also need the gospel. And even if they have money our patients might have difficulty obtaining our high standard of care. Nevertheless, I was fed up. After discussing the situation with my team members, we decided to pull out of Henan in search of poorer patients. And we had several years of enjoyable times in Dali, Yunnan province.

HIS Foundation is also a blessing to the hospitals collaborating with us. Some of these hospitals had been financially in the red. Perhaps HIS Foundation teams boosted their reputation and thus their coffers as well. We can see the hospitals become bigger and better. We are more grateful to see that their staffs have also improved. They observe our team members using their holidays, paying their own expenses, travelling thousands of miles, and working long hours to serve patients with care and love. In subsequent years, we noticed the local staffs showing more love and care and dedication. Likely this helps to account for why the hospitals have become better. Over the years, we made many good friends among the hospital staffs. Unfortunately, when we leave one site, we rarely have a chance to meet these old friends again. Our wish is that the spark we lit in their hearts will continue to burn and light up more hearts.

Another change is that in the early years hospitals competed to attract HIS teams to their institutions. In



七兄弟 1996 年河南許昌。

Seven brothers in Xuchang, Henan Province, 1996.

每次回想天鄰發展，都感恩神在不同階段為我們預備合作伙伴，除事情事半功倍外，合作更臻完善，去年已於「最佳拍檔」文中敘述 2020 年 12 月《香港天鄰通訊》。天鄰模式偶有被詬病為手術後拍拍屁股走人，術後治療復康不理想。在雲南時覓得一伙伴機構，有醫生護士術後探訪護理病人，傷口癒合及康復大大改善，但可能傳福音味道太濃，機構不准營運。及後在馬達加斯加則進化出馬島模式，手術隊——教會——教會馬島青年——教會華人——短宣隊互相扣連，彼此祝福，服侍馬島（詳見 2019 年《香港天鄰年報》「異域恩光」）。作為醫生很容易墮入自以為宇宙中心，眾星環繞為的是

recent years, many people were cooler than lukewarm about collaborating with us. Our money represents just a small fraction of their business. Of course China still has many poor people, but the modus operandi of our surgical teams makes it unsafe for us to go to county-level hospitals to reach the poorer people. In 2021, China declares that she has eradicated absolute poverty.

Every time I reflect on the ministry of HIS Foundation, I thank the Lord that He has provided wonderful partners at each stage of our ministry. They helped us to become more efficient, in fact to approach perfection. (Detailed story in HIS newsletter Dec 2020 「最佳拍檔」) Many people are unhappy or even critical of the hit-and-run mode of our surgical teams – operate, brief visit on follow up, and no treatment or rehabilitation until the following year. For several years we collaborated with another NGO in Yunnan province, with a doctor and nurses helping us with post-op wound care and rehabilitation. Perhaps their evangelical efforts overstepped the line, as they were kicked out

給他服務的心態，在馬島神讓我看見我祇是一隻棋子，像國際象棋中的皇后，雖然戰鬥力強，若無別的棋子配合也獨力難支，小若一隻小卒，操到底線後可變成皇后，成為扭轉大局的主將。盼望馬島青年能成為這拼力向前的小卒，又願這馬島藍圖能在天鄰其他工場實現。

尋回 96 年手術隊團體照，照片中有些人仍然偶有見面，但已沒有出隊一段事期了；更多是失去聯絡多年，可說是生死未卜，難免有點唏噓。當然神為各人的計劃盡不相同，有在教會事奉的，有在工作上為主見證，甚或是照顧年老雙親，實無需臆測別人的心志，耶穌說：「……與你何干？你跟從我吧！」（約 21:22）。轉眼再看這半杯水，竟有一些是在這 ¼ C 不間斷地為天鄰燃點生命，即或至親離世，身患重病，工作巨變，也難阻他們為主全然獻上，令我肅然起敬。第三次看，原相中九成是 25 至 40 歲一族，擁有些人生經驗，卻仍精力旺盛，幹勁十足；如是者天鄰由一年一個手術隊加一個小覆診隊，發展到一年多至十七個手術隊或覆診隊（香港 + 美國）。美國天鄰發展蓬勃，澳洲也有不少隊員。又再看近年照片，40 歲以上已成為多數，也不少是 60 歲以上的，人口老化這世界問題也侵襲天鄰？其實當

of China. Then the Madagascar model evolved: the surgical team, the church, the church Malagasy youth, the church Chinese, and short-term mission support teams, all working synergistically or even symbiotically, mutually blessing and together bringing blessings to Madagascar. As a surgeon, it would be easy to fall into the trap, imagining ourselves the center of the universe, with the moon and stars revolving around us to help fulfill our mission. But God showed me a different plan in Madagascar. I am like the queen in a chess match; although powerful, I will not survive if I fight solo. The small and weak pawn, marching insistently to the baseline, is promoted to a queen and becomes the game-changer. My wish is that our church Malagasy youth become like this persevering pawn. May this Madagascar model become the blueprint for other sites of HIS Foundation to grow into well-rounded and flourishing ministries.

Digging out the group photo taken in 1996, some members we still see occasionally but who have not joined teams for some years already. More common are people we have lost contact with, not sure if they are alive or not. Such reflections might be depressing, but fortunately I am not a pessimist. We must submit that God has plans tailored to each individual, so conjecture about the apparent absence of former team members is fruitless. Some may be drowned by their church commitment. Others may have found the best path in testifying through their careers. Perhaps a few simply had to stay home to care for ailing parents. Looking at this half-filled glass again, I find many who are igniting their lives incessantly for HIS Foundation, despite losing loved ones, enduring major illnesses, or weathering tumultuous changes in their careers. Trials and tribulations have not barred their sacrifice for God. I salute them from the bottom of my heart. Looking at the group photo again, I see 90% of the team in the age range of 25 to 40. They have had a little life experience, and are still healthy and energetic. With people like them, our surgical teams greatly expanded

然這是多元因素，教會人口老化是不爭之實，社會因素估計更為重要。我被笑說是「大中華膠」，猜想在天鄰多的是；但當今年輕一代拿著智能手機長大，視野更國際化，生活更多元化，追求生活質素等，他們當中有多少大中華膠呢？2011 年我在美國天鄰感恩晚會分享，見到一些天鄰人的子女參與事工，於是道出薪火相傳的理想，可惜天鄰二代未能成為主流，要隊員年輕化我們仍需努力。

轉眼再看天鄰的董事會，竟然過半人服侍 $\geq \frac{1}{4}$ C，若包括浩敏祇差一年便 $=\frac{1}{4}$ C 的話，便佔董事會 75%！其實早在十多年前便著手引進較年輕者加入董事會，也是在諸多因素下，現存董事多為兩鬢斑白者。我工作部門有一笑話曰：「天下無不散之筵席，久唔久有餐食」，事因同事跳槽升職，或私人執業，便設晚宴歡聚，離別是不變定律。日前在一餐廳看見牆上的漫畫，此人愁著問智者，我手中之杯到底是半滿還是半空，智者曰「打碎你的杯便能解決你的愁煩！」誠然，老化不老化又如何，無需執著，黑貓白貓年老者年輕者，凡忠心侍主者便是主所喜悅者。轉念，人生有多少 $\frac{1}{4}$ C，你有那些事奉是你願意委身 $\frac{1}{4}$ C？向諸位仍堅守天鄰的董事致敬！

from one big team plus one short follow-up team each year, to 17 big teams and follow-up teams a year in 2019. HIS USA has developed rapidly. We also have many members from Australia. Whoever is willing to surrender to God, God will bless them abundantly, and through them bless HIS Foundation. But looking at more recent photos, I see that the majority are over 40, and not a few are over 60. Has the aging population so dramatically altered our team composition? Of course this is multifactorial. Most churches have an aging problem too. I believe social factors may be more important. Like many people of my generation, the love for China cannot be eradicated from my blood even if you put me on hemodialysis. On the other hand, the present generation grew up suckling a smartphone. Their world view is more international, their lives more colorful and varied. They treasure work/life balance. How many of them would test as blood group C+? (clue: C for C....) In 2011, I gave my testimony at the US Thanksgiving dinner. There I saw some second-generation HIS members joining in the ministry. I shared my vision of passing the torch. However, this seems not to be catching on. We need to work more on HIS Gen 2 as well as on attracting younger team members.

Turning to our HK Board, more than half served in HIS Foundation $\geq \frac{1}{4}$ C. If we include Ho Man, who is just one year shy of $\frac{1}{4}$ C, the total comes to 75%. Aging is also visible on our Board! Actually, over 10 years ago, we began recruiting younger board members. For various reasons, those still on the Board tend to have silver lining in their hair. Just last week, I saw a cartoon on the walls of a restaurant. A troubled man asked, "Wise one, wise one. Is my glass half full or half empty?" To which the wise man replied, "Break your glass and you have no more trouble." Indeed, what does it matter if we have aged or not? Black cat, white cat, old man, young man, whoever is fully committed to Christ will be loved by Him. Paradigm shift. How many $\frac{1}{4}$ C do you have in your lives? What

再回顧我自己，96年第一次出隊，有一隊員呼我為「壽司醫生」，事後才知指「一舊飯」；我要申報利益，當時正患感冒喉痛，大多時躲在一角不出聲也。多年後不再壽司，¼ C 後青澀變老柴，外體顯著敗壞，感恩手上的刀依然鋒利。環顧從前醫學院舊同學，有些是公務員，早於十年前提早退休「咬長糧」，到處騎單車唱唱 K；也有些在私人執業多年，早是上岸一輩，終日打高爾夫品嚐紅酒的生活。作為醫生，當然更多見的是連親生女兒也不認得的長者，或是終日臥床，與垂死軀體爭扎著的生存者。幸而點綴在我身旁的還有像我教會胡欽老牧師，在教會退休後，回饋家鄉安徽省，建立

kind of ministry are you willing to commit for ¼ C? To our Board members persevering for ¼ C, again I salute you!

Turning to myself now. When I first joined in 1996, a team member called me “Doctor Sushi.” Sushi is a lump of rice (一舊飯) ; in Cantonese it means dumb one. I have to declare that I had the flu and a sore throat at that time. So I was often hiding in a corner, too sick to say or do much. But a quarter of a century passed, and I am Sushi no more. The greenhorn has become an old hen. Aging is visible over every part of my body. Fortunately, the scalpel in my hand is as sharp as ever. As I look around at my classmates in medical school, I find that some became civil servants, took early retirement 10 years ago, and are enjoying their pensions. Some engage in cycling every now and then, and in karaoke often. Others went into private practice very early on and earned a fortune. These folks are often seen golfing and enjoying their lives bathed in red wine. As a doctor, of course, I commonly encounter elderlies who cannot recognize their own daughter. Or those barely surviving, tethered

了 60 所中、小學校、14 間醫院、150 間教會、兩間神學院等，風塵僕僕至 87 歲才停下他中港兩地跑的腳蹤；我常謔笑他「做壞行規」，對我們這些初老者，意欲安享晚年者乃當頭棒喝。其實無論你年紀大小，你也要選擇：是還有心跳呼吸的「生存」著，祇懂吃喝玩樂的「生活」著，抑或有血有肉有使命地燃點著餘下「生命」，你知我的答案吧。

翻閱手中 30 週年特刊見證篇，不論是病人、學生、老師、他們的家人或我們的合作伙伴，談的不是他們的手、足、口得到醫治，或是他們有書讀了，而是他們的生命如何被天鄰觸摸到、改變到，縱或十年廿年後仍歷歷在目。當中的醫生、護士、老師等，述說他們不是施與者，而是被祝福者，被燃點者。誠然，天鄰——這不單是董事、隊員，而是每個為天鄰流下汗水淚水，付上禱告或金錢者。天鄰不是派錢的基金，我們是藉生命影響生命，是愛的使者。在這三十週年數算恩典之日，見祝福因華東水災而始，愛的火種已撒播全球，我有幸在這 ¼ C 「偶然」與天鄰的軌道重疊，領受無比祝福，今生無悔，即或今天蒙主寵召，應當不是空手見父神，盼望在彼岸聽見「又良善又忠心的僕人」之呼喚。

to their beds 24/7. Fortunately, we also have people illuminating our lives like my old church pastor. After retiring from our church, he dedicated his remaining life to his home province of Anhui. He built 60 schools, 14 hospitals, 150 churches, 2 Bible seminaries etc. I often teased him for setting a bad example for us. For the young old like me, dreaming of a leisurely life ahead, this is a nasty wake-up call. Honestly, whatever your age you have to choose: “surviving,” just with heart beat and breathing; “living,” perhaps enjoying life but with no clear purpose, not benefiting the people around; or burning your life, with a passion almost blinding to the people around you, with a calling to make the world a better place. Without a doubt, you can guess my choice.

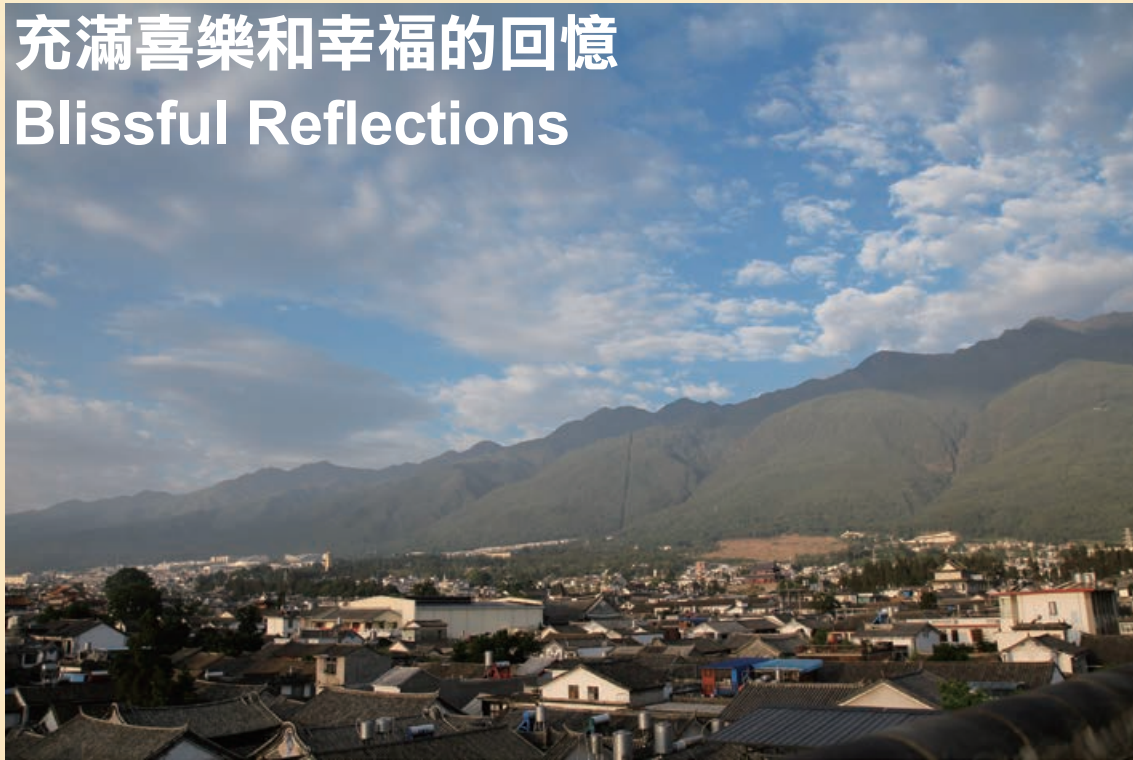I was reading through the 30th anniversary testimonial book (HK). Whether patients, students, teachers, family members, or those who partnered with us, they are not talking about how their hands, legs, lips have been healed, or that they finally have a chance to study. Rather, they describe how their lives have been touched, moved, transformed by HIS Foundation. Our volunteer doctors, nurses, and teachers testify that they are more the receivers than the givers of blessings, how their lives are burning for Christ. Yes, HIS Foundation – not just Board members and team members, but all who have shed their blood, sweat, or tears, all who offered up prayer and money – is not simply a foundation that doles out money. We use our life testimony to transform lives; we are messengers of God’s love. This blessing was born due to the great flood in China. By now the seeds have been planted throughout the world. In this year, when HIS Foundation counts our blessings across 30 years, I am really thankful that “accidentally” my ¼ C crossed path with HIS Foundation. I have received blessings overflowing. No regrets. Even if I receive His urgent call to move upstairs today, I think I won’t go empty handed. Hopefully I can hear Him calling “good and faithful servant” when the elevator door opens.



1998 年宜陽門診。

Outpatients clinic, Yiyang, Henan in 1998.

充滿喜樂和幸福的回憶 Blissful Reflections



Rochelle Dy 小兒康復科醫生
劉漢杰 中文翻譯

Rochelle Dy, MD
Pediatric Rehabilitation Specialist

一個星期天下午，剛剛完了教會的主日崇拜，與朋友午膳，我隨便的問我的朋友，是否知道有方法買到大批的輪椅，用以捐去菲律賓？當時我負責一個小的組織，由菲律賓畢業的醫生組成，我們計劃去菲律賓開展一些醫療及康復的服務。「有一個機構每次捐贈幾百張輪椅到中國農村，送給貧困人士。」這個回覆超乎我的想像，我當時未有想到，原來 神正在預備我的心去事奉祂。我是第三代的菲律賓華僑，在菲律賓長大，我曾想像如果我的祖父沒有離開中國，我現在的生活是怎樣呢？我還可以有機會接受訓練成為醫生嗎？還有機會認識福音而成為耶穌基督的追隨者嗎？多年

My journey with HIS Foundation started as a casual question to a friend while having lunch after church service one Sunday afternoon. “Do you know where I can purchase wheelchairs in bulk that can be shipped to the Philippines?” At that time, I was leading a small organization of Filipino doctors in the United States planning for a medical and rehabilitation outreach project to the Philippines. I received an answer far larger than what I was asking for: “Well, there is a group that sends several hundreds of wheelchairs and distributes them to the rural poor in China.” Little did I know that this was the path that God was preparing my heart for. Over the years, I had a growing interest and desire to better understand my ancestral roots and the land of my origin, and God willing, to

來我有一個越來越濃厚的渴望，就是去尋根，去認識中國，甚至如果是 神的旨意，能夠去服務中國作為回饋神的恩典。

當我了解天鄰基金會在中國各地的的工作之後，我覺得很適合我參加作義工，以提供康復治療的服務，這是一個完美的配搭。作為一位小兒康復的專科醫生，我經常治療腦癱和其他先天或後天性的殘疾兒童。腦癱是世界上最常見引致兒童殘障的原因，該病常常連帶有其他醫學問題，例如癲癇和視力障礙等。病的嚴重性因人而異，主要是視乎腦部的受損害情度而定。很多腦癱的孩子都有上、下肢肌肉緊張和乏力的現像，而令到走路和日常活動困難，甚至不可能。當孩子漸漸長大，他們的骨骼不能正常地發展，甚至引致位置異常，緊張的肌腱導致骨頭和關節變形，這就更加妨礙肢體的功能。物理治療、職業治療及語言治療可以有效地改善體力和功能。有時藥物、支具和手術可以改善孩子走路的能力。但是處理腦癱最重要的工作就是教育病人和家長，由醫護人員來指導護理方法，並且提供支援，以幫助患者和家庭。

於 2012 年，我參加了由劉漢杰醫生帶領的骨科隊，到雲南大理服務。這是我第一次踏足中國，我對她的環境、醫療制度和可取用的資源一無所知，我的中文詞彙只有幼稚園程度，但我的隊友非常樂意為我提供幫助，讓我適應新境況，他們為我翻譯，又教我有關當地的文化、地理和語言。自此，我每年都參與大理隊的服務，直至 2018 年後

be able to serve and give back. As a third-generation Filipino-Chinese, born and raised in the Philippines, I often wondered what my life would have been if my grandfather had never left China. Would I have had the opportunity to acquire the training and skills to become a doctor? Would I still have had the opportunity to hear the Gospel and become a follower of Jesus?

Learning about the medical outreach services provided by HIS foundation in various places in China, I saw an opportunity to volunteer my medical and rehabilitative specialty services; it was a perfect match! As a pediatric physical medicine and rehabilitation physician, I work closely with patients with cerebral palsy and other conditions that result in impaired function, either congenital or acquired. Cerebral palsy is the most common cause of disability in children worldwide. The severity of the condition and possible accompanying medical problems (such as seizures or impaired vision) varies from one person to another depending on the extent of injury or abnormality in the brain. Many children have tightness in their muscles and weakness in their arms and legs, which makes walking and performance of daily activities difficult, if even possible. As these children grow, their bones do not develop well and become misaligned, and their muscles tighten to the point of causing bone and joint deformities, further limiting their functional abilities. Physical, occupational, and speech therapy services are much needed to help them improve their strength and function. At times, medications, braces or splints, and surgery can help improve a child's ability to walk. However, the most important part is patient and family education, as the medical

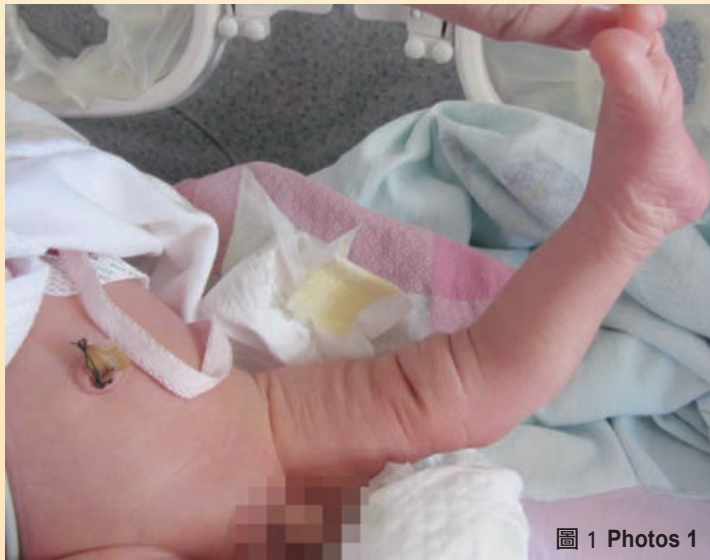

圖 1 Photos 1

這個兩天大的嬰兒，左側膝部過度向前伸展，超越正常的位置。

Hyperextension of the left knee of a 2-day-old baby.

醫院不再與我們續約為止。在這些年裡，隊友間之友情建立起來，我們每年都渴望再重敘。此外，又渴望能夠見到病人回來覆診，或去探望舊病人，尤其是那些需要長期護理的患者。回顧這七個年頭，我不禁感謝 神給我機會去服事中國的同胞。讓我與你們分享以下一些精彩的回憶。

祝福

我見證了 神無數的恩典和奇蹟，親身經歷了許多的醫治和康復個案，而且慶幸能夠參與其中，但在眾多病例之中，最令我難忘的就是以下的一個。

當天是醫療隊在大理醫院工作的最後一天，手術室工作人員正忙着為病人檢查傷口、換石膏和收拾醫

and paramedical team offer support and guidance in providing care.

The first trip I embarked on was with the Orthopaedics team to Dali, Yunnan province, led by Dr. James Lau in 2012. It was also my first trip to China, and I did not know what to expect in terms of the environment, the medical care system and available resources. My Mandarin vocabulary was perhaps at a kindergarten level, but my teammates were so welcoming and accommodating. They helped translate for me and taught me about the place,

the culture, and the language. Each year I joined the team to Dali until our contract was no longer renewed in 2018. Over the years, bonds of friendship developed, and we all looked forward to a reunion and to visiting our patients, especially those who returned for follow-up and ongoing care. Reflecting over those 7 years, I cannot help but praise and thank the Lord for giving me the opportunity to serve my brothers and sisters in China. Allow me to share a few highlights of these reflections.

The Blessing

Among the countless instances of God's display of mercies and miracles, success stories of healing and recovery that I have been blessed to witness and be a part of, one in particular stand out for me.

療儀器。在接近黃昏的時候，醫院一位當班的醫生聯絡我，要求我們去看一個出生才兩天的嬰兒。這嬰兒的膝部過度向前伸展，超越正常的位置（圖 1）。原來孩子是雙胞胎之一，他們是早產兒，早了幾個星期出生，體重比正常嬰兒為輕，皮膚非常脆弱，呼吸又遇上問題，現正在初生嬰兒深切治療部醫治。媽媽因為剖腹產而大量出血，並有其他併發症，所以也在醫院接受治療和觀察。爸爸和祖父母當然心急如焚，十分焦慮。晚上九時，劉醫生和我終於帶着石膏，來到嬰兒的牀邊。我們把膝關節復位，然後打上石膏固定，以免再次脫位，我們祈願孩子膝部能夠正常成長。

翌日，當大隊正收拾東西，準備離開，醫療隊的聯絡人和我決定去探望嬰兒的母親，她一直要臥牀休息，從未有機會擁抱初生的雙胞胎。她分享感覺非常傷心和內疚，因為不能夠照顧孩子，她很渴望可以把孩子抱在懷裡。我們告訴她孩子的情況及接受了治療，並且鼓勵她，她很感激並且願意讓我們為孩子的痊癒而禱告。我們在大理的合作伙伴跟進，在幾個星期後把石膏拆掉。

翌年，我們回到大理，媽媽主動來找我們，孩子成長得很好，已經走路了！在該年醫療隊完成工作後的告別會中，一家人都出席了，媽媽還致詞表示感謝 神施行奇妙的醫治。見到兩個孩子健康地成長，令我心中產生無限喜悅（圖 2、3）。耶穌曾說：「施比受更為有福。」此刻我深深感受這話語的真實。因為言語的障礙，我當天沒有說甚

It was our last full day in Dali, and the surgical team was busy in the operating room with final cast changes, wound checks, and closures. In late afternoon, I received a call from a hospital attendant asking if we could see a 2-day-old baby whose left knee was extended beyond the normal range (hyperextension) (photo 1). Born a few weeks premature, he and his twin had a breathing problem. With delicate skin, and small for his gestational age, he required intensive care. His mother delivered the twins by Cesarean section and suffered complications including significant blood loss; thus, she also needed treatment and close monitoring. The father and the grandparents were understandably worried and distressed about the health of the twins and the mother. It was not until 9:00 PM when Dr. Lau and I were able to return to the newborn's bedside and applied plaster cast over his left leg to keep it in a proper position and prevent further dislocation. We could only hope and pray that this condition would resolve as the baby grew older.

The next morning, while the rest of the team packs our things to prepare for departure, our team coordinator and I decide to quickly visit the mother, who is on strict bedrest and thus has never held her newborn twins; in fact, she has yet to see them. She shares with us her utmost heartache and her guilt at not being able to care for them, and she tells us how much she longs to hold them in her arms. We inform her about the one twin's condition and the treatment he received, and we encourage her. The mother is grateful and allows us to pray for her and her son's full recovery. Our local partners provide follow-up care, and several weeks later remove the cast.



圖 2-3 Photos 2-3



雙胞胎嬰兒的父母回來向醫療隊表示感謝。
Parents of the twins came back to express appreciation to the surgery team.

麼，但是這事情提醒我，我的出席和陪伴，給予這位母親在她最困難的時候，送上了一份支持和祝福。

每一個人都是有價值的

很不幸殘障人士常常被社會貶低他們的價值，這些人士除了要面對求醫的困難和資源不足的艱辛之外，還經常被剝奪融入社會成為有建設性的公民之機會。因為他們的殘疾，人們迴避他們，他們被忽略，又被奪去尊嚴，時常陷於絕望。天鄰基金會的工作，就是要肯定他們的價值，特別是殘疾和貧窮的人，並且藉着醫療服務，展現基督的愛，為患者及家庭帶來希望。

我特別喜歡去探訪一些住在偏遠地區的病人，這些病者沒有交通方法來診所就醫。我們為他們檢查支

The following year, when we return to Dali the mother reaches out to let us know that her son is doing very well and is already walking! She comes with her family and gives a speech of thanks at our closing ceremony and praises the Lord for this miracle. To see her twins healthy and growing is indeed a great joy (photos 2,3). As Jesus' words teach us, it is more blessed to give than to receive (Acts 20:35); this rings especially true for me in this moment. Although, given the language barrier I did not speak much that day, yet, I am humbled and reminded that by just being present were enough to offer her the support and encouragement she needed during those difficult times.

Each person is valuable

Unfortunately, individuals with disabilities or deformities are devalued by society.

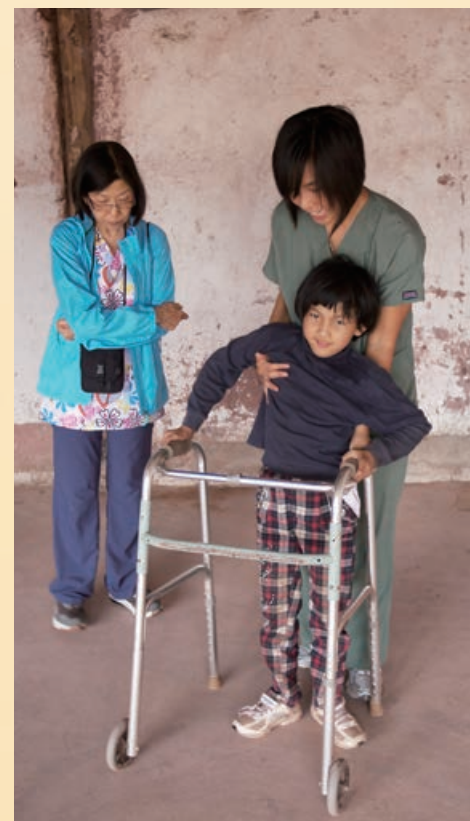

圖 4-7 Photos 4-7



家訪一位 8 歲大患有運動障礙性腦癱的孩子，患者的四肢有不隨意的活動，不受控制，並且很難保持身體的平衡。醫療隊隊員教授病人各種技術包括正確的坐姿、正確的走路姿勢、使用助行器方法等。此外，又教授家人如何用遊戲來幫助患者鍛鍊身體。

At the home of an 8-year-old girl with dyskinetic cerebral palsy; she has involuntary movements in her limbs and difficulty stabilizing her body. Various techniques for properly positioning her in sitting, in walking with and without a walker, and exercises through play and fun activities are demonstrated to the family.



具，又教家人怎樣協助患者在家中做康復運動（圖 4-10）。

我們醫療隊給我留下的一個深刻印象，就是多學科的專業隊伍，這對以病人為中心的照顧十分重要。這其實是一個最理想之醫治模式，即使在大的醫療中心也很難做到。但 神奇地把骨科、麻醉科、康復科、物理及職業治療、護理和支具科技等的專家連在一起，組成了大理醫療隊，大家各盡所長，又願意與病人及家屬商討醫治方案（圖 11-13）。

早期的康復運動對病人的痊癒至

Moreover, not only do these individuals face challenges in gaining access to medical care and adequate resources, but they also are often deprived of the opportunity to be integrated into the community and to become productive citizens. Because of their impairments, they may be neglected, shunned, stripped of their dignity, and left hopeless. The work of HIS Foundation emphasizes the value of each person, especially those who are disabled and poor, and brings the love of Christ through medical care and service, providing hope to afflicted individuals and their families.

I especially enjoyed the times when we

圖 8-10 Photos 8-10



醫療隊探訪一位 10 歲患有痙攣性腦癱的男童，他早一年接受了天鄰手術隊提供的跟腱延長手術。圖 10 顯示一個臨時方法，讓病人在家中練習站立，鼓勵直立姿勢，並且作伸展運動。

Visiting with a 10-year-old boy with spastic diplegic cerebral palsy, following heelcord-lengthening surgery by the HIS Foundation team a year prior. Photo 9 shows an improvised standing exercise regimen at home as part of his therapy to stretch his legs and promote an upright posture.




由骨科、麻醉科、康復科、物理及職業治療、護理和支具科的專業人士組成的醫療隊。

A multi-specialty team include specialists from orthopaedics, anesthesia, rehabilitation, physical and occupational therapy, nursing, and orthotists.

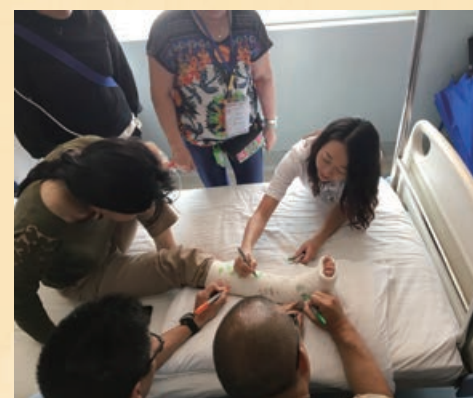
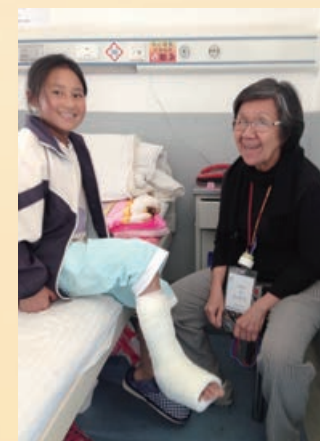
圖 11-13 Photos 11-13

圖 14-16 Photos 14-16



病者依照物理治療師和職業治療師的指導做康復運動。

Patients follow the instruction of physical and occupational therapists in doing rehabilitation exercises.

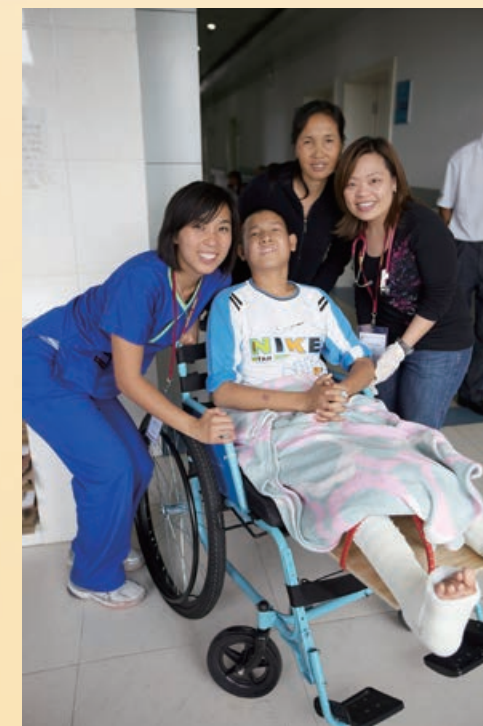

圖 17-19 Photos 17-19



performed home therapy visits for some of our patients who lived far out in the countryside and did not have the means for transportation to see us in the clinic. We checked their braces for proper fit and taught the families exercises that can be done at home (home visit, photos 4-9).

One quality about our team that truly impresses me is our multi- and interdisciplinary team approach to patient-centered care. This is the ideal model of care, but we know it is challenging to put together and hardly occurs even in the more advanced medical centers. Yet here, God assembles the team in Dali as Orthopaedics, Anesthesia, Rehabilitation, Therapy, Nursing and Orthotics (brace specialist) come together, with all hands-on deck, to discuss assessment findings and the treatment plan with the patient and the family (photos 11-13).

Early mobilization and rehabilitation are vital to enhance functional recovery, especially after surgery. Once medically cleared, the patient receives inpatient physical and occupational therapy services (photos 14-16). Education is empowerment. Thus, during our outpatient therapy clinics, we strive to provide patients and their families with therapy tools and techniques to improve functional abilities, which they happily accept (photos 17-19).

Serving and growing together as a family in Christ

A family that prays together, eats (and

治療師在教導病人做康復運動。

Therapists are teaching patients the proper exercise techniques.

為重要，特別是手術後的患者。所以，當醫生認為手術後病人能夠開始活動，物理治療師和職業治療師就馬上開始病人的康復運動（圖 14-16）。教育也很重要，能讓病人明瞭病情。所以，在康復門診中，我們盡力教授病者及家人適當的康復技術，讓他們可以改善身體功能，他們都欣然接受（圖 17-19）。

在基督裡一起事奉和成長

一個家庭如果能夠一起祈禱、一起進餐和一起娛樂，這家庭將會維繫在一起（圖 20-22）。我從隊員和病人身上學到很多功課，是對我的一種激勵，並且令我成長，這些都是讓我喜悅的經驗。天鄰的事奉令我謙卑，又教我學會辦事要靈活，隨時因需要而修改計劃，不要一成不變。我常常被天鄰隊員的愛心、委身和熱心所激勵。我們每人只有五餅二魚，但我們盡其所能，完全信賴神的供應，我們見到神彰顯祂的大能，我學習到信靠和依賴祂，願神繼續使用這事工來榮耀祂的名。



圖 20-22 Photos 20-22

eats more) together, and has fun together, stays together (photos 20-22). I have enjoyed a heartening and growing experience, and I have learned a lot from my patients and my teammates. Serving with HIS Foundation has taught me humility and the need to be flexible and ready to do what is needed. I am continually inspired by the passion, dedication, and love that emanates from each team member. As we each bring our five loaves and our two fishes, we work with what we have, to provide the best care we can, while fully relying on God's provisions, and we watch as He unfolds His power. My faith has been strengthened by learning to trust and fully rely on Him. May the Lord continue to use this ministry for His glory and honor!



醫療隊員一起生活，樂也融融。

Members of medical team living together happily.

天鄰醫療事工 HIS Foundation Medical Ministry : 一個經歷神，服侍人，改變生命的事奉 A Ministry That Transforms Lives Through Serving People and Experiencing God

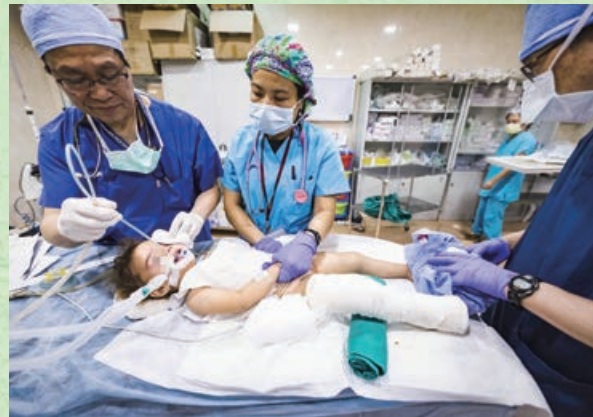吳國威 麻醉科醫生
Stephen Eng, MD Anesthesiologist

90 年初中國華東大水災，透過中國河南省紅十字會的邀請和協助，天鄰醫療事工，始於河南省的許昌市，繼而展開到洛陽市，駐馬店，平頂山，沁陽和安陽市，其後更有機會到雲南，四川，青海不同城市服務。服侍對象，大多是行動不便的小兒麻痺後遺症，腦癱及嚴重馬蹄內翻的病人。

這些貧困殘疾病患者，都是弱勢社群，為了治病，家人四處求醫，以致家境一貧如洗。不少患者，在學校遭到同學的白眼和歧視，在社會，也遇到不平等的待遇，面對殘酷的現實以致心力交瘁，感覺絕望和前景暗淡。

The medical ministry of HIS Foundation got started in the early 1990's during the Great Flood of Henan Province in Northeastern China. Through the invitation and support of the Chinese Red Cross, our medical and surgical services began in the City of Xuchang, followed shortly by services in the surrounding cities of Luoyang, Zhumadian, Pingdingshan, Qinyang and Anyang. In time, Orthopaedic surgical services were further expanded to the Provinces of Yunnan, Sichuan and Qinghai.

The vast majority of the patients we serve are living below the poverty line with extremely limited access to healthcare. Most are suffering from disabilities resulting from cerebral palsy, post-poliomyelitis syndrome, and severe congenital club foot deformities.



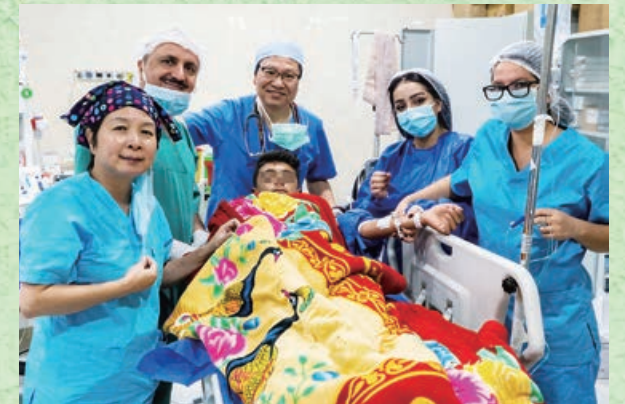吳醫生在照顧一名小兒骨科病人。

Dr. Eng taking care of a pediatric orthopaedic patient.

但聖經教導我們，要傳福音給貧窮的人，宣告被擄的得釋放，瞎眼的得看見，受壓制的得自由（路加福音 4:18）。天鄰同工就帶着從神而來的愛和關懷，作主的使者，以愛心行動去參與醫治關懷的事工，願意將愛心，希望和曙光，帶到幽暗失落的角落。

患者的父母，看見子女經手術及物理治療後，竟然可以站起來走路，心中那份喜悅快慰，實在是難以形容，也讓我們深深體會到，這個愛的行動事工是有意義，有價值的，因為用真愛的行動去影響生命，是最有效的見證，勝過千言萬語。

隨着天鄰醫療團隊持久不斷的服侍和跟進，讓我們看見殘疾病人生活上行



吳醫生、病人、醫療隊員及當地麻醉科醫生合照。

Dr. Eng had photo with patient, medical team members, and local anesthesiologist.

Daily life is especially difficult for this marginalized group with disabilities. Many families have used up their lifetime savings to seek local medical or surgical treatments to no avail. They are constantly being looked down upon by classmates in school and are generally "discarded" by society. Most are suffering from low self-esteem, depression, and hopelessness due to their bleak future.

Inspired and empowered by the love of God, HIS Foundation volunteers respond to the call of the Great Commission: to preach the good news to the poor, to proclaim freedom for prisoners and recovery of sight for the blind, and to release the oppressed (Luke 4:18). Through the Medical/Surgical services and Caring Ministry of HIS Foundation, we strive to bring God's love, light and hope to the darkest corners of the world through actions of love.

Every parent of these disabled children is elated to see their child transformed. Whereas once they were crouched, hunched over or crawling through life with their deformities, after corrective surgery and extensive physical therapy, they are able to stand up, start taking steps and even walk again. Some are able to have gainful employment. Some have gotten married and had children. Some have accepted Christ as their personal Lord and Savior. We are grateful to see so many lives touched and

transformed by the power of the Holy Spirit. The joy, relief and gratitude expressed by these patients and their families is beyond description. It reaffirms to us that this love in action is valuable and meaningful and a powerful testimony. May His love continue to surround and uphold them always. We pray that they will respond to His love and grace and pass it on to those who are in need around them. We love because God first loved us.

By His grace, God has miraculously opened another door for HIS team to serve in Zakho, a city in the Kurdistan region of Northwestern Iraq. We are able to provide medical and surgical services to the poor and displaced Yazidi refugees, an ethnic group who are being persecuted through an “ethnic cleansing” and forced to flee to the Kurdistan region for safety.

動得到改善，身心靈創傷得到神大能的醫治和大愛的安慰後，生命得以振作，激勵和更新，自信心得重建；可以重投社會工作，結婚生子，實在帶給我們不少的喜樂和欣慰，亦為他們生命的更新和生活的改善，不斷感恩。願主的愛，繼續圍繞、激勵這些曾被社會遺忘的一群，更願他們將這份屬天的愛，傳遞下去，給予更多需要幫助的人。願這份信念和關懷，常存在他們心底，知道人間有愛，是因為神先愛我們，我們對人獻出關懷和愛心服侍，實是對神大愛和恩典的回應。

最近兩年，神奇妙的恩手更為天鄰醫療事工展開新領域，帶領我們到伊拉克北庫爾德斯坦地區的 Zakho 市，去參與服侍貧困和流離失所，被種族清洗迫害而逃亡到庫爾德斯坦的雅茲迪難民，開始了當地聯合國難民營的骨科醫療工作。

回憶所到之處，都清楚看見神的開路和帶領，處處都留下福音能醫治人身心靈大能的見證，在眾病患中更留下許多恩典的記號和祝福。



吳醫生接受長期服務獎。

Dr. Eng received long-term service award.

Reflecting on the places where we served previously, we are able to see a clear picture of God’s grace and guidance. Everywhere we go, there are testimonies of the power of the Gospel to heal the body, mind, and soul.

It has been a tremendous blessing for me to be able to use the professional skill God bestowed upon me to serve Him and the people He loves. Although it has been challenging for me to leave my comfort zone and practice anesthesiology in an unfamiliar environment with less sophisticated medical equipment, it requires me to pray earnestly and rely on His strength and protection to finish the work He entrusted to me. I learned in the medical mission field to be very flexible and wholeheartedly rely on His help, strength and guidance. It has been a great opportunity to experience God myself and develop spiritual formation which I will treasure forever.

May those patients who were healed through His ministry be bold to witness His wonderful love and grace. May the seeds of love we sow in their hearts, in His time, germinate and grow. May His name be glorified in all we do and in every life we touch.

回顧過往參與天鄰醫療短宣的日子，深深感受到，能夠用專業在事奉祭壇上去榮耀神，服侍人的，實在是何等寶貴，一切都是神對為我豐富的預備，更是我生命中美好的祝福和恩典。

能夠離開日常工作的安舒區，去到陌生、設備不完善和言語有別的環境下去做手術麻醉工作，迫使我不斷的去用禱告仰望交托，更認真的去倚靠祂的加力扶助和保守，才能完成所托付的工作，醫療短宣讓我有機會去學習鍛煉全心依靠神大能的幫助，需要放下自己，隨機應變，與主同工，不但是屬靈操練的好機會，更能體會經歷神的寶貴。

惟願病人經過身心靈醫治後，能彰顯和見證天父奇妙的大愛和恩典。但願我們在他們生命中播下愛的種子，在祂的時間，能發芽生長，榮神益人，但願一切榮耀頌讚歸與天父。



離別前，醫療隊員與手術後病人合照。

Medical team members had photo with a postoperative patient before departure.

天鄰醫療服務之奇妙旅程

A Wonderful Journey of Medical Service with the HIS Foundation

丘婕 醫療化驗師

Yau Chi Medical Technologist
Translation by James Lau



作者（中）與骨科隊隊員在大理基督教會正門合照留念。

Author (middle) and orthopaedic team members taking a photo at the main entrance of Dali Christian Church.

想一想，原來開始參加天鄰基金會事工，已經是大概三十年前的事啊，一去就竟然連續了二十多年，沒斷過，有時候一年還去兩次。在回憶中的時間總是那麼的快，一切仿如昨日。

I first joined the HIS Foundation ministry 30 years ago, and I have been on HIS Foundation service teams every year for over 20 consecutive years. Sometimes I went once a year, sometimes twice a year. Time passed so quickly, and yet my memories are as fresh and vivid as yesterday.

就在上世紀末，在北京發生了震撼人心的事件，看見不少年輕人犧牲了很多，覺得自己很幸福，不用付出甚麼，就得到他們拼了命也未必獲取到的幸福。所以很想為那些很有需要的老百姓做點甚麼。我擁有了甚麼可以分享給他們呢？剛巧我的母語是普通話，在香港受教育，會普通程度英語，職業是醫療化驗師，醫療知識也頗片面。但如何落實，去為老百姓做點甚麼呢？

就在這個時候，在我同事組織的基督徒細胞小組的聚會中，出現天鄰基金會的傳單，上面描述的事工，與我的理想很接近。於是便馬上聯繫上，當時天鄰基金會很需要普通話翻譯，也是它成立的初期，仍在探索階段。還記得第一次去只是學術交流，我主要負責翻譯，自

Near the end of the last century, something shocking happened in Beijing. Many young people lost their lives. I felt lucky because I did not pay the price they paid, and yet I was enjoying what they fought for. Thus I felt that I should do something to serve the people in China. But what could I share with them? My native language is Mandarin. I was educated in Hong Kong and my English is average. I am a medical laboratory technician with limited medical knowledge. With this background, what could I do to serve?

During a Christian fellowship meeting at work I saw a pamphlet from the HIS Foundation. The ministry described in the pamphlet seemed close to what I was looking for. So I contacted the HIS Foundation and learned that they needed Mandarin translators. At that time, the HIS Foundation was still in its infancy and looking for directions to serve. I remember joining a medical team. My job was as an interpreter, but I also gave a lecture. I can still recall the tour of local hospitals. Before long I had opportunities to join dental teams, orthopaedic teams, and plastic surgery teams. Since then, I have been on a journey that has opened my eyes and enriched my life. My life has become more meaningful, and I now know God more intimately and understand myself better. This wonderful journey has changed my life.



作者很喜愛狗兒。

Author is a dog lover.

The first time I saw the dental team lay out their dental equipment, I thought the team had brought a dental clinic with them. Later, when I saw the surgical instruments and supplies of the surgery team, I was even more impressed. A whole operating room appeared to have been transferred to the mission field; in fact, they needed a truck for transportation. To get all the equipment and supplies ready in a timely manner is a daunting task. I met surgeons,



作者（左）與輪椅隊隊員合照。
Author (left) had photo with wheelchair team members.

己也負責其中一堂講課，並且也有機會參觀一些縣級醫院和衛生院。很快我參與了牙科隊、衛生教育隊、骨科隊和矯形外科隊。從此便開始了一個大開眼界的歷程，豐富了我的人生，並且通過個人醒悟自省，進深認識自己，並且認識神更多，隨之而又改變了自己。真是一個奇妙的旅程。

第一次見到牙科隊攤開牙科專用的器具時，像把整個牙醫診所搬過來。後來再看到手術隊的器材和醫療用品，原來是小巫見大巫，猶如把整個手術室搬到當地的醫院，要一整輛大貨車才運得完，並且還要及時在預定好的手術日前抵達。要在服事的地方準備好這些硬件，殊不是一件簡單的事，對我來說更是件不可能的任務。

anesthesiologists, operating room nurses, ward nurses, and physiotherapists. All of them were very senior in their professions and able to make independent decisions. They came from different hospitals, different cities, and different countries. Even though many team members were meeting for the first time, they worked smoothly and efficiently for two weeks and completed many operations. Indeed, the medical staff at the local hospital thought we were a team that had been working together for years.

In the beginning, the HIS Foundation sent one team per year. Later, three or four teams were sent every year, often to serve in different locations. Thus, it was impossible to have the same volunteers on each team. One of the lessons that our volunteers learnt was how to work together with strangers to accomplish difficult tasks. It was truly a miracle unfolded, and this happened because we shared the same religion, same beliefs, and same goals.

Meeting the patients was an astonishing experience. The orthopaedic team treated patients with upper and lower limb problems. At the screening clinics we met many patients with severe deformities who had great difficulties in walking. Even the local medical staff were surprised to see so many handicapped patients.

Our teams worked extremely hard, making the most of limited resources (manpower, supplies, and time) that we had. Even though the workload was 50% higher than the usual workload at home, everyone wanted to treat more patients. Therefore, the most heart-wrenching task was to comfort those patients and families that could not have surgeries, and explain why this was so. Many patients traveled long distances to the clinic, spending up to a day

此外，要籌集天鄰的手術隊員更具挑戰性，例如，要組合一個骨科隊，便要召集骨科醫生、麻醉科醫生、手術室護士、病房護士和物理治療師，天鄰的專業團隊，不但資深，而且還是具備獨立判斷能力的專才。他們來自不同醫院及不同的國家，要在短短的兩星期內合作完成數十台手術。很多時大家是在出發時才第一次見面，彼此都很陌生，卻能極速配合，常常令我們內地合作的對口單位，誤以為團員都是來自同一間醫院的員工。

天鄰每年出隊次數，由起初一年一、兩次發展到後來三、四次，去不同的地點，因此參與的醫療人員都不可能同一批人，以致天鄰的義工必須首要學會的功課，是如何極速與陌生的拍檔磨合，去共同完成艱巨的任務。這真是天鄰其中一個奇蹟，相信是因為大家有同一個信仰，同一個信念，同一個目標。

另一令我大開眼界的是病人，骨科隊服務的對象，主要是四肢有問題的病人。在篩選病人那天，門診擁滿了各種腿腳畸形，行動異常或不能走動的病人，連當地醫護人員也很驚訝，說有很多症狀未見過。

由於人力，物力和時間都很有有限，故此每次能服事的病人數目也很有限，團隊唯有把工作時間拉到最盡，工作量都是大家平常一倍半以上，期望能醫治多一個，便得一個病人。其中最艱鉅又費心的工作，就是要向被拒絕的病人和家屬解釋和安慰。他們每一家能到醫院求診都是來之不易，很多是來自鄉

to make the trip. Since the clinics started in the morning, many patients arrived the day before and stayed overnight. Thus a round trip could require three or four days. In addition, the travel, meals, and lodging added up to a considerable sum of money for many families. It was good news if a patient was admitted for surgery. Some patients, however, had conditions not amenable to an operation. Sometimes families kneeled and begged us to admit the patients for surgery. We had to pray to our Father and ask Him to give us appropriate and caring words to comfort these families. We also tried our best to offer non-surgical treatments. We hoped that our passion and encouragement would give them strength in facing the challenges in their lives.

Patients admitted to surgery usually remained in the hospital for five to ten days. No matter whether the patients were in the ward or in the operating room, we tried our best to understand their difficulties and to take care of them. We wanted to remove any barriers to surgery and recovery.

We often gave children a small present, perhaps a children's book to read, and we played games together. We arranged patient education sessions to inform patients about preparing for surgery and about postoperative care. We also provided education on health-related topics.

Patients with similar conditions frequently met in the wards. Patients and families took care of each other and talked to each other. Although evangelism is prohibited in China, the HIS Foundation volunteers witnessed by their actions. Patients and families were frequently curious about why we had traveled so far to provide them with excellent, free medical service. They had never seen people serve others so selflessly.

村，路途遙遠，要花半天或一天才能抵達。門診由早上開始，有些人早一天就來到。家屬和病人的旅費、食宿費也不少，還要花兩、三天來回，真夠折騰了。能排得上，固然開心，但手術不是萬能的，有些病人的身體狀況即使動手術也是不能矯正。有些病人家屬甚至會跪下請求，我們只好用愛心說誠實話，祈求天父賜下合宜的言語。我們也盡量提供非手術的醫療方案去改善他們的病情，又予以肯定，鼓勵和關懷，讓他們能正面接受現實，有盼望的活下去。

對於能得到手術機會的病人，我們可以與他們相處五到十天。無論在病房或手術室，我們天鄰團隊的醫護隊員都盡量關懷他們，了解他們的需要，幫助他們解決阻礙做手術的困難。對於兒童病人，還會送他們小禮物，安排圖書借讀，玩遊戲等等。另外也安排病人教育，給予他們術前、術後須知和一些衛生常識。

同病相憐的病人都住在同一病房，病人的家屬都可以留下照顧病人，大夥一起聊聊天，雖然當局不允許直接傳福音，我們抓緊機會以生命影響生命。他們特別好奇，為何世界上有人會無條件，不收手術費，去幫助他人？其中有位病人家屬說，他們一輩子都是過苦日子，這樣美好的事件怎會輪到自己的家呢？直到他看到患相同病況的同鄉得醫治，且效果很好，才憑著信心帶自己病了的孩子上路，剛巧當天就被安排上手術名單上，他太開心了。我們期盼病人和家屬透過我們的服事，體會神的愛是具體且真實

I recall a time when a patient's family member said that she had endured a long and difficult life, and that she never thought anything good could happen to her family. Then she discovered that someone in her village had been treated by the HIS Foundation with good results. So the woman brought her handicapped child to the HIS Foundation and was so pleased when the child was admitted for surgery. She realized that God's love was true and practical, and she remained happy during her stay in the hospital.

After surgery, patients received first-rate postoperative care. Patients and families had never experienced the kind of encouragement and caring attitude offered by our medical staff. Pain at the site of surgery is common, but with the hope of improvement and cure, most patients managed to tolerate the pain and discomfort.

We hoped that the local medical staff and hospital officers could see the witness we bore as Christians, and the love of God. We wished that the seeds we had sown would one day grow in their hearts.

On each mission trip we enjoyed a dinner with the local medical staff. The highlight was when Dr. Lau shared the results of orthopaedic treatment. It was truly a touching moment. We saw how patients' conditions had improved after surgery. Some who had been home-bound and unable to walk were now walking independently. After treatment, some could go to school or seek employment. To see the lives of so many patients completely changed for the better was deeply gratifying. We hoped that people understood and appreciated this labor of love and would come to know Christ one day.

"Unless the Lord builds the house, those who

的，並不只是嘴巴說說而已。他們分享在醫院的日子過得很開心，得到從未有過的關懷，雖然術後傷口很痛，復健也相當辛苦，但是由於有了醫治的盼望，就產生忍耐堅持下去的力量。

透過與對口醫護人員，領導和一些官員的接觸，我們也深盼他們可以從隊員身上看到神的愛和真實，有如種子般撒在他們的心田上。每次在招待他們的聯歡會上，劉漢杰醫生都會分享病人術後的成果，那是最感動的時刻，特別看到術前術後的改變，病人從不能走路，變成可以自由行動，能夠自理，甚至完成學業，可以謀生，大家都深受感動。病人得醫治後，連生命也有改變。我們祈許這些感動能像種子般在他們心裡茁壯成長，終於有一天，可以明白真理，得救重生。

「若不是耶和華建造房屋，建造的人就枉然勞力。若不是耶和華看守城池，看守的人就枉然儆醒。」（詩 127:1）那麼多年過去了，我深深體會，如果沒有神的保守帶領，我們所作都可以枉然。我很榮幸，可以有份參與其中，不單止見證神奇妙的恩典，而且自己也得到造就，完成了很多在我看來不可能的任務。衷心感謝主，也感謝並肩作戰的隊友們的肯定和鼓勵。

作者（左）接受感謝證書。

Author (left) received a certificate of appreciation.

build it labor in vain. Unless the Lord watches over the city, the watchman stays awake in vain" (Psalm 127:1). After many years of ministries, I fully realize that it was our Lord who led us and protected us, otherwise what we did would have been in vain. I am honored to be part of the ministry, a ministry which has accomplished so many wonderful works, including things I had thought impossible to achieve. Not only did I witness the marvelous works of our Lord, but I was also built up spiritually. Besides praising the Lord, I also appreciated the encouragement of other team members and their affirmation of my work.



中國醫療傳道與天鄰醫療事工

Medical Missions in China and HIS Foundation Medical Services

劉漢杰 小兒骨科醫生

James Lau, MD Pediatric Orthopaedic Surgeon

西醫在中國的起源

西教士對西方醫學傳入中國，及其初期的發展息息相關。早期的宣教士使用醫療服務和社會關懷（例如：反對販賣鴉片、照顧孤兒），來打開中國福音之門。馬禮遜（1782-1834）是第一位更正教派來中國之宣教士，他來華之前，就曾經在倫敦的聖巴塞洛繆醫院，學習醫科兩年，作為宣教的裝備。他在中國雖然沒有親自行醫，但卻設立了第一所基督教診所，並委任約翰·利文斯通醫生為診所主診。

彼得·帕克醫生（1804-1888）是來華第一位正式醫療宣教士，他於美國耶魯大學取得神學（1831）及醫學學位（1834），於1834年被按位為長老會牧師，並於同年由美國差會差派到中國宣教。他於1835年在廣州設立普愛醫院，常被稱為眼科醫院，為廣州醫院的前身。

帕克醫生見到當時有許多眼疾患者，中醫往往不能提供有效治療，故專注處理眼科病症。帕克醫生切除白內障的手術成為一時佳話。此外，帕克醫生又做了很多切除腫瘤的手術，他是第一位將麻醉技術傳入中國（1847）的醫師。

The Birth of Western Medicine in China

The introduction of western medicine into China and its early development was closely related to western missionaries. In early years, missionaries frequently used medical and social services (e.g., anti-opium campaign, taking care of orphans) as means of evangelism. Robert Morrison (1782-1834) was the first Protestant missionary to China. He studied medicine for two years at St. Bartholomew's Hospital in London before he left for China. He was the first Christian to start a clinic in China. Although Morrison did not practice medicine, he appointed Dr. John Livingstone to run the clinic.

Peter Parker (1804-1888) was the first medical missionary to China. He graduated from Yale University, earning a theology degree in 1831 and a medical degree in 1834. Parker was ordained as a minister by the Presbyterian Church in 1834 and sent by the American Board of Commissioners for Foreign Missions to China in the same year. He founded the Pu Ai Hospital in Canton in 1835. Commonly called the Eye Hospital, it later became the Canton Hospital.

Dr. Parker saw many patients with eye conditions who could not be treated by Chinese medical doctors. Therefore, he specialized in ophthalmology and became famous for performing cataract surgeries. Dr. Parker also excised many tumors. Significantly, he

美國長老會於1854年差派嘉約翰醫生繼承成帕克醫生的工作。嘉約翰醫生是一位著名的外科醫生，他在中國建立了首間西醫學院，有系統地引入西方醫學。此外，他也創立了中國第一間精神病院。

自從帕克醫生成立第一所醫院以後，醫療宣教士在中國各地建立了很多醫院，依據麥克斯韋爾醫生的調查報告，到1931年為止，宣教士所創辦的醫院一共有215間，病牀共16,149張，外藉醫生共317位，住院病人共90,843位，而門診人數達3,468,465人。

當時中國有22間醫學院，其中8間為醫療宣教士所創立，包括北京協和醫學院、聖約翰大學醫學院、華西大學醫學院、山東基督教醫學院、瀋陽醫學院、夏葛女子醫學院、基督教女士醫學院及湘雅醫學院等。

天鄰基金會的使命

天鄰基金會的醫療隊和輪椅隊，是用免費的醫療服務來見證神的大愛和福音的大能，這宗旨及事奉精神與醫療宣教士所做是如出一轍的。奇妙地，與天鄰醫療隊合作提供服務的醫院中，有三間的前身就是宣教士所創立的醫院。

洛陽市第一人民醫院

這是一間有百年歷史的市級綜合醫院，其前身是美國和意大利宣教士，分別在1910年及1911年所創辦的福音醫院和聖心醫

introduced the art of anesthesia to China in 1847.

In 1854, the Presbyterian Church in America sent a medical missionary, Dr. John G. Kerr (1824-1901), to continue the work of Dr. Parker. Dr. Kerr was a famous surgeon, and he established the first medical school in China. He systemically introduced western medicine to China and founded the first institute for the treatment of psychiatric conditions.

After Dr. Parker founded the first hospital in China, missionaries established many hospitals. A survey carried out by Dr. J. L. Maxwell in 1931 counted 215 mission hospitals, 16,149 beds, and 317 foreign doctors, treating a total of 90,843 inpatients and 3,468,465 outpatients. Of the 22 medical schools in China, eight were founded by missionaries: Peking Union Medical College, University of St. John Pennsylvania Medical School, West China Union University Medical School, Shantung Christian University Medical School, Mukden Medical College, Hackett Medical College for Women, Woman's Union Christian Medical College in Shanghai, and Hsiang-Ya Medical College.

Medical Missions of HIS Foundation

The main objective of the HIS Foundation medical and wheelchair teams is to witness the love of Christ and the power of the gospel by rendering free services to those in need. This is in line with the commitment demonstrated by medical missionaries in the past. Interestingly, three of the hospitals that partnered with HIS Foundation were initially founded by missionaries.

Luoyang Number One Renmin Hospital

This is a century-old general hospital at the city level. An American missionary founded a Gospel Hospital in 1910, while an Italian

院，1951 年兩所教會醫院被洛陽市人民政府接收後，合併成立洛陽市人民醫院。在 1965 年，按建院年序，將該院改定為洛陽市第一人民醫院。1991 年被命為洛陽市唯一一家“紅十字”醫院（圖 1）。天鄰的骨科隊及整形外科隊曾於 1998 至 2004 年到該院義診及做手術。

大理市第二人民醫院

該院的前身是福音醫院，是由宣教士於 1938 年 7 月建立的，亦是當地最早的一家醫院（圖 2），座落在大理古城之內，北面城門旁。經過了七十餘年的拆毀和重建，一間簡單的醫院已變成一所擔負著大理市北區及周邊地區 20 多萬人口的醫療中心（圖 3）。該院的骨科和整形外科發展比較慢，天鄰醫療隊正好在這方面補其不足，為小兒麻痺、腦癱、先天性骨科疾病、脊椎裂、燒傷及免唇裂顎等病者提供優質服務。有人認為是歷史的巧合，但我卻相信是神的主宰和美意，一間本已被遺忘的福音醫院，走過了 70 年的風雨歷程，神將祂的

圖 2 Photos 2



原大理福音醫院。

The original Gospel Hospital in Dali.

圖 1 Photos 1



洛陽市第一人民醫院。

Luoyang Number 1 Renmin Hospital.

圖 3 Photos 3



現在的大理第二人民醫院。

Dali Number 2 Renmin Hospital.

圖 4 Photos 4



在天鄰手術隊及輪椅隊在大理第二人民醫院服務。

HIS Foundation surgery team and wheelchair teams served at Dali Number 2 Renmin Hospital.

兒女帶回當中，繼續昔日救傷扶危的使命。天鄰手術隊的服務，由 2010 年開始，至 2018 年完結（圖 4-5），其間又以該院為基地，發展了雲南的輪椅捐贈事工，及麻瘋康復村的工作。

瀘州福音醫院

1913 年，來自加拿大安大略省的傳教士李芝田牧師和福古森醫生，在四川瀘州市成立了該市的第一所西醫醫院—瀘州福音醫院。該院用現代西醫技術救治戰爭傷者，效果顯著，令該院骨科聲譽鵲起。1938 年，福音醫院遭日本飛機轟炸停診，翌年在原址重建，應當時國民政府要求，更名為基督教瀘州仁濟醫院。



圖 5 Photos 5

圖 6 Photos 6



瀘州福音醫院與解放軍二野醫院合併前醫院員工合照。

Group photo of medical staff of Luzhou Gospel Hospital before it merged with People Liberation Army Number 2 Hospital.

圖 7 Photos 7



瀘州福音醫院旁的瀘州基督教會。

The Luzhou Christian Church is located next to the Luzhou Gospel Hospital.

missionary established a Sacred Heart Hospital in 1911. In 1951, the city government took over the two hospitals and merged them to form the Luoyang Renmin Hospital. In 1965, the hospital was renamed Luoyang Renmin Number 1 Hospital. In 1991, the hospital was the only hospital in Luoyang dedicated as a “Red Cross Hospital.” (Picture 1)

HIS Foundation sent orthopaedic and plastic surgery teams to the hospital from 1998 to 2004 to provide free medical care, including surgeries.

Dali Number Two Renmin Hospital

This hospital was founded by a missionary in July 1938. Named The Gospel Hospital, it was the first hospital in the city (Picture 2), located inside the old town, next to the north city wall. Over a period of 70 years, the hospital underwent demolition and reconstruction. Today the hospital is a medical center caring for about 200,000 people in the northern part of Dali (Picture 3). The orthopaedic and plastic surgery departments of the hospital were not well developed, but the HIS Foundation was able to remedy this deficiency. HIS Foundation medical teams took good care of patients with post-poliomyelitis deformities, cerebral palsy, congenital limb anomalies, myelomeningocele, burns, harelips, and cleft palates. Some may feel that this is a coincidence in history, but I believe this is God’s will and blessing. After 70 years of difficult history, a long-forgotten missionary hospital resumed its old mission and became a center where God’s children returned. HIS Foundation surgery teams served from 2010 to 2018 (Picture 4-5). During this period, the hospital also became a center for wheelchair donations and a leprosy rehabilitation village program.

1950 年，中華人民共和國政府將福音醫院和解放軍二野醫院合併（圖 6），成立了川南醫院，後發展成為瀘州醫學院附屬醫院。該院於 2011 年在原址重建，取用舊名瀘州福音醫院，並歸入西南醫科大學附屬醫院系統。醫院歸瀘州基督教會所管理，教會的會址正在醫院旁（圖 7），該院堅持濟困扶弱的傳統，常為貧困病者減免費用。天鄰骨科隊於 2017-2018 年曾到該院義診和做手術（圖 8）。

結語

醫療傳道，無論在一百多年前的中國，或今天的宣教禾場，都是一個模仿耶穌基督周遊四方，醫治各樣的病症的有效傳道模式（馬太福音 9:35）。

圖 8 Photos 8



天鄰手術隊 2018 年在瀘州福音醫院義診及做手術。

HIS Foundation surgery team served at Luzhou Gospel Hospital in 2018.

Gospel Hospital in Luzhou

In 1913, the Canadian missionary Rev. Charles Jolliffe and a medical doctor, Dr. Ferguson, founded the first hospital in Luzhou, Sichuan Province. It was named the Luzhou Gospel Hospital. The hospital became well-known for its good results in treating war victims with western methods. In 1938, unfortunately, the hospital was destroyed by Japanese air bombing. Rebuilt the next year, upon the request of the government the name of the hospital was changed to Luzhou Yan Chai Christian Hospital.

In 1950, the Gospel Hospital merged with the People’s Liberation Army Number Two Hospital to form a new Chuan Nan Hospital (Picture 6). The hospital was subsequently turned into a teaching hospital for the Luzhou Medical School. The hospital was rebuilt on the original site in 2011 and given its old name, Luzhou Gospel Hospital. This hospital is included in the Southwest Medical School system and became one of its teaching hospitals. The hospital was later handed over to the Luzhou Christian Church to manage (Picture 7), and the two buildings are located side-by-side. The hospital maintains its tradition of serving the poor. Many times, treatment fees are lowered or waived. The HIS Foundation orthopaedic team provided a free clinic and surgeries at the hospital from 2017-2018 (Picture 8). Further teams were unable to go due to the Covid-19 pandemic.

Conclusion

Medical missions, whether in China over a century ago or in mission fields today, model the example of Jesus by traveling far and healing illnesses. This caring work is an effective means of spreading the good news of God’s Kingdom (Matthew 9:35).

什麼是最好

張藝紅 手術室護士



什麼是最好
就是能夠結識同伴
大家懷有共同心願
共同服侍共同付出

什麼是最好
就是大家都看見雨後的彩虹
漂亮地高掛在大理的天空上

什麼是最好
就是一起經歷神的恩典和慈愛
傳頌祂的話語
將榮耀全歸祂

什麼是最好
就是一起歡笑拍掌
一起傷心流淚
一起共享喜與悲

什麼是最好
就是看見憂愁的臉孔
轉變為燦爛的笑容

什麼是最好
就是看見生命的改變

什麼是最好
就是看見殘疾
得到最好的醫治和看顧

什麼是最好
就是生命影響生命

什麼是最好
就是伙伴同行
生命承傳

什麼是最好
就是與一班最美麗的人
去一個最美麗的地方
做一件最美麗的事情

What Could be the Best?

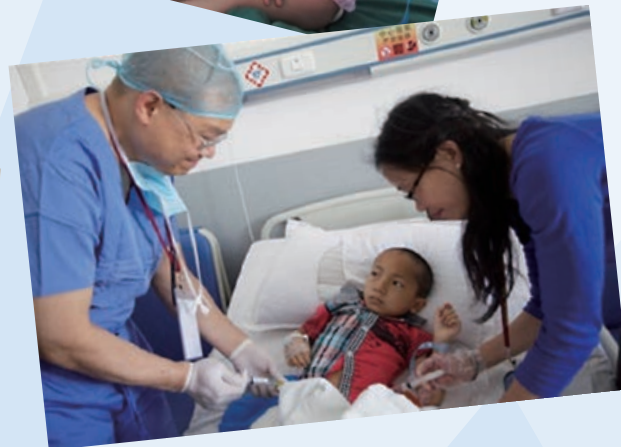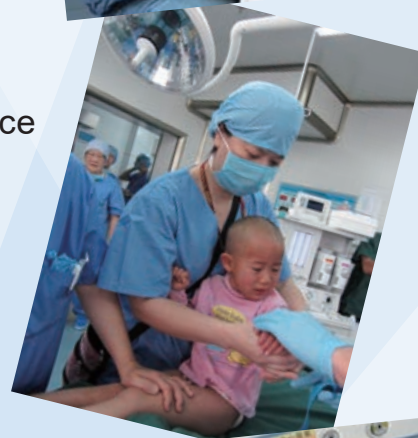Joey Cheung Operating Room Nurse
Translation by **James Lau**

What could be the best?
That's getting to have friends
With the same vision
Serving and giving together.

What could be the best?
That's when all of us see the rainbow after
shower
Hanging over the sky of Dali.

What could be the best?
That's when we all experienced God's grace
and love
Praising His holy words
Glorifying Him.

What could be the best?
That's when we all clapped with joy
All cried and grieved together.
We share our joy and sorrow.



What could be the best?
That 's when we see saddened faces
Transformed into brilliant smiles.

What could be the best?
That's when we see the handicapped
Get the best care and cure.

What could be the best?
That's when one's life is casting impact on life of others.

What could be the best?
That's when we walk together
Passing on heritage.

What could be the best?
That's when we keep company with the most charming friends.
We go to the most beautiful place.
Together, we performing the most amazing task.



庫爾德斯坦難民工作簡介 Refugee Ministries in Kurdistan

劉漢杰醫生

James Lau, MD



難民營一景。

A scene in refugee camp.

雅茲迪人及其信仰

雅茲迪人是一群住在伊拉克北面的小數族群，他們有很長遠的歷史，而他們所相信的宗教是一個古老的信仰，其中混合了拜火教、基督教和回教的成份。在他們的傳說中，神創造天地之後就將大地交給七位天使管理，天使長曾經因為犯罪而被打入地獄。但後來恢復職位。雅茲迪人的鄰居多數是回教徒，一些回教徒認為雅茲迪人所敬拜的天使長其實是魔鬼，所以很憎惡他們。雅茲迪人因為信仰的緣故，多次被迫害，甚至種族清洗。

種族清洗、淪為難民

在 2014 年，伊斯蘭國武裝分子，突然圍攻雅茲迪人聚居的城市 Sinjar 和附近的村莊，殺死數以千計的男人，又將幾千名婦女和兒童俘虜。年輕的女人多被迫做性奴隸，部分的男孩就被洗腦，訓練成兒童軍人。數以十萬計的

Yazidi and Religious Belief

Yazidi is a minority group that lives in the northern part of Iraq. They have a long history. They believe in an old religion. It is a mixture of Zoroastrianism, Christianity, and Islam. In their legend, God created the earth and entrusted it to seven angels to manage. The archangel committed sin and was thrown into Hell. Later he was restored to his original position. The neighbors of Yazidi are mostly Muslims. Some Muslims believe that the angel worshipped by Yazidi is the Devil. Therefore, they hate the Yazidi. The Yazidi suffered many persecutions due to their religious belief, including ethnic cleansing.

Ethnic Cleansing and Diaspora

In 2014, the militia force of ISIS suddenly attacked Sinjar and the neighboring villages where the Yazidi lived. Thousands of men were murdered. Thousands of women and children were captured. Young women were forced to become sex slaves. Some boys were indoctrinated and trained to be child soldiers.

雅茲迪人慌忙逃命，不少人在走難時被殺或因為疾病和饑餓而死亡，很多難民輾轉逃到庫爾德斯坦地區，因為雅茲迪人在種族上與爾德斯坦人相近，庫爾德斯坦人有軍隊，能夠抵抗伊斯蘭國武裝分子。

聯合國在當地設立了 23 個難民營，給雅茲迪人棲身。但因為難民人數太多，難民營有人滿之患，所以不少難民不能入住難民營，只能住在帳篷或被棄置的房屋裏。

伊斯蘭國武裝分子幾年後被美軍和聯軍打敗，但雅茲迪人的家鄉已經被嚴重破壞，而且當地局勢不穩定，依然有衝突事件，令到大部分難民不敢歸家。

基督徒的回應

雅茲迪人被種族清洗的消息引



雅茲迪婦女與醫療隊工作人員（右二）在難民營內合照。

Yazidi women and a medical volunteer (second from right) had a photo taken together inside a refugee camp.

Hundreds of thousands of Yazidis escaped for their lives in panic. Many were killed on the way or died due to diseases or starvation. Many refugees eventually arrived at Kurdistan. Yazidi is ethnically closed to the Kurds. The Kurds have military force and resisted the aggression of ISIS.

The United Nations established 23 refugee camps for the Yazidi. However, the refugee camps are full, and many are not able to get into the camps. For those that were not able to live in refugee camps, they can only live in shelters or abandoned houses.

A few years later, ISIS was defeated by US and alliance forces. However, the hometowns of Yazidi are badly ruined. The local situation is unstable, and conflicts are still occurring. Most of the Yazidi are not able to return home.

Christian Responses

Ethnic cleansing of the Yazidi got the attention of international community. Some Christian and humanitarian organizations provide relief efforts.

God inspired a group of Christians in Southern California. A new Christian organization called Habibi-International was raised. Habibi means friends. Many Christians responded to the calling of Habibi-International. Different types of short-term mission teams were formed to help the refugees. The internal medicine teams provide general medical and preventive care. The dental teams offer treatment and

起國際社會的關注，一些人道組織和基督教組織都提供援助。

神感動了一班在南加州的信徒，興起一個新的基督教團體名叫 Habibi-International。Habibi 就是朋友的意思。很多基督徒響應 Habib-International 的呼籲，組織成不同的短宣隊去幫助難民。短宣隊中有內科隊，主要是提供一般性的保健和醫療服務，牙科隊為很多病人處理牙病及教導牙齒保健常識，婦女探訪隊專門關懷受創傷的婦女，教育隊為兒童提供康樂活動和教授英語及電腦課程。這些雪中送炭的行動，幫助了很多流落異鄉的難民，打動了不少雅茲迪人的心。

天鄰基金會的參與

2019 年，美國天鄰基金會應 Habibi-International 的邀請，派出兩隊骨科手術隊及兩隊骨科覆診隊，為難民提供免費手術和物理治療等服務。骨科隊隊員包括骨科醫生、麻醉科醫生、護士和物理治療師等，雖然大部分是美國隊員，但亦有小數來自澳洲和香港的義工參加。

醫療隊得到當地政府的支持，可以免費使用一間政府醫院為病人做手術。但當地醫院設備不足，因此醫療隊帶備了很多手術儀器和醫療用品，而部分藥物就在當地購買。來就診的病人很多，門診大排長龍，很快手術項目就排得滿滿的，未能夠排上手術的病人就只能夠安排在下次骨科隊再來的時候才接受治療。

病人當中包括很多下肢殘疾的



一個雅茲迪家庭與醫療隊隊員在家中合照。

A Yazidi family had photo taken in their home.

preventive dental care. Lady visitation teams provide care for many traumatized women. Education teams render recreational programs and teach English and computer skills. Many refugees are helped by these relief efforts. They are deeply touched.

HIS Foundation Medical Mission Teams

In 2019, upon invitation of Habibi-International, HIS Foundation sent 2 orthopaedic teams and 2 orthopaedic follow up teams. The services provided include surgery and physical therapy. Team members included orthopaedic surgeons, anesthesiologists, nurses, and physical therapists. Most team members were from the United States with small number of volunteers came from Australia and Hong Kong.

The orthopaedic teams were supported by the local government. They were allowed to use a government hospital free of charge. The medical equipment of the hospital was insufficient. Therefore, the teams brought in large number of medical equipment and supplies. Some of the medications were purchased locally.

患者，例如馬蹄內翻和腦癱等。當地很多女孩子都有先天性髖關節脫臼，骨科手術對很多病人幫助很大，能夠把變形的部位矯正，令走路改善或回復正常，生活能夠自理。

急須援手

組織醫療隊需要很多人力和金錢，我們渴望更多基督徒的醫護人員加入我們的行列。非醫護人員亦可以參與，因為醫療隊部分的工作例如文書、物資管理、攝影，是沒有醫學訓練的義工亦能夠參加的。

此外一些教育隊和探訪隊亦適合非醫護人員參與。有經濟能力的，可以考慮用金錢奉獻來支持醫療隊和其他服務隊的工作。馬太福音第 25 章，耶穌說“作在一個最小的弟兄身上，就是作在我身上了”。雅茲迪難民可以說是天涯淪落人，是很需要人去關心他們，你願意成為好撒瑪利亞人，去幫助他們嗎？



在難民營診所外等候的病人。

Patients waiting outside the refugee camp clinic.

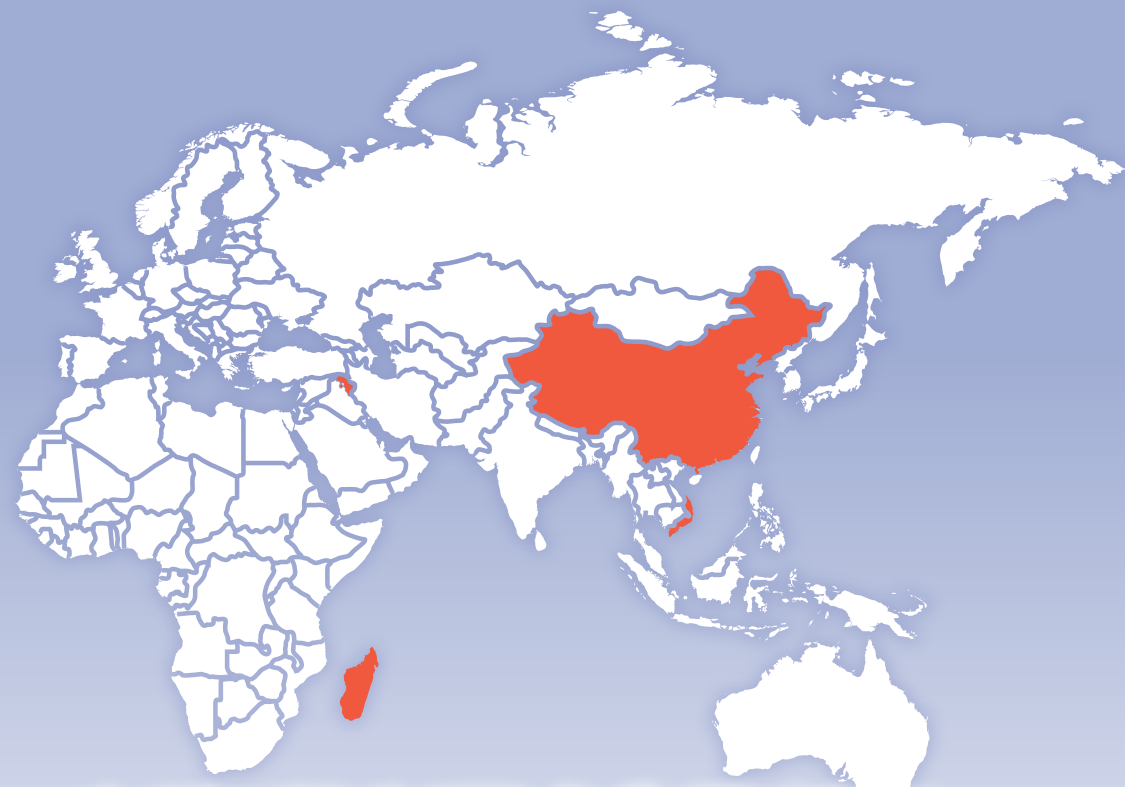Many patients came for treatment. There were long queues at the clinics. The operation schedule was quickly filled up. Patients that could not get on the surgery schedule had to wait for the next orthopaedic team.

Many patients have lower limbs deformities including those with clubfoot and cerebral palsy. Congenital dislocation of hip is very common among girls. Orthopaedic surgeries are very beneficial to the patients. Surgery can correct the deformities and allowed patients to walk better or normally. Some after surgery were able to take care of themselves.

Urgent Help Is Needed

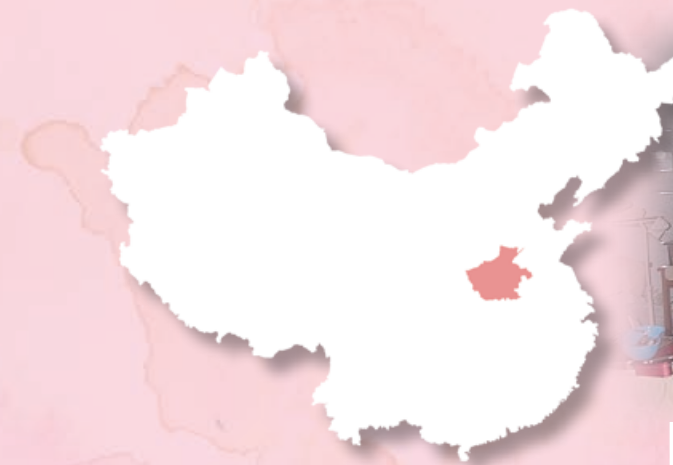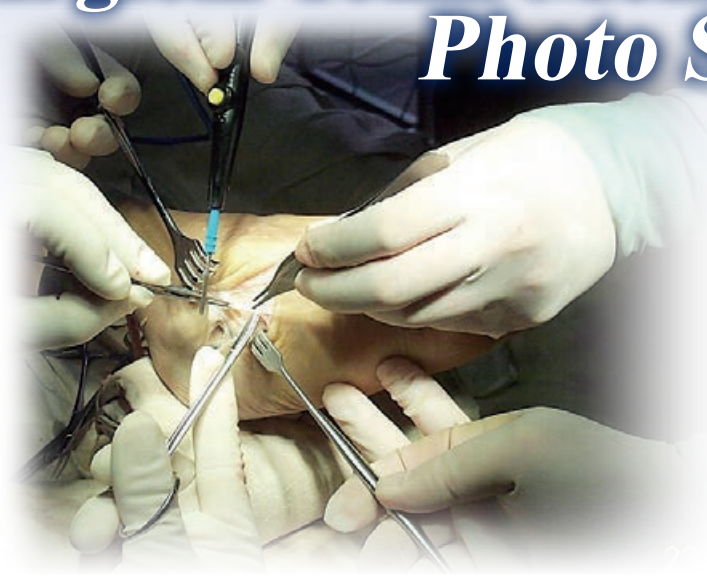
A lot of money and manpower are needed to organize medical teams. We hope that more Christian medical professionals can join our teams. Non-medical people can also join the teams because positions such as secretary, logistics manager, and photographer do not need medical training. Education teams and visitation teams also need non-medical volunteers. One can also donate money to support medical and other teams.

In chapter 25 of the Gospel of Matthew Jesus stated that “whatever you do on one of the least, you are doing that on me”. The Yazidi are people in great distress. They need people to care for them. Are you willing to be the Good Samaritan to help them?



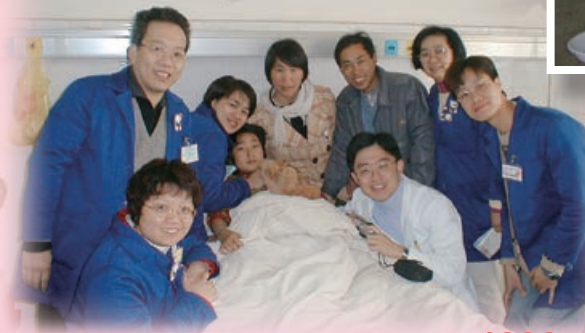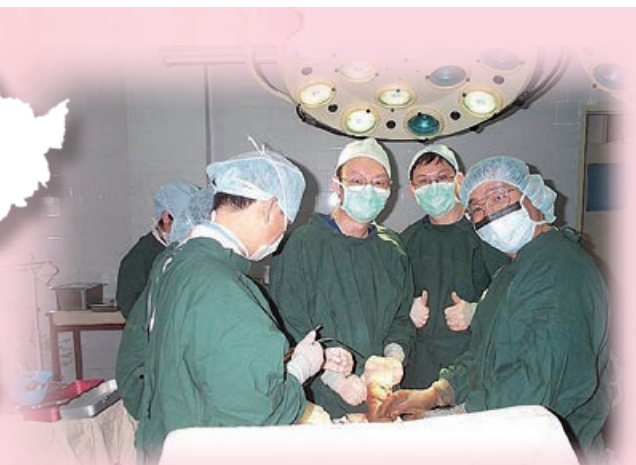手術隊員剪影篇

Surgical Team Members Photo Section



河南篇

Section Henan



洛陽骨科隊
Luoyang Orthopaedic Team

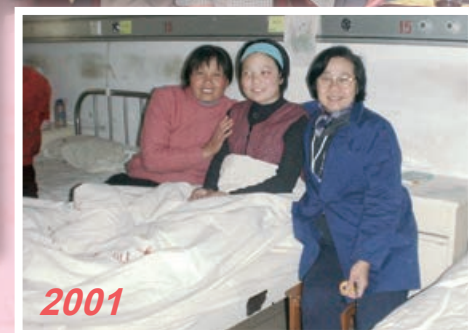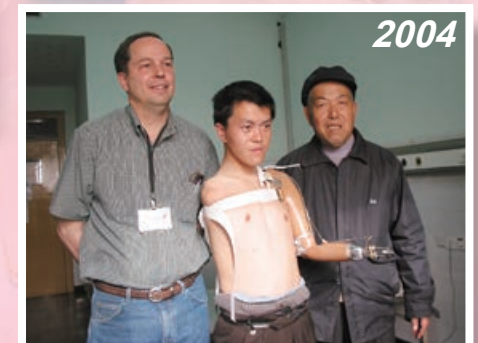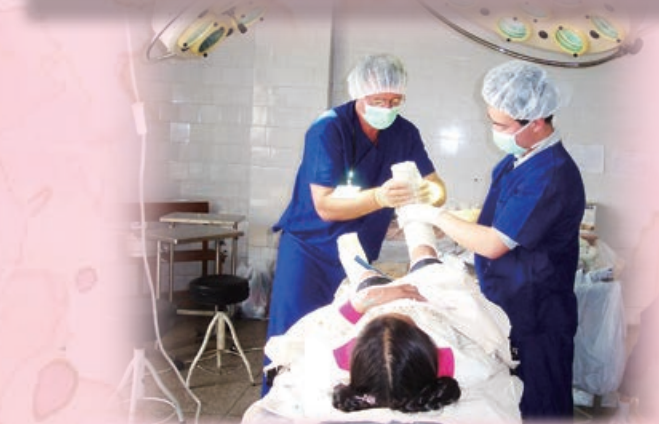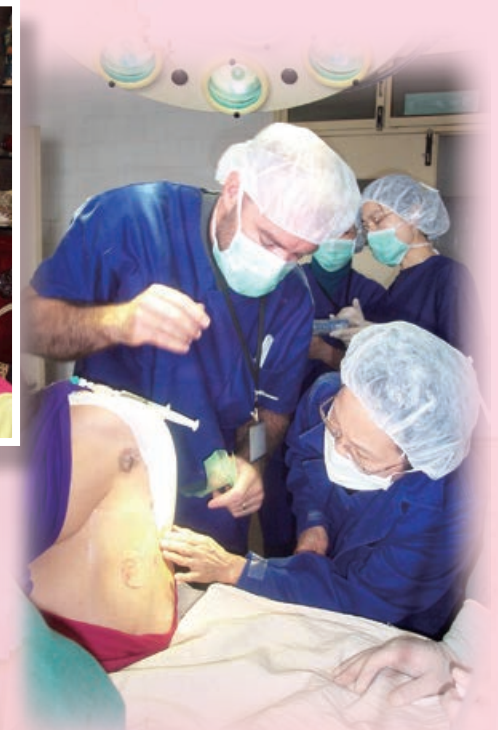1999

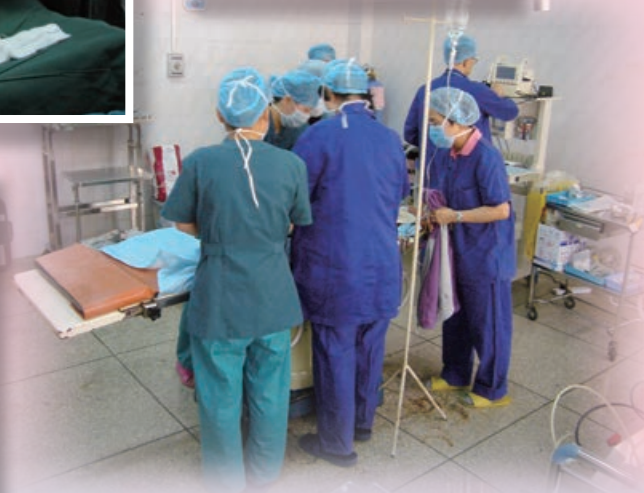
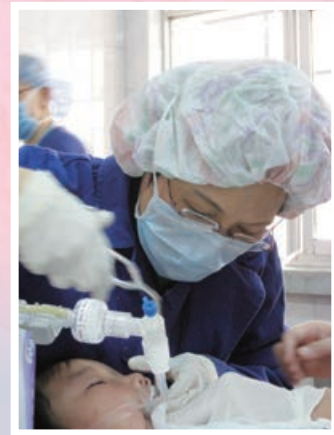
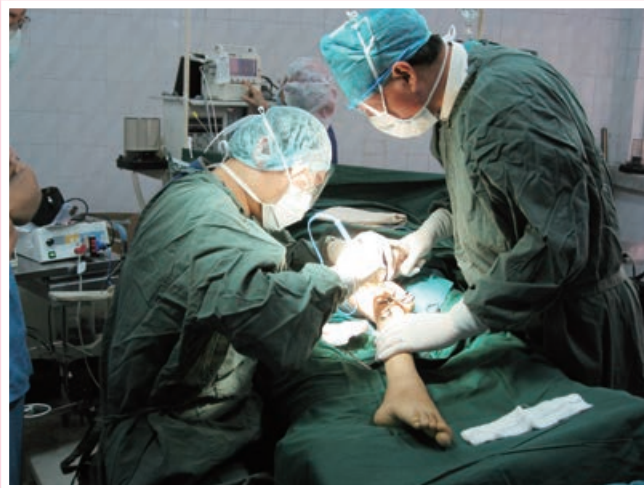1999

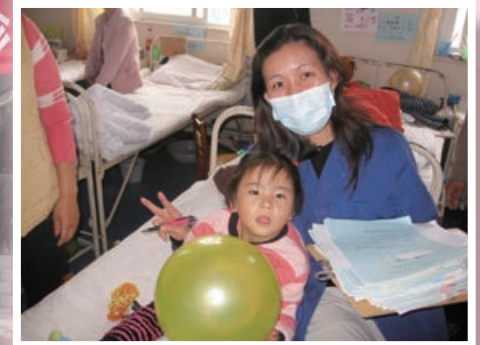

宜陽縣診所
Yiyang Clinic



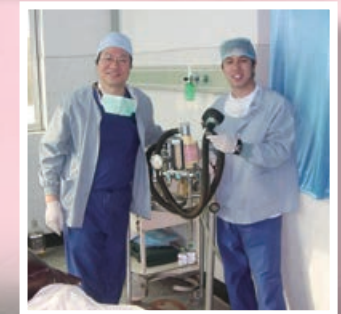
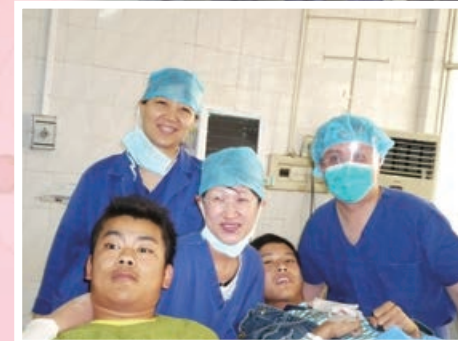
迎香港天鄰基金會來院义诊



2004

駐馬店骨科隊
Zhumadian
Orthopaedic Team



2009





中國紅十字會沁陽醫院



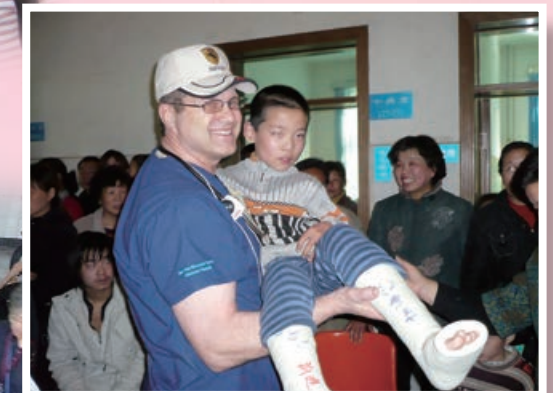檢討會
Evaluation

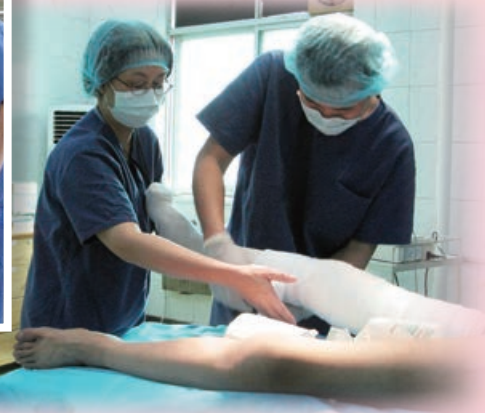
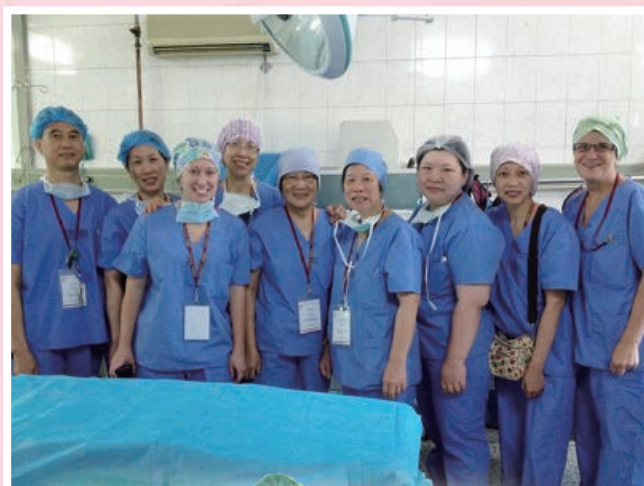
2005

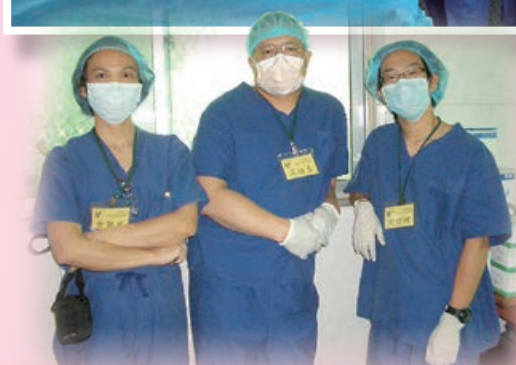
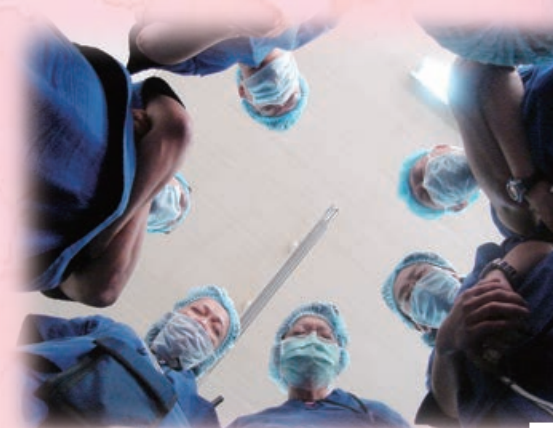
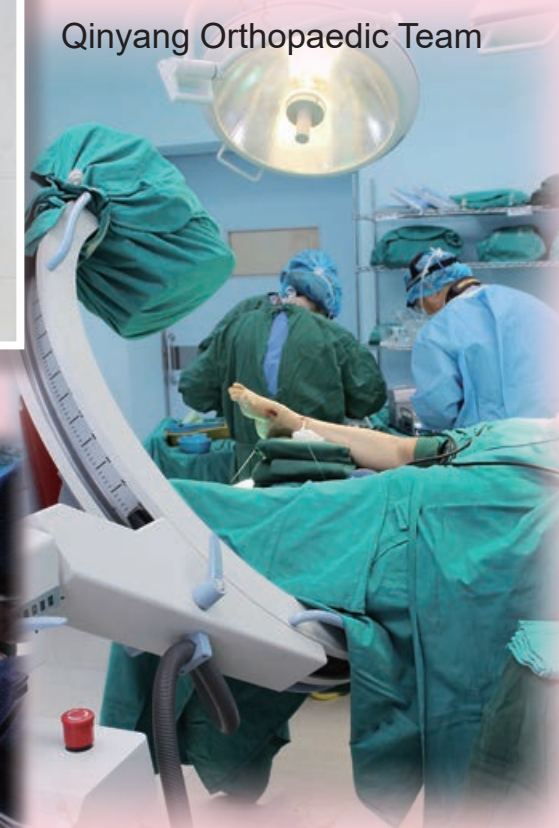沁陽骨科隊
Qinyang Orthopaedic Team

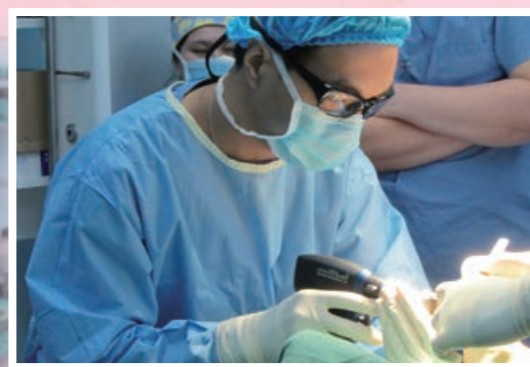
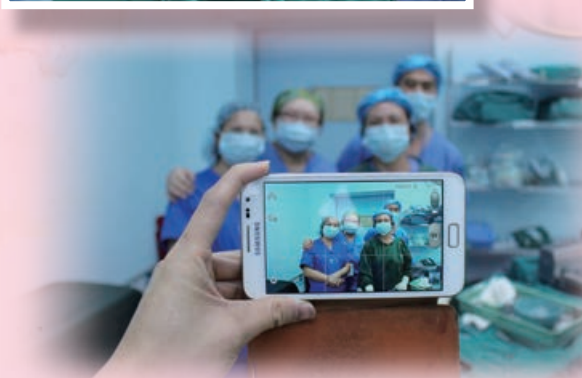
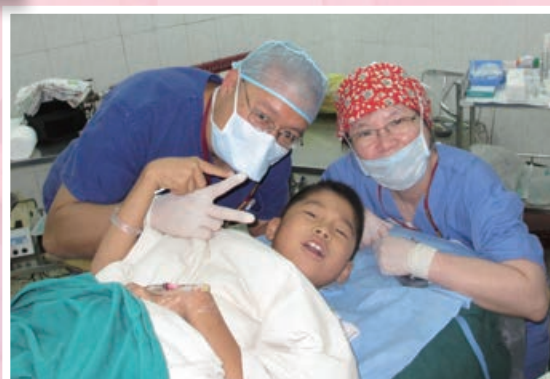
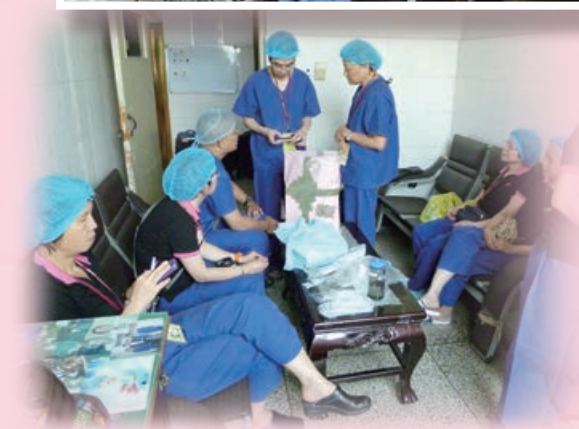
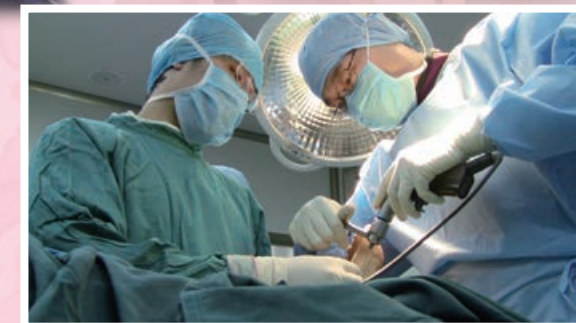
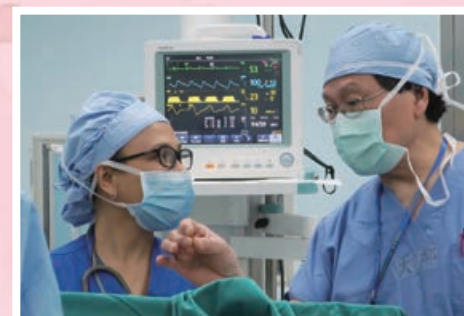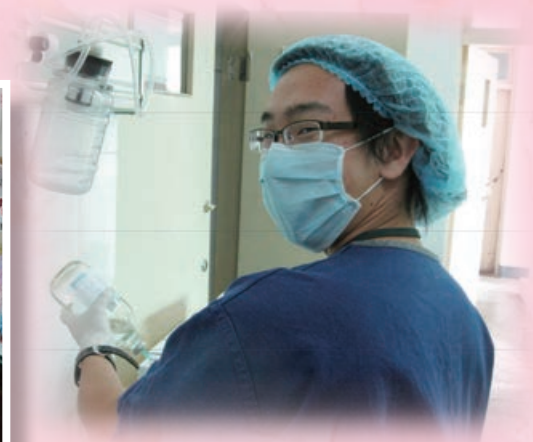沁陽骨科隊
Qinyang Orthopaedic Team



沁陽骨科隊
Qinyang Orthopaedic team



热烈欢迎香港天邻眼科、骨科医疗队莅临我院开展慈善助残手术



沁陽骨科及
眼科手術隊
2014

Qinyang orthopaedic
& Ophthalmology
Team 2014

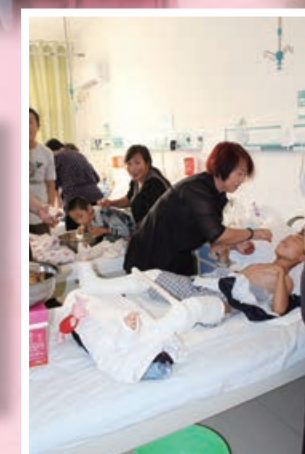天鄰骨科及外科醫生
orthopaedic &
General Surgeons



沁陽骨科隊 2015
Qinyang orthopaedic
Team 2015



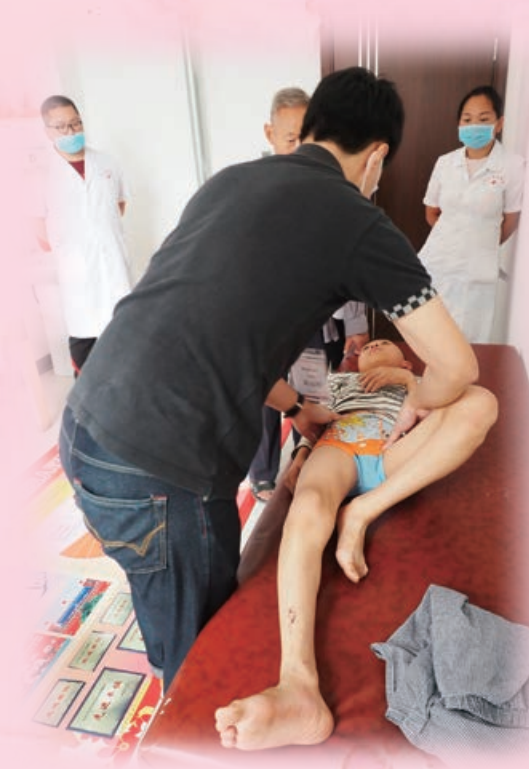沁陽肥雞餐
Qinyang Chicken
Feast



骨科門診
orthopaedic Clinic



沁陽骨科隊
Qinyang orthopaedic Team



告別會
Farewell



感謝信
Letter of Appreciation



2015年香港天鄰患者告別會




2007



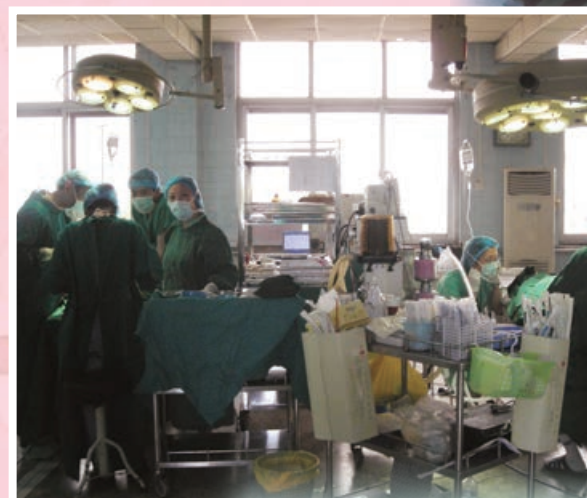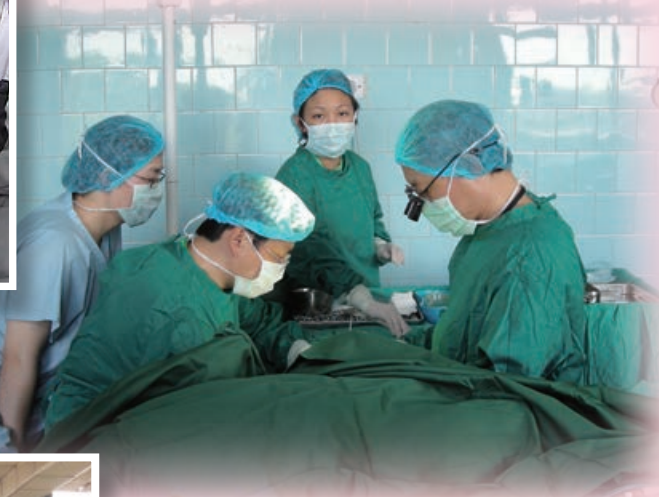2013



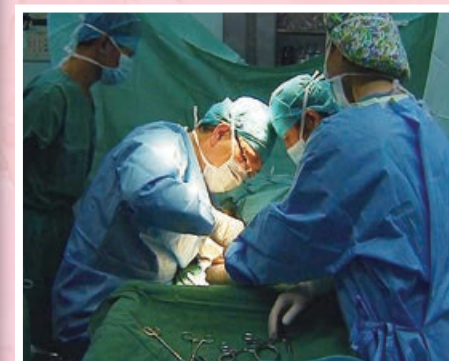安陽骨科隊
Anyang Orthopaedic Team



安陽骨科隊
Anyang Orthopaedic Team

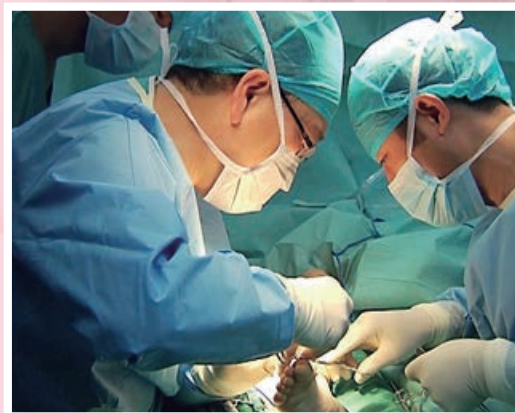

2007



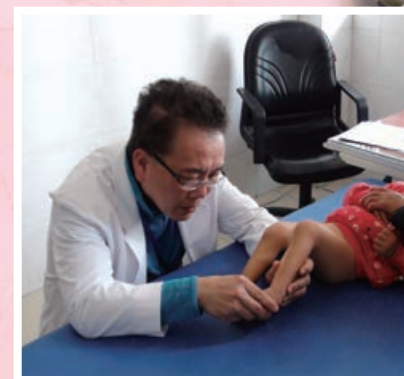2012





2016

滑縣骨科隊
Hua Orthopaedic Team



2017

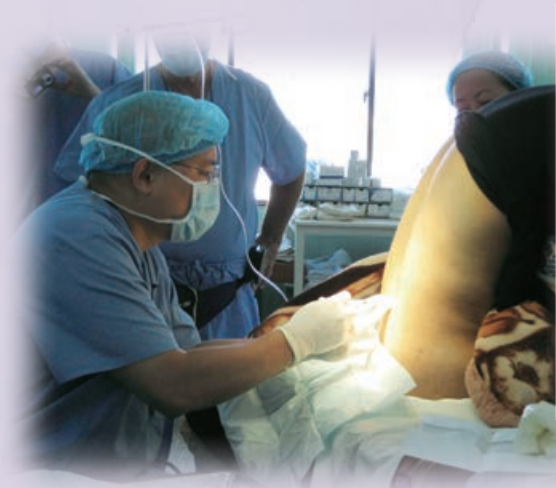
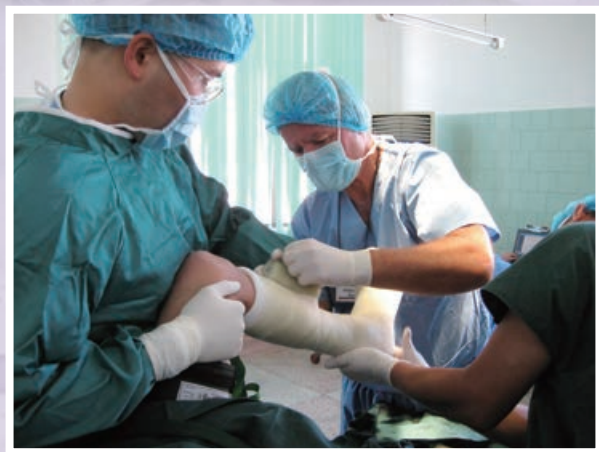
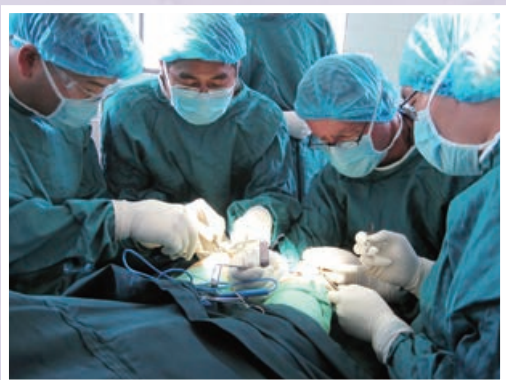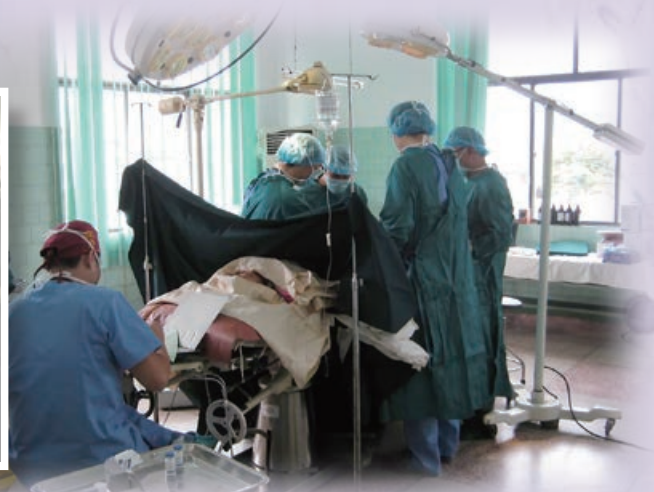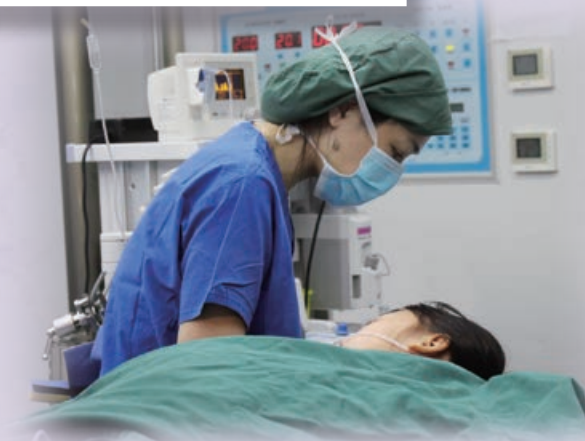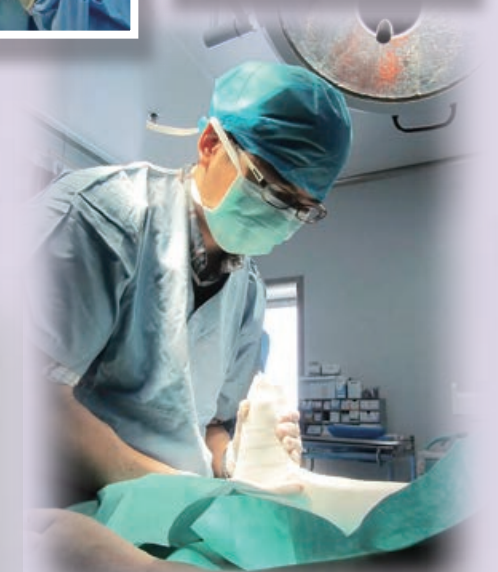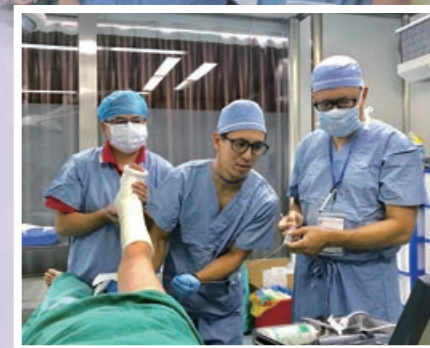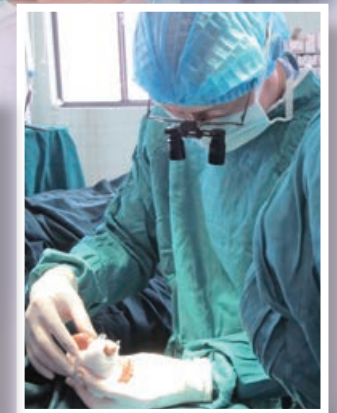
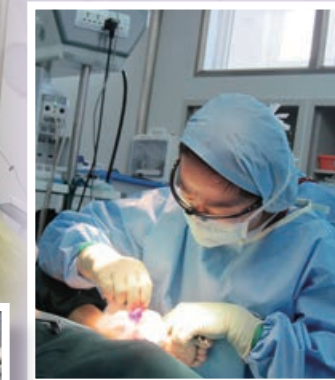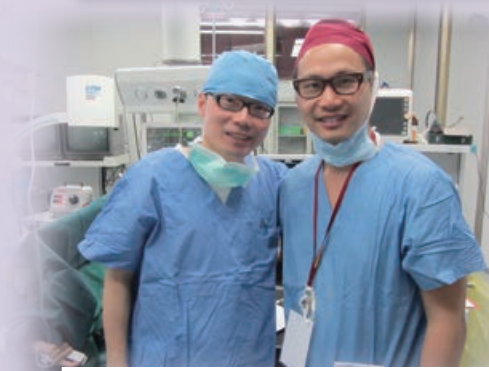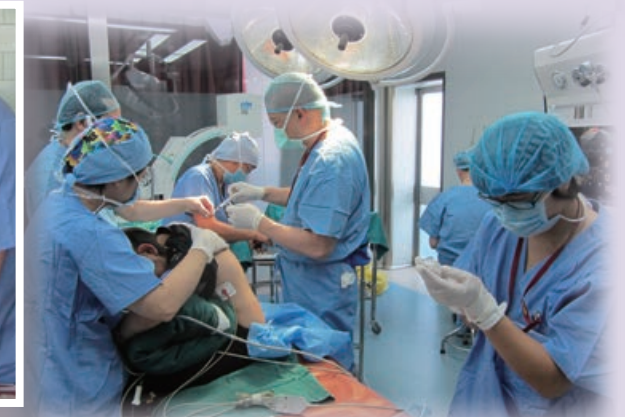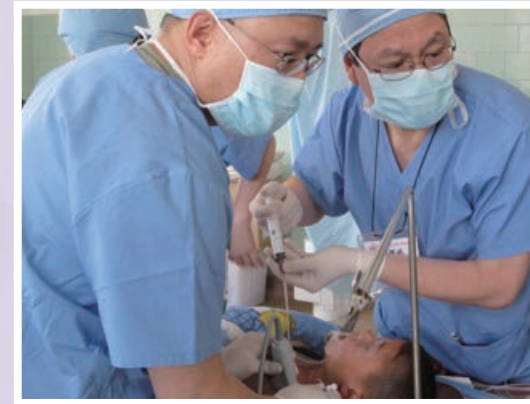滑縣骨科隊
Hua Orthopaedic Team



雲南篇 Yunnan Section

永平縣人民醫院
Yongping Remin Hospital

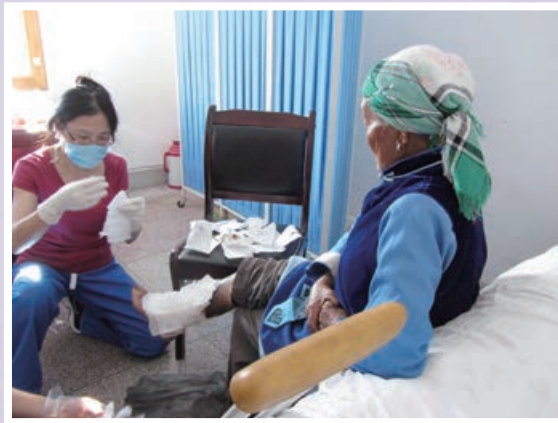

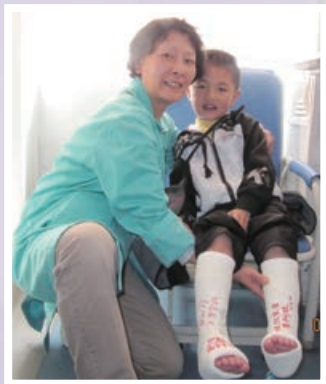



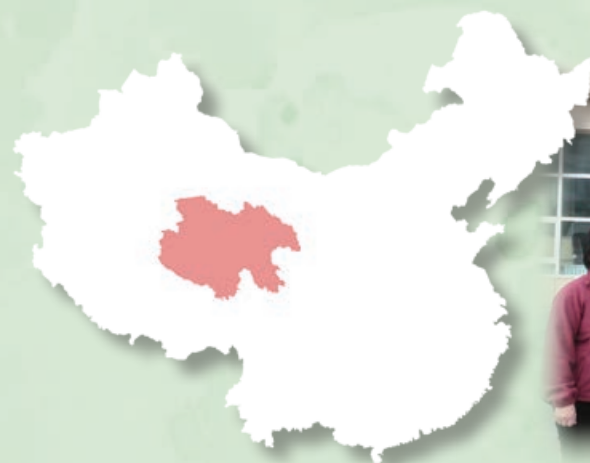
大理市第二人民醫院
Dali No. 2 Remin Hospital



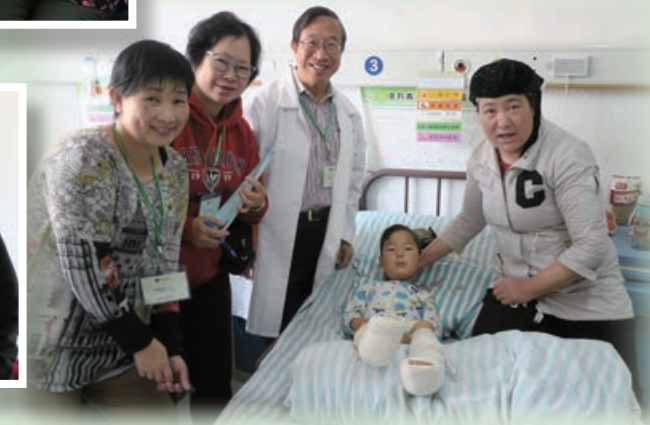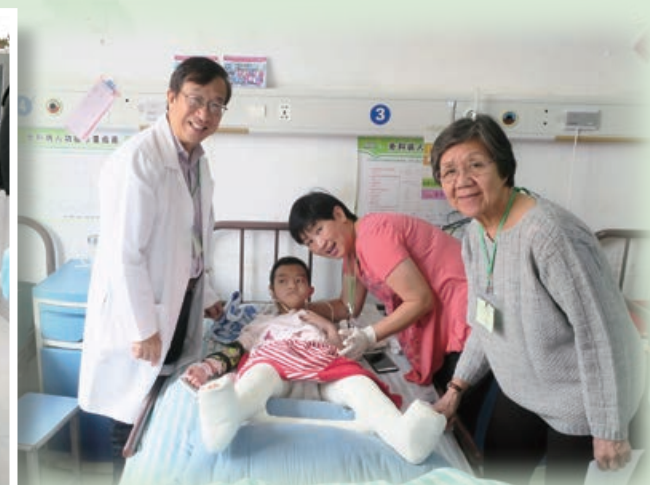2011



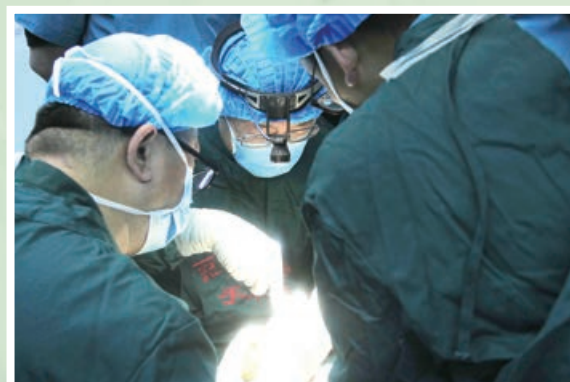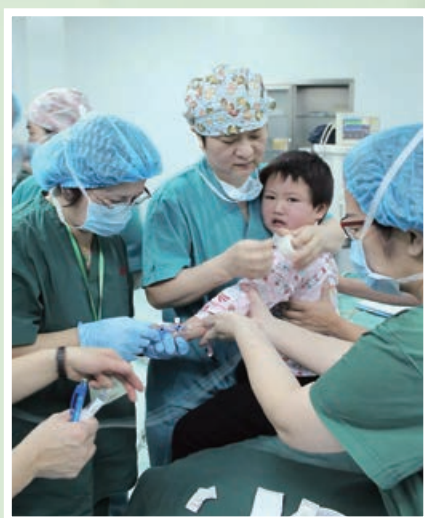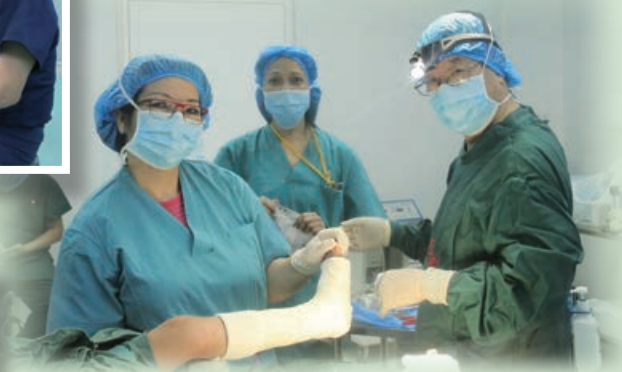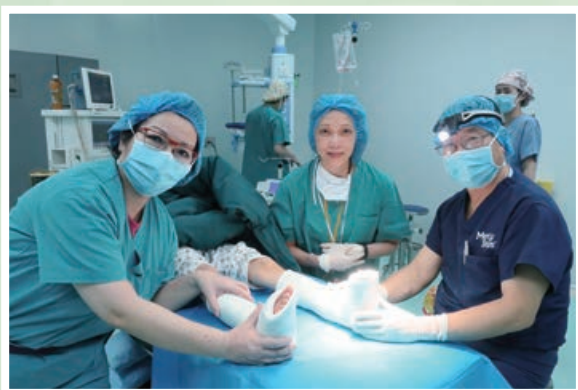2014
道別儀式
Farewell Ceremony



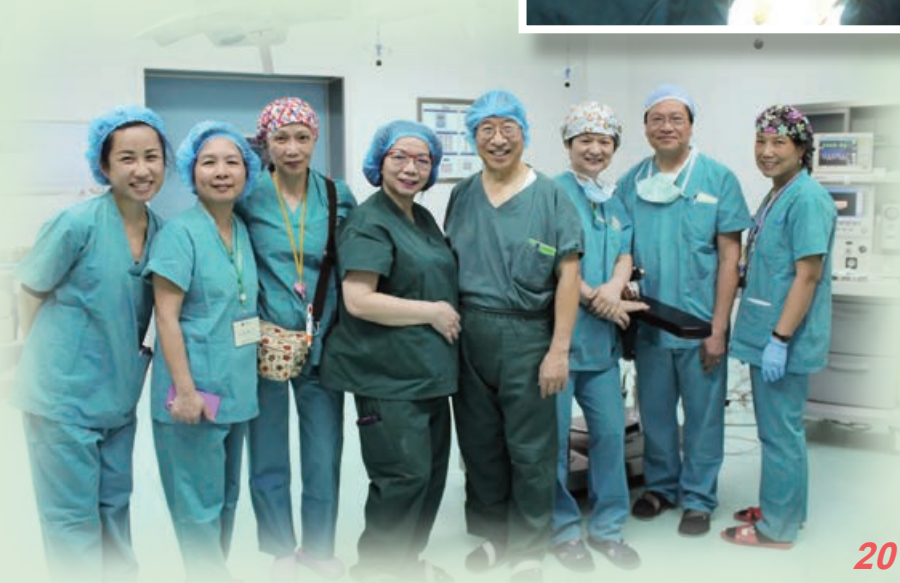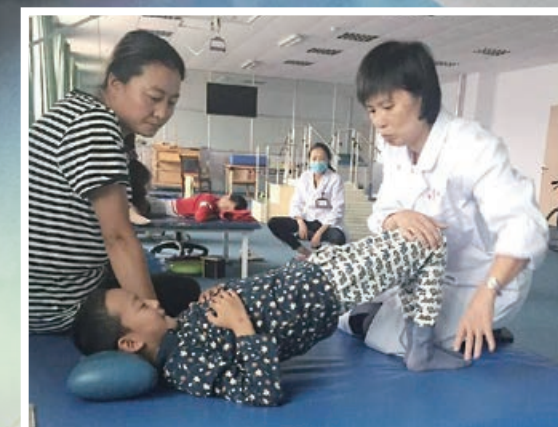青海篇 Section Qinghai



2018



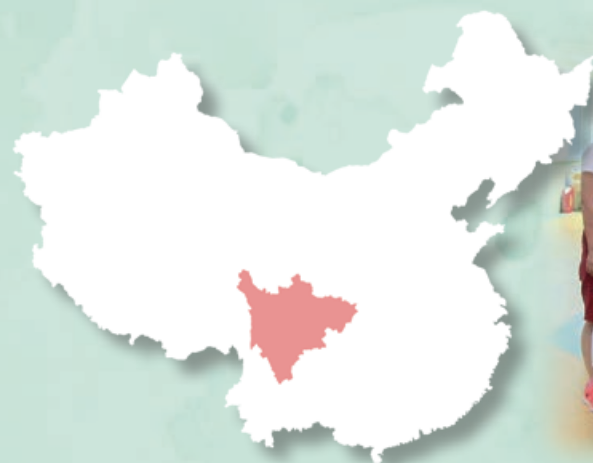物理治療
Physiotherapy



2018



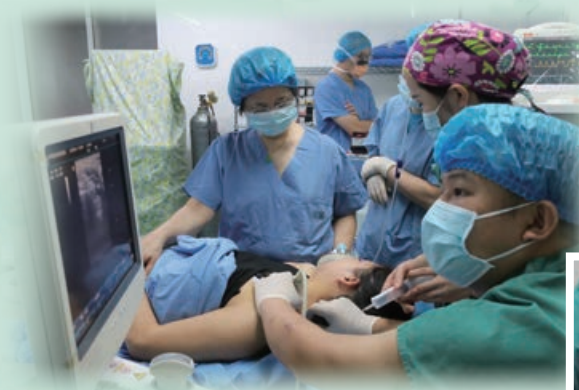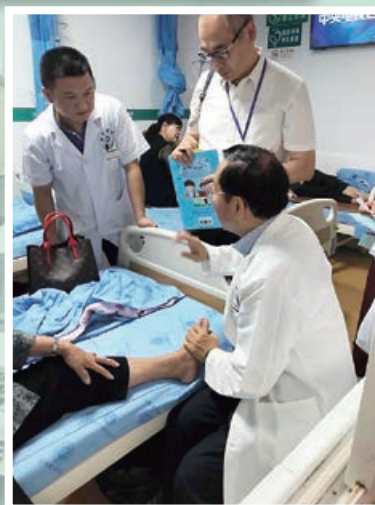2019



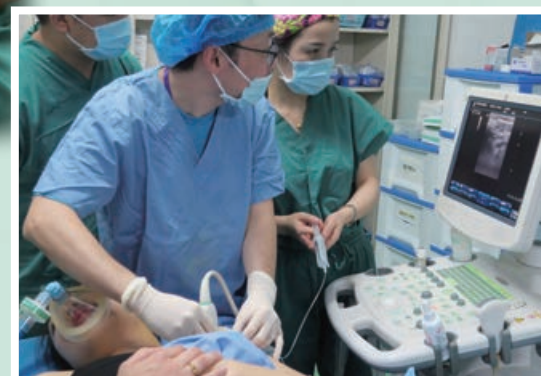四川篇 Sichuan Section

天鄰隊員與瀘洲福音醫院骨科部醫護人員合照。

Picture of HIS volunteers and Luzhou Gospel Hospital Orthopaedic Staff.

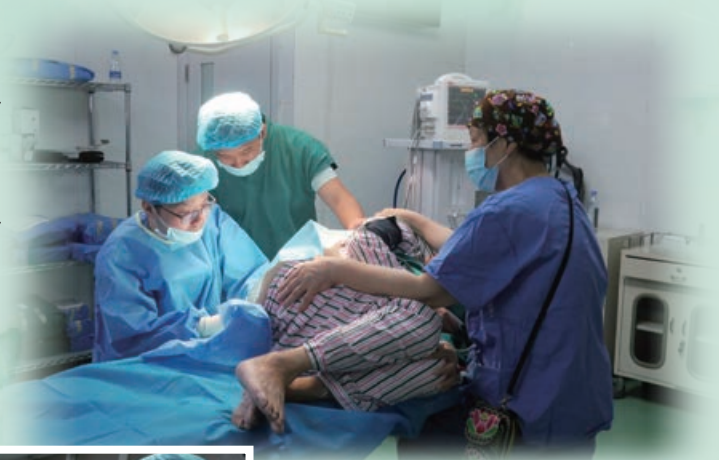

部位神經麻醉法
Regional Nerve Block

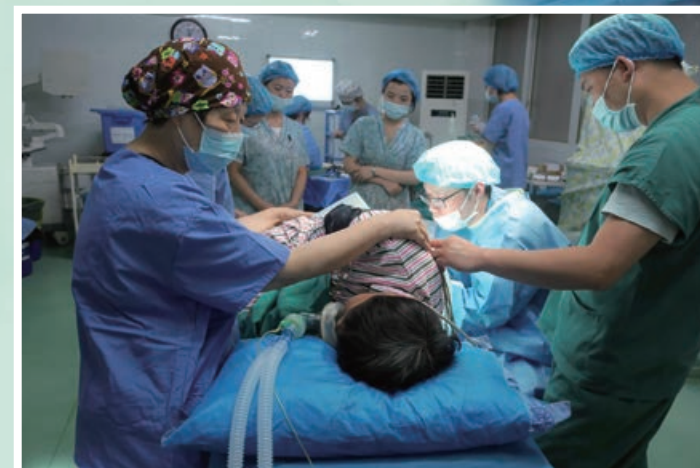

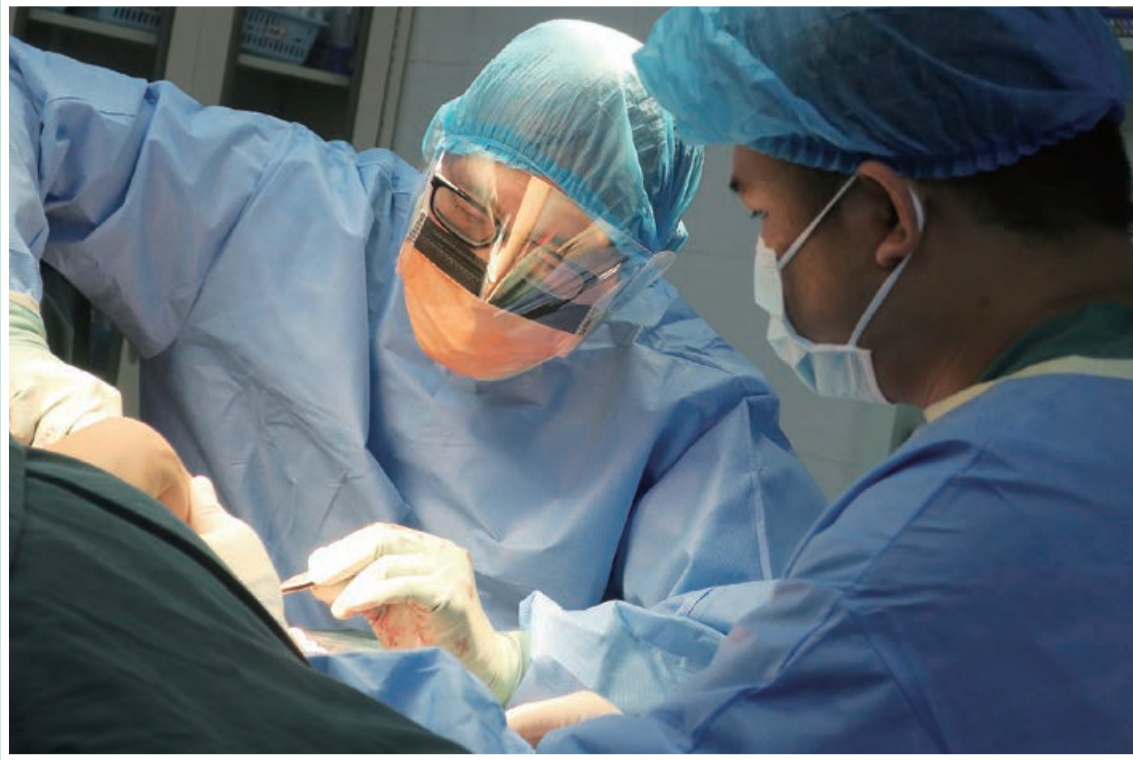
大部分骨科手術是上肢或下肢手術，很適合用部位神經麻醉法或脊髓麻醉法。一方面減少用全身麻醉帶來的風險，又可以引用作手術後止痛之用。

Most orthopaedic surgeries are upper limb or lower limb surgeries. It is very suitable to use regional nerve block or spinal anesthesia. On one hand it avoids risks associated with general anesthesia, on the other hand it is helpful for postoperative pain management.

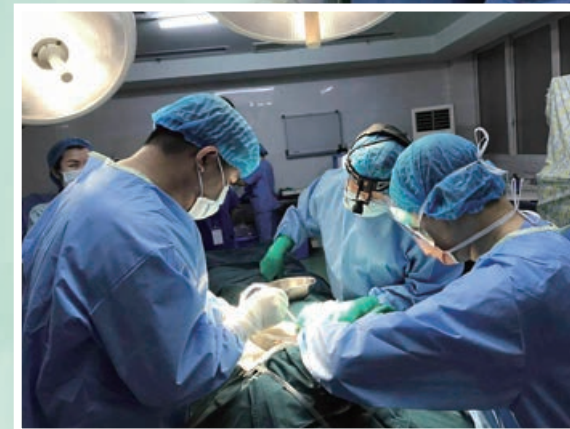
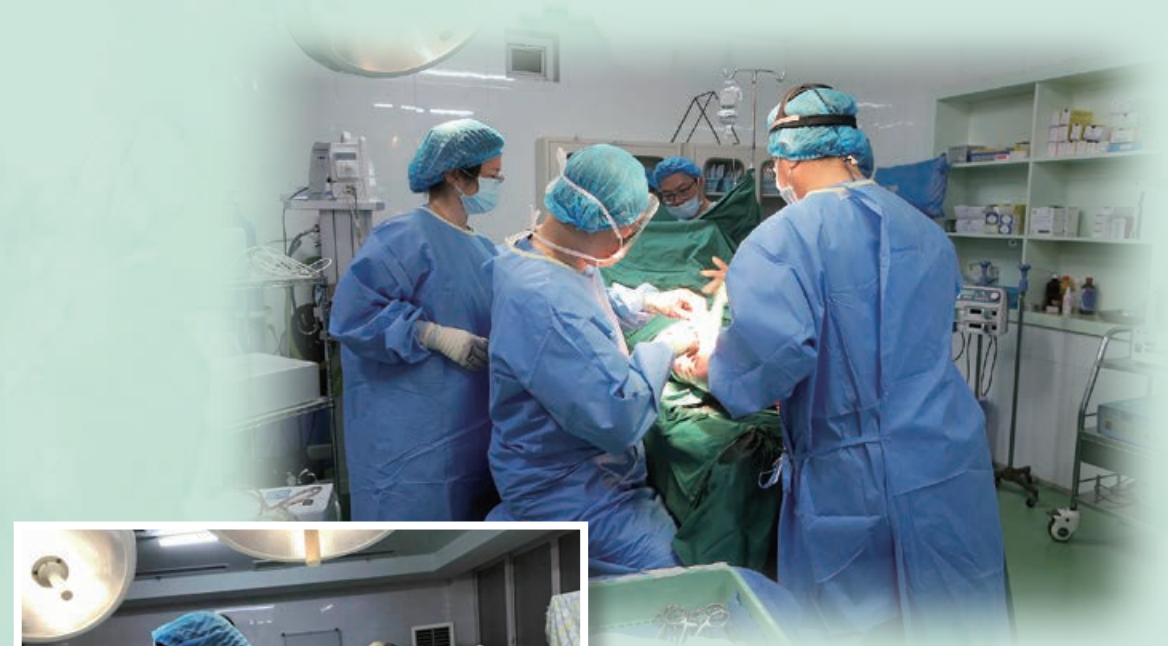
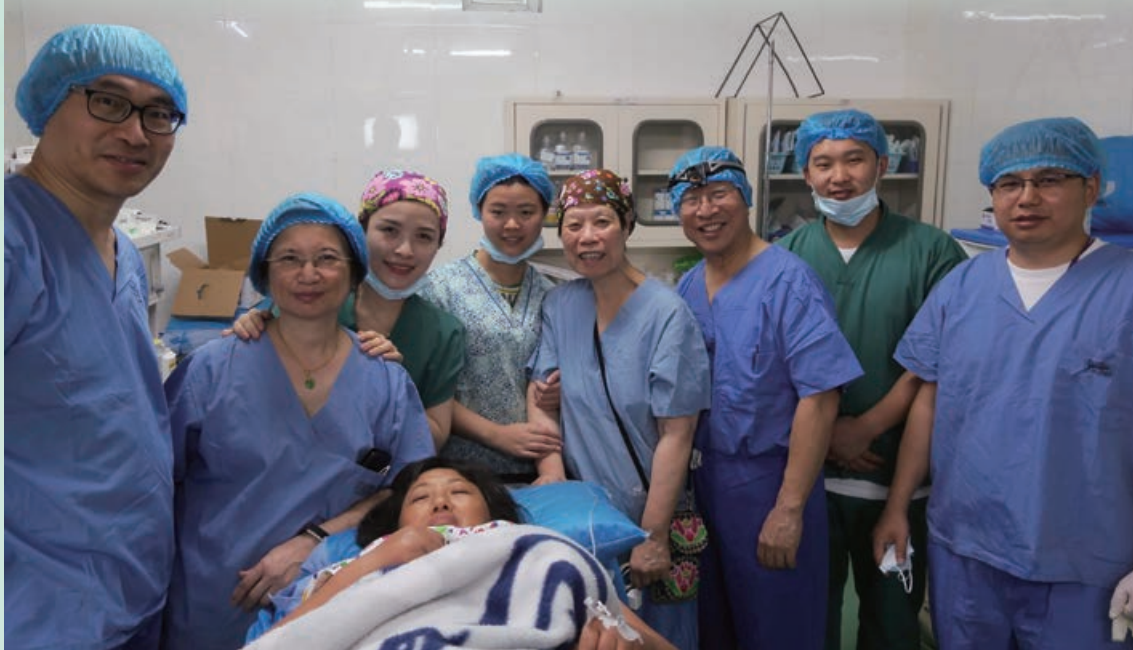脊髓麻醉法（腰麻）
Spinal Anesthesia





天鄰手術隊員與瀘洲福音醫院醫護人員在手術完成後合照。
HIS Foundation surgery team members had picture with medical staff at Luzhou Gospel Hospital after completion of an operation.



醫護人員與覆診病人合照。
Medical staff had photos with patients at follow up.

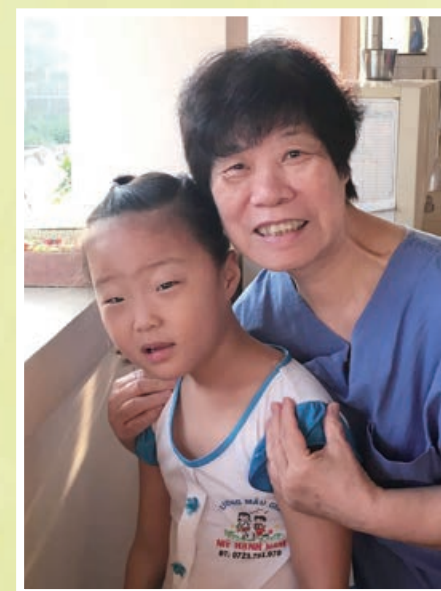
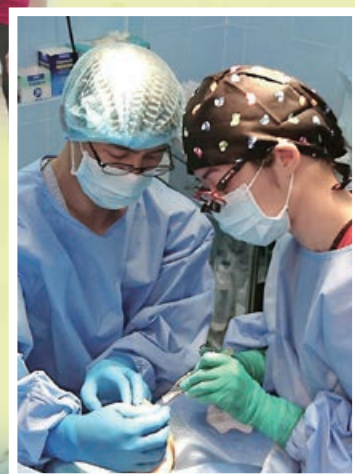


第一隊越南隊 The First Vietnam Team



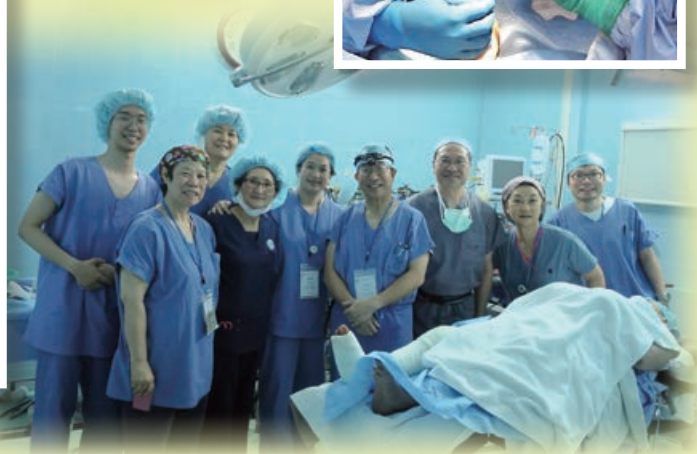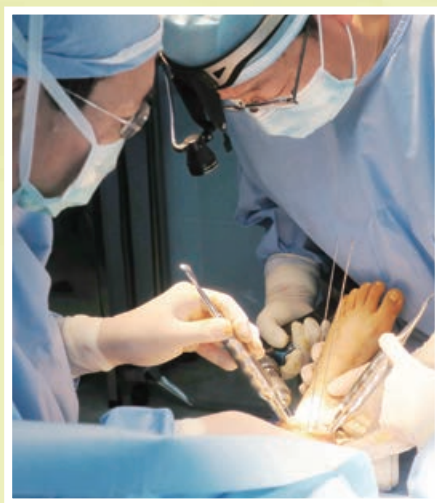門診
Clinics



早禱會
Morning Prayer

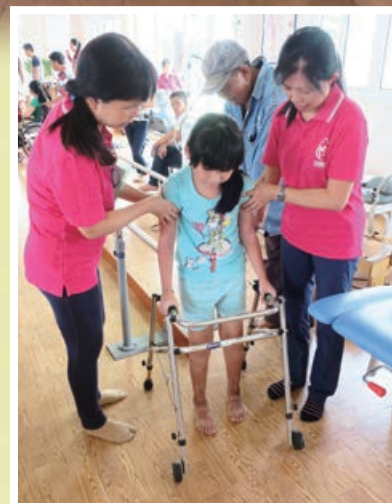
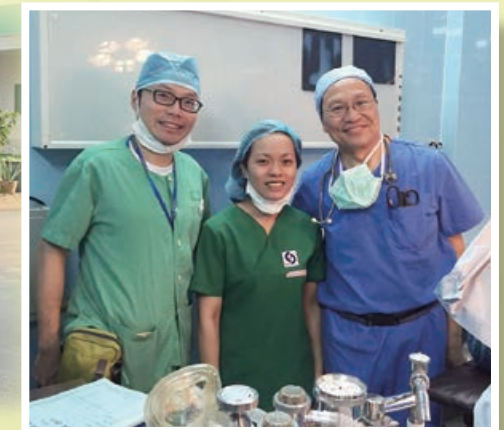
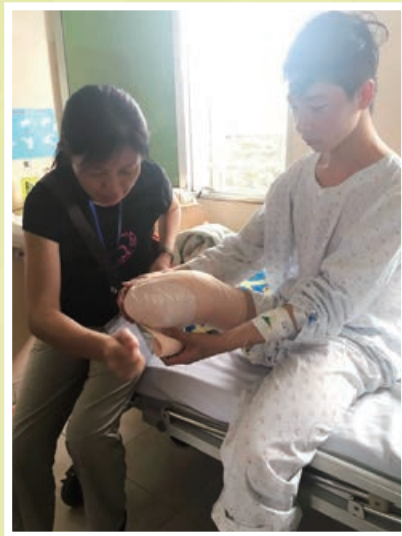越南篇 Section Vietnam



2017





與韓國醫院員工合照。

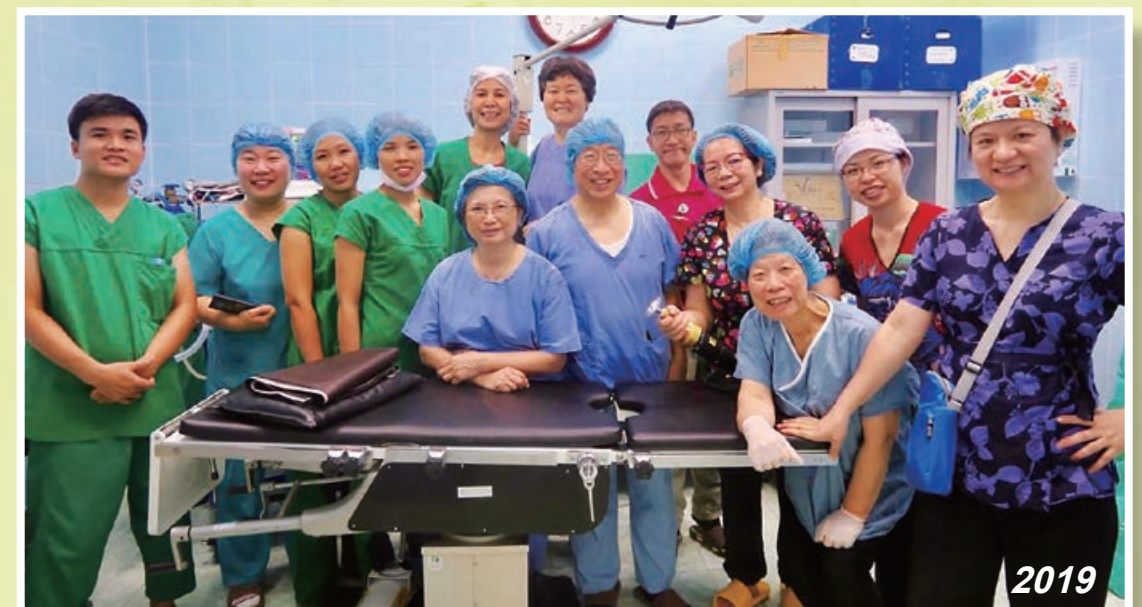Pictures with staff of Korean Hospital.



物理治療
Physiotherapy

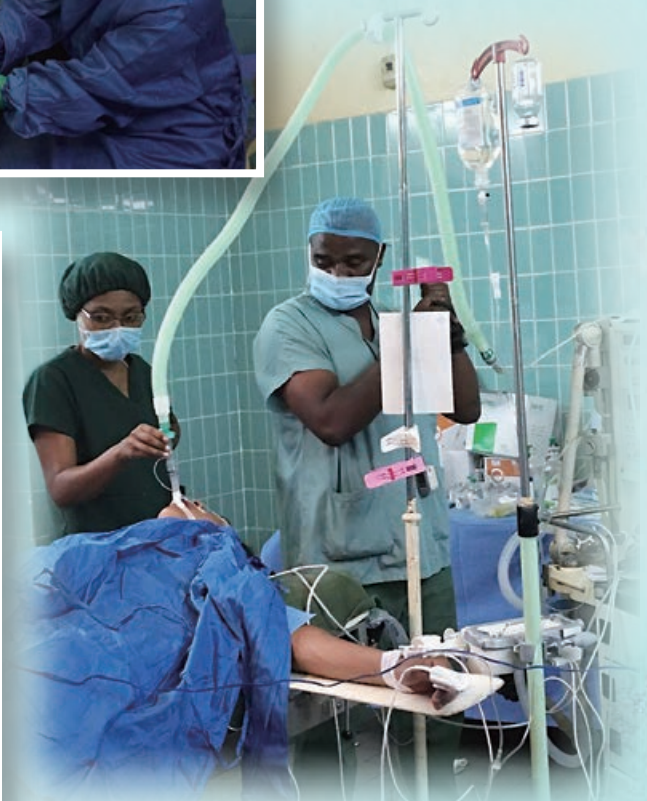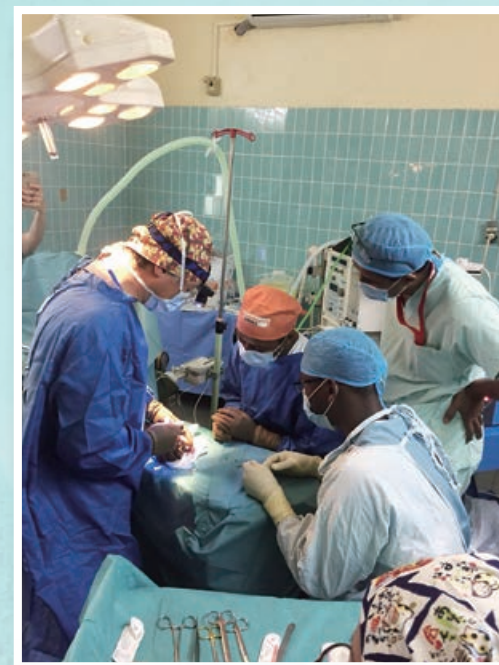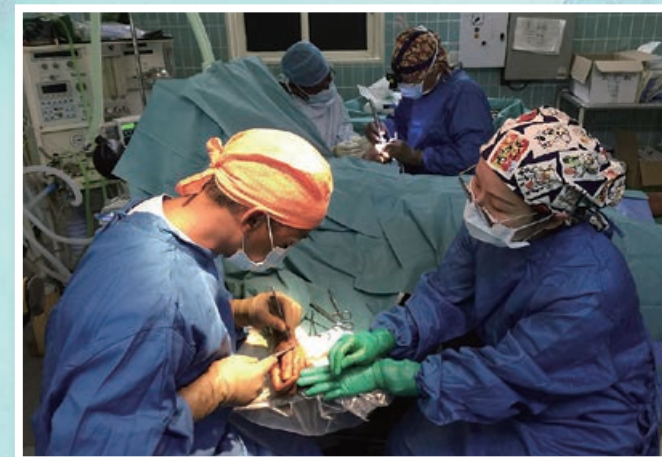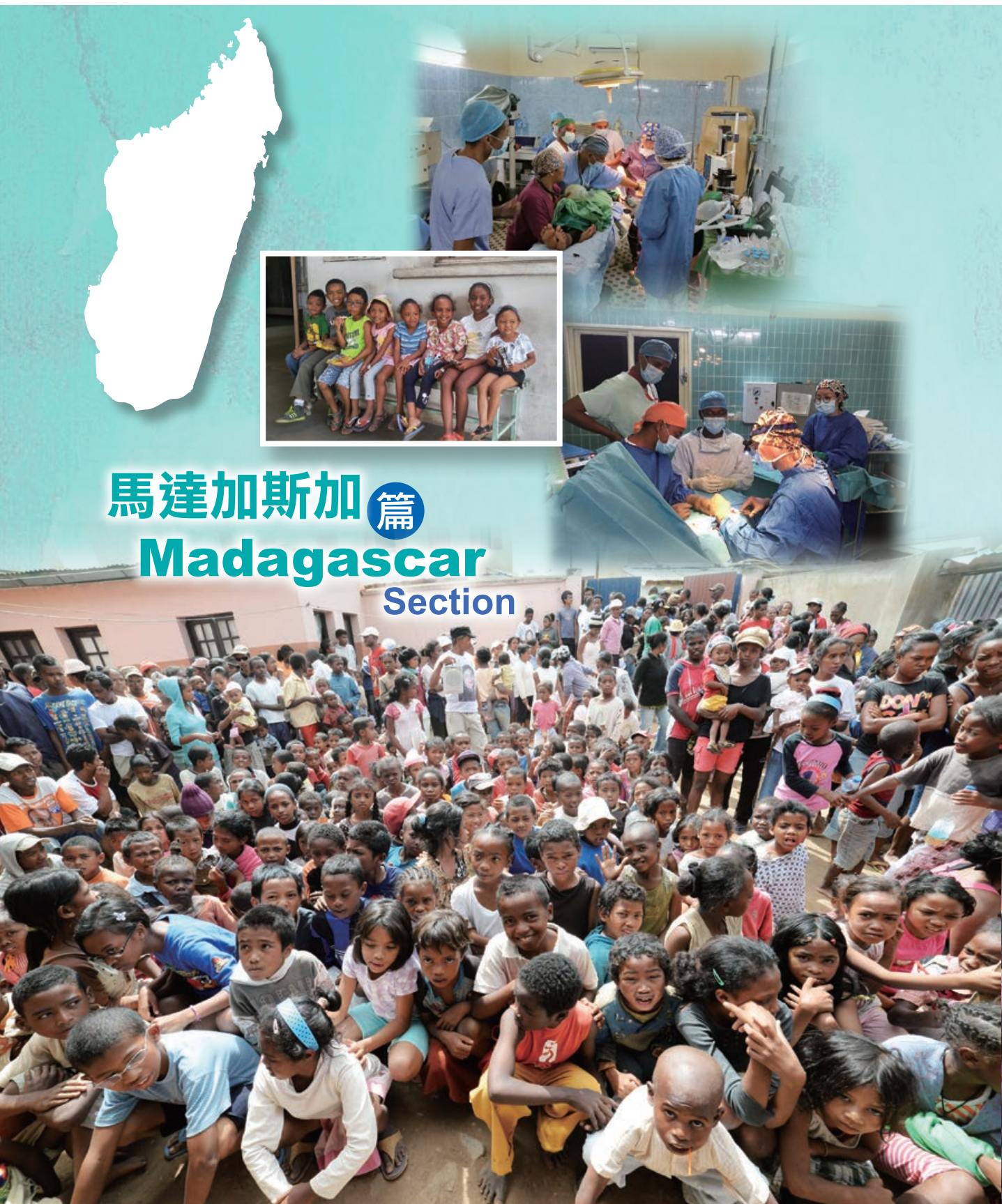與病人在病房唱歌。

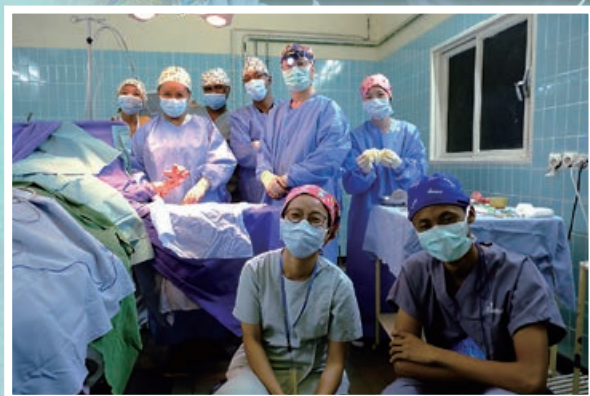Singing with patients in ward.



2019

馬達加斯加篇
Madagascar
Section

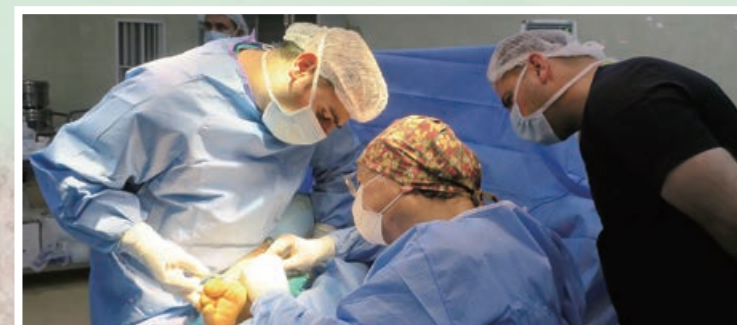



馬達加斯加手術隊
Madagascar
Surgery Team



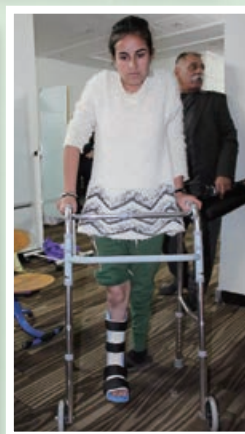庫爾德斯坦篇 Kurdistan Section



第一隊手術隊
The First Surgery Team

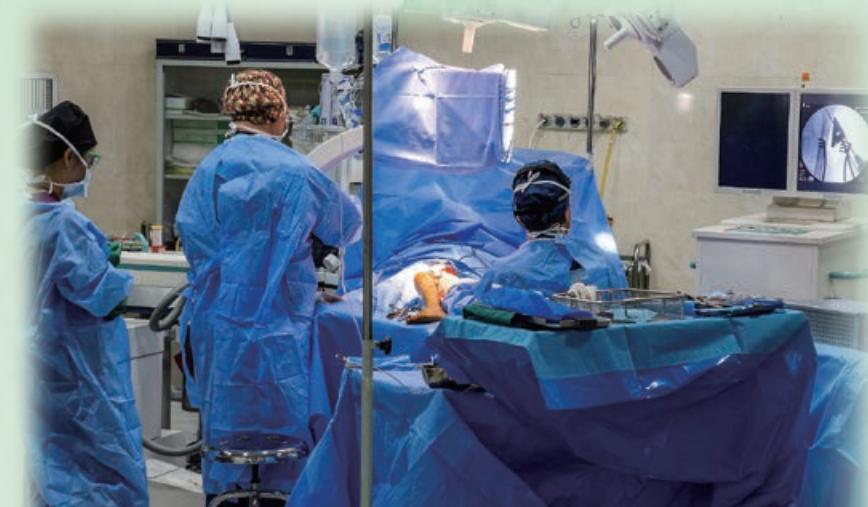
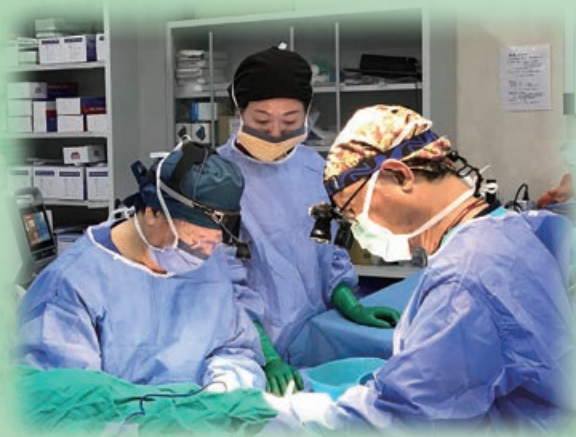
門診
Clinics

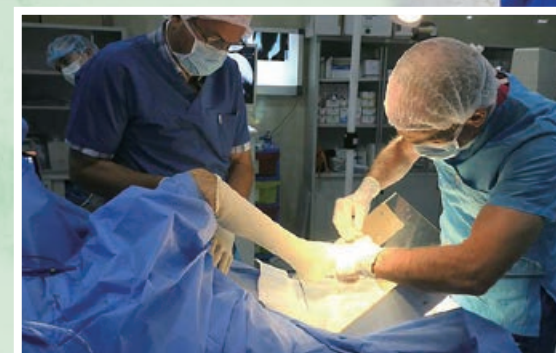
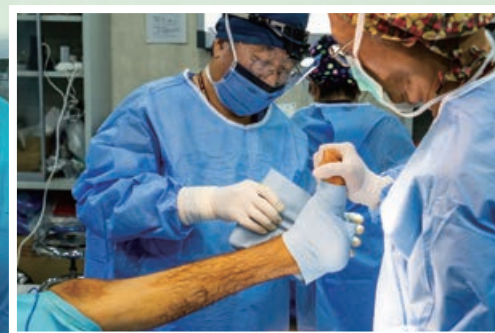
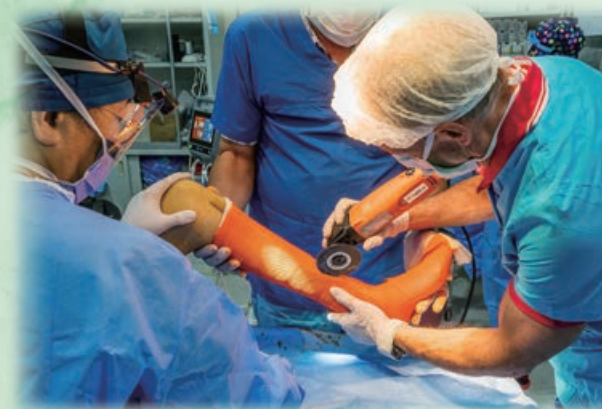
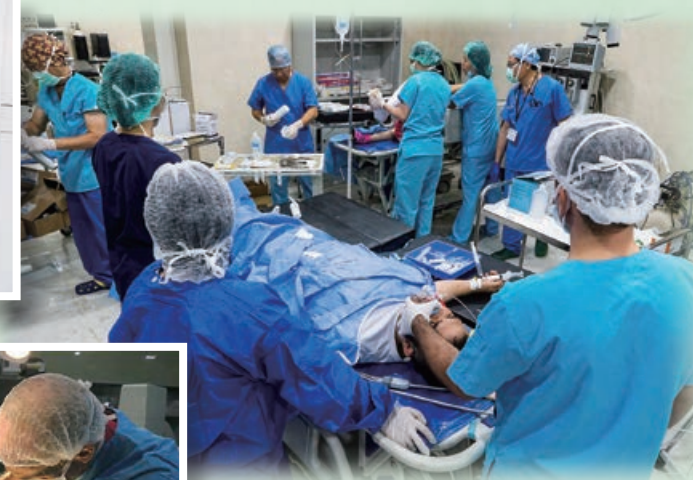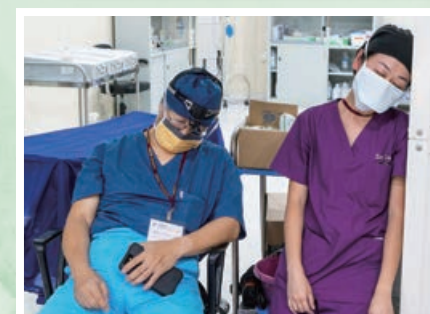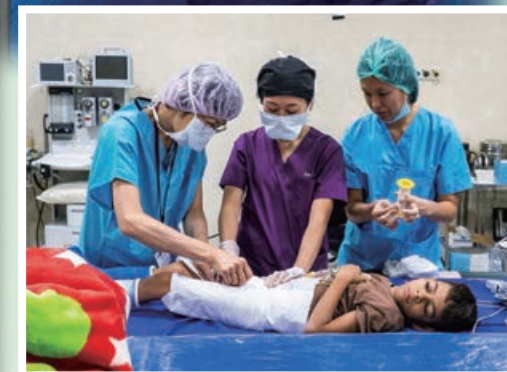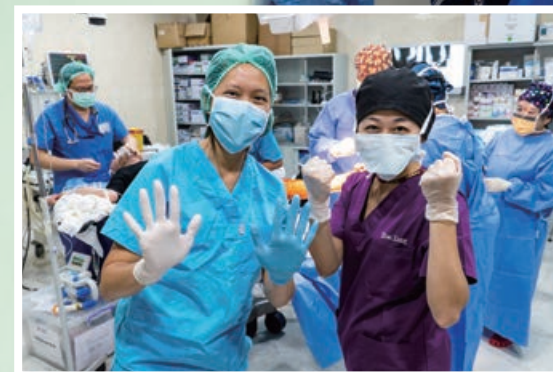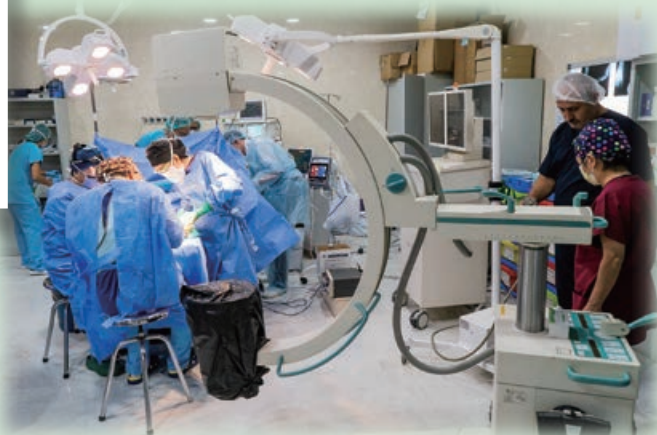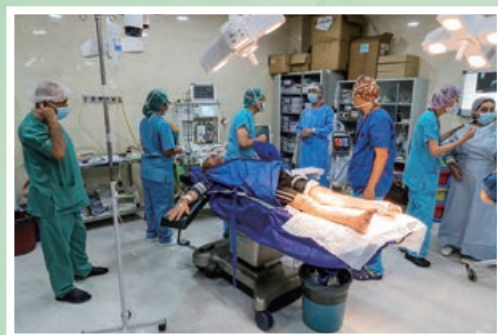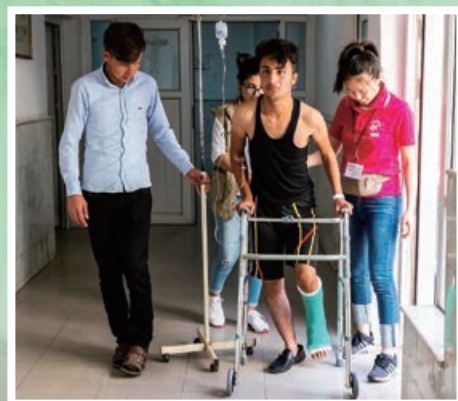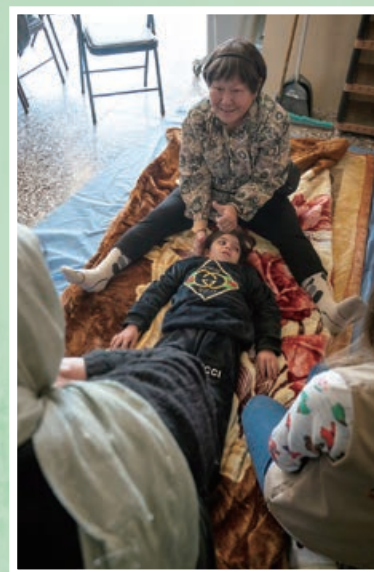初生嬰兒
髖關節篩查診所
Baby Hip Clinic





手術室
Operating Room





物理治療
Physiotherapy



病房
Ward





難民營探訪病人
Visitation of Patients
in Refugee Camp



病人感言篇

Patients' Words of Appreciation Section



病人感言..... From the heart of our patients.....

李飛 Li Fei

如果沒有你們的到來，我的孩子或許永遠不會站起來，你們的團隊給我的孩子帶來了希望，給我的家帶來了幸福。你們實在是太辛苦了，沒日沒夜的工作，你們無私的奉獻給孩子帶來了快樂，你們的精神值得我們永遠學習，你們的愛心將永遠在我們心中。

病童李飛的父母

If HIS Foundation surgery team had not come, my son may never had been able to stand up. You bring blessings to our family. You bring hope to our child.

You work really hard day and night. Your selfless sacrifices bring joy to our child. Your servant spirit is respectable and is something we should learn. We will always remember your love.

Parents of Patient Li Fei



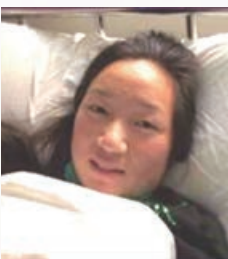祁晶晶 QUI JING JING

您們對我是百般的呵護，讓我感到家的溫暖，親人的愛護，您們百般不厭一遍又一遍問我有何不適，讓我為之感動。您們是耶穌給我們的使者，如果沒有您們，我就無從談健康，更不能快快樂樂的生活。

是您們給予我第二次生命的機會，改變命運，使我們過的更快樂幸福，總之一句話非常的感謝您們。

Your care to me make me feel the warmth of a family. You asked me again and again if I was uncomfortable. I am deeply moved by your concern. You are agents sent by Jesus Christ. Without you, I cannot be healthy and cannot live happily.

You gave me a second chance to live. You changed my life, my destiny, and allowed me to have a joyful life. Thank you very much.



王岩岩 Wang Yan Yan

從前我為我的腿感到非常痛苦，非常失望，你們這次來為我帶來了希望，讓我感覺到生活的美好。你們為了我們非常辛苦，不顧得吃飯，不顧得睡覺，整天為我們奔波，讓我們感覺到了親情，你們就好像我最親近的人，我感覺到你們是用心對我們每一個人，非常的愛我們。

In the past I was very sad and disappointed due to my leg. Now you have brought hope to my life. You have made me experience beauty in life. You have been working tirelessly for us, forgetting about your meals, deprived of sleep, running around the whole day. I felt warmth and compassion. You are just like my closest relatives. I know that you are sincere to each one of us. You love us very much.



劉浩 Liu Hao

您們沒來之前，我不相信世界上會有人給病人看病不要錢，在這幾天內，我體驗到您們每一個熱愛的心。我要向您們學習，把愛心獻給每一個人。您們要走了，我好想您們。

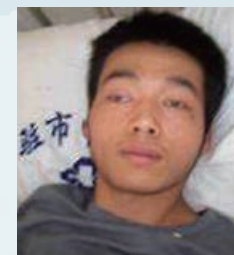Before you came, I did not believe that someone would provide medical care free of charge. In the past few days, I personally felt the great love from each of you. I need to learn from you. I will learn to love others. I will miss you a lot after you left.



張川川 Zhang Chuan Chuan

能夠接受你們的手術，我非常高興！十九年了，我從沒站過，是你們幫我實現了十九年的夢。我願你們永遠健康長壽，因為只有你們健康了，更多人的夢才有望實現。

I am so glad that I could have surgery performed by HIS Foundation. For nineteen years already, I have never stood up. You helped me to fulfill my dream of nineteen years. I wish that all of you are healthy and live a long life. Only when you are healthy can the dreams of more people be fulfilled.



姚輝 Yao Hui

有古奶奶（天鄰病房護士）逗大家開心的笑，有 MJ（天鄰義工）為大家畫上精美的圖案，也有護士姐姐為我們每天查兩次房；我在這裡說一聲：“您們辛苦啦！”通過這次手術，您們給我有了重新走路的機會。我會好好珍惜這來之不易的機會，我要好好地謝謝您們。

We had Mrs. Gu (ward nurse) entertaining us and kept us smiling. MJ (HIS volunteer) came and drew beautiful picture for us too. Nurses made ward rounds twice a day. All of you really worked hard! Through this operation, I had a chance to walk again. I will treasure this valuable opportunity. I deeply appreciate and thank everyone of you for your hard work!



周炯 Zhou Jiong

你們是上帝派來的天使，平時我很煩惱，你們給我帶來了美好的希望，是主把愛通過你們送給了我們。感謝你們「愛的天使」！

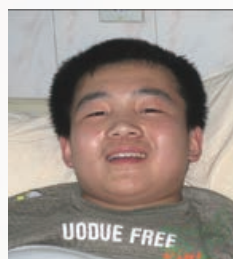I used to be troubled by my illness. You are the angel sent by God that brought us hope and love. Thank you, Angels of Love!



魯冲冲 Lu Chong Chong

你們的到來給我們帶來了莫大的高興，你們給我們這些受人歧視的兒童帶來了自信，感謝有你，讓我有勇氣作我自己。

Your coming is such a great pleasure for us. We, handicapped children, are discriminated against. However, you bring us confidence so that I can have the courage to be myself again.



孫芳芳 Sun Fang Fang

我們需要您們的愛，如同植物需要陽光雨露一樣，一顆小草怎能回報一座森林？我對叔叔阿姨們有道不盡的謝意和講不完的感受。

We need your love just like the plants need sunshine and water. How can a small plant return gratitude to the forest? My words are never enough to express my deep appreciation for your love.



孫磊磊 Sun Lei Lei

遇上天鄰基金會，是我一生最大的幸運。我本身天生就承受行動不便的痛苦，我對生活都失去了信心。您們為我做了手術，使我看到了前途，對生活又充滿了信心。

I was born with a disability and had difficulty walking. I felt no hope for the future. I am fortunate to have met the HIS Foundation. You performed surgery on me and let me have a new prospect for life.



喬海霞 Qiao Hai Xia


我接受了一個改變命運的重要手術，叔叔阿姨哥哥姐姐們是那麼細心認真無微不至的呵護照顧，令我感動的眼淚不止。每當傷口痛苦襲來的時候，可敬可愛的姐姐用熱情的目光，知心的話語，愉悅的表情，頓時把我感染，使我的疼痛瞬間一無所有，您們的點點滴滴我將永遠牢記在心。

I received an important life-changing operation. All members of the surgery team are so compassionate and caring. I am so touched that my tears cannot be stopped. Whenever I have pain, the respectable nurses came to me with so much kindness and empathy. Their loving attitude gave immediate relief to my suffering. I will remember forever everything you did for me.



劉影 Liu Ying

通過去年和今年的手術，通過你們的關心和愛護，把我從黑暗中送到了光明的世界裏，讓我重新認識到人生的歡樂與悲傷。我看到了我的腿從原來的彎曲到現在的伸直，從原來的軟弱到現在的有力，這一切的一切都是你們的功勞，是你們對我的愛心，所以，我對這次手術感到非常滿意，而且我以後也一定要學習你們那種救死扶傷、無私奉獻的精神。



Through the surgeries last year and this year and with the caring and love you gave me, I was brought from a world of darkness into a new world of hope and brightness. I learned again the joy and sadness in life. I see that my crooked legs became straight. My weak lower limbs become strong. All these are the results of your caring treatment. I am very pleased with the surgeries. I will learn from you the spirit of selfless care to help those who are sick or in need.

李元峰 Li Yuan Feng

百忙中送溫暖，患者心裏如蜜甜；送食物送藥棉，手術臺上送慈善；獻愛心去患難，病者心裏真喜歡。



Amidst your busy schedule, you came and provided compassionate care. You brought us food and medical supplies. On the operating tables, you showed your charity. Your loving concerns expelled our misfortune and filled our hearts with sweetness and joy.

侯巧娜 Hou Qiao Na

是您們給了我又一次生命，給了一個健康的我。我心裏很感激。我爸爸媽媽見到我恢復健康，心裏很高興。

I am so grateful that you gave me a new healthy life. My parents were filled with joy when they saw me recovered.



胡美娟 Hu Mei Juan

在這住院期間，您們的一言一行，對我無微不至的呵護和關懷，使我實在捨不得與您們的分離，您們為我們付出的辛苦和愛心，使我們永遠永遠感謝不盡！

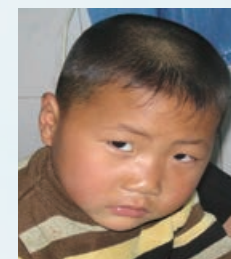

I am so impressed by your affectionate care during this period of hospitalization. You worked very hard and paid attention to every detail. I really missed all of you after you left. I can never thank you enough for all you have done for me.

閔豪豪 Run Hao Hao

您們給我兒子精心的治療和無微不至的照料，這種奉獻的精神，很值得我們大家學習宣傳。

閔豪豪家長



You gave my son expert treatment and meticulous care. Your spirit of sacrificial love is something we should learn and pass along.

Parents of Run Hao Hao

陳東媛 Chen Dong Yuan

在遇到你們到來的短短一年裡，我的女兒是進步變化最大的一年，也是我們一家開心的一年。在沒有遇到您們以前，我們是絕望、無助、失去方向，是你們的到來，讓我們再次朝氣蓬勃，積極主動起來。

陳東媛的媽媽



Our daughter has the greatest improvement in the one short year since we met. It is a happy year. Before we met, we felt desperate, hopeless, and with no direction. Your arrival let us become energetic and proactive.

Mother of Chen Dong Yuan

石棟峰 Si Dong Feng

感謝你們的無私奉獻，感謝你們一絲不苟的治病。你們讓我們灰色的世界裡充滿了愛，讓我們感受到了愛的力量，讓我們一起走進愛的世界，為了我們明天美好的生活共同祈禱吧！

Thank you so much for your selfless sacrifice. Thank you for your meticulous treatment. You filled our dark gray world with love. We feel the power of love. Let us enter a world of love. Let us pray for a beautiful world in the future.



張闖 Zhang Chuang

侄兒張闖身患殘疾已十三餘載，因看病花去家中全部資金，後來父母離異，因此，照顧張闖的重擔就落在年邁多病的奶奶身上。由於侄兒生活不能自理，只能靠雙拐支撐走路，所以奶奶的傷心與痛苦就可想而知了。就在奶奶悲傷絕望之時，天鄰來了，並免費收治張闖入院。在住院期間，給侄兒送衣送物，嘘寒問暖，對張闖無微不至的關懷，使失去父母的侄兒倍感溫暖。我這個做姑姑的，看到這一幕幕感感人的事蹟，常常感動流下幸福的眼淚，真的謝謝！



患兒張闖的姑姑

My nephew Zhang Chuang is disabled for 13 years. The family spent all their fortune on seeking medical treatment. Later, the parents were separated. The duty of taking care of Zhang Chuang falls on the grandmother who is old and infirmed. Zhang Chuang was not able to take care of himself. He could only walk with a pair of crutches. Grandmother felt very sad and miserable. At the time of great despair, the HIS Foundation came. Not only did HIS Foundation accepted my nephew for treatment free of charge, but also gave him gifts and clothing. The care was personal and meticulous. It really warmed the heart of my nephew who lost both parents. As I witnessed these acts of compassion, I was not able to stop my tears. Thank you so much!

Aunt of Zhang Chuang

張瀟 Zhang Xiao

……就在我們陷入失望、想放棄之時，聽到了“天鄰”這個來自天堂般的聲音，又讓我們燃起了希望之火。……受到了你們熱心的幫助和積極的治療，我們真的很高興，我們為孩子慶幸。

張瀟的父母

……at the time of disappointment and when we wanted to give up, we heard about “HIS Foundation”. It was like a sound from heaven. It rekindled our hope. ……We are happy for our child because he received passionate and aggressive care from you.

Parents of Zhang Xiao



張洛樂 Zhang Luo Le

小時候由於自己的不小心，將雙手給燙傷了。自從遇見了你們，使我在生活中有了很大的變化。使我對自己的未來充滿了信心，使我從迷茫中找到了道路，給了我一條溫暖的陽光大道，充滿溫馨。

When I was little, my hands were scalded by hot water due to a careless mistake. My life has changed a lot since I met you. I am now confident about my future. I was lost but now I found a road full of sunshine, warm, and fragrance.



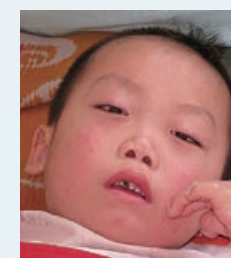
董留留 Dong Liu Liu

當聽到天鄰基金會向腦癱病人獻愛心，扶貧救人的好消息，我們心中感到萬分高興。你們給我的兒子做了手術，又萬般照顧。你們救了我的兒子，也救了我全家，你們是我兒子的再生父母，謝謝你們。

董留留的母親

We were excited after we heard about the good news of HIS Foundation. HIS Foundation offered treatment for the poor and the sick. Also, HIS Foundation rendered passionate care for cerebral palsy patients. You performed surgery on my son and gave him care in many areas. You saved my son. You saved my whole family. You are the second parent of my son.

Mother of Dong Liu Li



後記 Epilogue

劉漢杰醫生 James Lau, MD

在編輯這見證集時，有很好的機會去數算主的恩典，在此與大家分享。

神的帶領

天鄰基金會的醫療工作，由三十年前一個小規模的河南醫療事工開始，當時只是組織香港講學隊，到河南講授醫療知識給農村的醫護人員，後來發展成內科隊和牙科隊，再發展成骨科隊、矯形手術隊及輪椅隊。骨科隊的工作由河南省許昌市開始，後來去到河南省的其他地區包括洛陽、駐馬店、沁陽、安陽及滑縣等。日後更由河南省發展到其他中國省份（雲南、青海、四川等）。

近年中國漸漸限制國外非政府機構的活動，神卻為天鄰開啟中國以外的宣教禾場，骨科隊到越南及馬達加斯加義診和做手術，自2018年起，去中東的庫爾德斯坦為難民服務。

During the editing of this testimony book, I was able to count the blessings from our Lord. I would like to share some of my thoughts with you.

God's Guidance

The medical ministries of HIS Foundation started 30 years ago as a small medical project for Henan Province. Teams of medical professionals from Hong Kong were organized to give lectures to medical personnel in rural areas in Henan. This project later added internal medicine and dental teams, and it eventually grew to include orthopedic and plastic surgery teams as well as wheelchair teams. The orthopedic services started in Xuchang, Henan. Subsequently, teams were sent to other areas in Henan including Luoyang, Zhumadian, Qinyang, Anyang, and Hua. In ensuing years, teams ventured to other provinces in China (Yunnan, Qinghai, and Sichuan).

In recent years, new policies implemented by the Chinese government placed tight controls on overseas non-governmental organizations. God, however, led HIS Foundation to other mission fields. Orthopedic teams were sent to Vietnam and Madagascar. Since 2018, teams have gone to Kurdistan to serve the refugees.

這樣的發展過程，大大超越了當初天鄰董事局的計劃和想象，卻又見證了聖經中兩段經文的真實：

人心籌算自己的道路；惟耶和華指引他的腳步。（箴言 16:9）

天怎樣高過地，照樣，我的道路高過你們的道路；我的意念高過你們的意念。（以賽亞書 55:9）

神的供應

組織骨科隊需要大量的人力及物力資源，專業人士方面，除了骨科醫生和護士之外，還需要麻醉科醫生、物理治療師、職業治療師和支具師。神好像早有安排，每次組隊都得到各專業人員及非醫護人員的大力支持，有如水到渠成。

骨科隊需要龐大的手術器材，而合作醫院往往都非常缺少手術儀器。記得近年有一次到當地醫院服務，該院的所有骨科手術儀器都是放在一個手術盤子上，其缺乏可想而知。自開始，骨科隊得到多方的捐助，令手術器材方面日益充足，除自用外，更經常捐贈予我們合作的醫院。

This course of development far exceeds what our original board of directors might have imagined. Clearly, it testifies to the truth of the Scriptures:

The heart of man plans his way, but the Lord establishes his steps. (Proverbs 16:9)

For as the heavens are higher than the earth, so are my ways higher than your ways and my thoughts than your thoughts. (Isaiah 55:9)

God's Providence

The organization of orthopedic teams requires a wealth of human and material resources. Among the necessary medical professionals are orthopedic surgeons, anesthesiologists, nurses, physical therapists, occupational therapists, and orthotists. Fortunately, God seems to have had these needs planned ahead of time. The ministries received great support from many medical and non-medical volunteers, and the work proceeded naturally and smoothly.

Orthopedic teams must also have various surgical instruments, but our partner hospitals usually lacked sufficient surgical devices. Recently, in one of the local hospitals, all the orthopedic instruments could fit on a single tray, a striking illustration of the deficiency in essential

此外，醫療隊經常遇到非常好的合作伙伴，例如當地教會、紅十字會、政府及基督教團體等，這些合作伙伴是醫療隊成功的關鍵。這一切都見證了神豐富的供應，超越我們所想所求。

神的保守

骨科手術是帶有一定風險的手術，併發症是無可避免的。手術隊工作的環境往往比隊員日常工作的環境差，消毒和防疫處理亦非完善，但在數以千計的手術中，手術的併發症很低，而且往往化險為夷，都可以完滿解決。

手術的成功不是必然的，即使有好的技術和計劃，手術效果亦有強差人意之時。我們一些病人需要經過多次的手術才能達致滿意的效果。

在接近三十年的手術治療中，天鄰從來沒有醫患糾紛。相反地，我們收到數以百計的感謝信和感謝旗，都令我們的隊員感到安慰和自豪。我深信，這一切的成功，背後是有神的祝福和保護，如經上所記，

若不是耶和華建造房屋，建造的人就枉然勞力；若不是耶和華看守城池，看守的人就枉然警醒（詩篇 127:1）。

instruments. Fortunately, our orthopedic teams received plentiful donations from various sources and accumulated abundant instruments, so much so that we were able to donate some to our partner hospitals.

Our orthopedic teams frequently join with good ministry partners. These include local churches, the Red Cross Society, local government, and other Christian organizations. These partners are key to the success of the orthopedic ministries. All testify to the rich providence of God, much more than we can hope for.

God's Protection

Orthopedic operations inevitably face risks, and complications are unavoidable. Our teams work in environments usually much worse than the conditions at home. Sterilization and disease prevention are not perfect. However, in thousands of surgery cases, we maintained an extremely low complication rate. Moreover, almost all complications had very good outcomes after treatment.

Success is not a natural outcome of surgery. Sometimes even with careful planning and excellent techniques, the results were not ideal. Some of our patients had to undergo multiple surgeries to achieve good results.

神的僕人

我相信，天鄰的工作是神喜悅的工作。參加事奉的天鄰隊員是神手中一件器皿，去完成祂的善工。我們需要做的，就是順服神，願意為神所用，成為祂用來祝福別人的工具。在這過程中，我們亦得到神的祝福，這其實是神事工的奧秘，施比受更為有福。

神能將各樣的恩惠多多地加給你們，使你們凡事常常充足，能多行各樣善事。（哥林多後書 9:8）

In almost 30 years of surgical treatment, HIS Foundation has never had a malpractice case brought against us. On the other hand, we received hundreds of letters of appreciation and appreciation banners. These gestures really warmed the hearts of our team members and made them proud of their services. I strongly believe that God has been protecting and watching over us. Just like the psalmist wrote:

Unless the Lord builds the house, those who build it labor in vain. Unless the Lord watches over the city, the watchman stays awake in vain. (Psalm 127:1)

God's Servant

I believe HIS Foundation ministries are in God's favor. Our volunteers are tools in the hands of our Lord which He uses it to accomplish his works. We must submit to God and let Him use us to bless others. During this process, we are being blessed as well. This is the mystery of God's ministry: the givers are more blessed than the receivers.

And God is able to make all grace abound to you, so that having all sufficiency in all things at all times, you may abound in every good work. (2 Corinthians 9:8)



讓我走動：天鄰骨科見證

Let Me Move:

A Testimony of HIS Foundation Orthopaedic Services

- 編輯 Editor :
劉漢杰 James Lau
- 出版 Publisher :
美國天鄰基金會 Holistic Integrated Services Foundation
- 聯絡地址 Mailing Address :
P.O. Box 2638
Fullerton, CA 92837, U.S.A.
- 電郵 e-mail : HISFound@aol.com
- 網頁 Website : www.his-foundation.org

奉獻方法 Donation

美國 United States of America

支票抬頭 check payable to : HIS Foundation

郵寄地址 mail check to :

P.O. Box 2638, Fullerton, CA 92837, USA

信用卡付款請在網頁辦理

www.his-foundation.org

Pay with credit cards

can be done at website www.his-foundation.org

用 Zelle 付款, donate@his-foundation.org

Pay with Zelle, donate@his-foundation.org

澳洲 Australia

銀行 Bank : National Australia Bank (NAB)

戶口 Account : Holistic Integrated Services (HIS)

Foundation Australia Incorporated

戶口號碼 Account number : 82-814-7811

BSB : 082-604

請將銀行存根經電郵交回

Please send deposit receipt by e-mail to :

電郵 e-mail : australia@his-foundation.org

香港 Hong Kong

銀行 Bank : 匯豐銀行 HSBC

戶口 Account : 042-1-049479

支票抬頭「天鄰基金會有限公司」

Cheque payable to HIS Foundation Ltd.

請將銀行存根寄 Mail deposit receipt to :

香港銅鑼灣謝斐道 408-412 號華斐商業大廈 1401 室

電話 Phone : (852)2794 9400

傳真 Fax : (852)2794 3900

電郵 e-mail : info@hisfoundation.org.hk

網頁 website : www.hisfoundation.org.hk

書籍分類：基督教 / 見證 / 宣教 / 慈善

Category: Christian/Witness/Mission/Charity

ISBN 978-988-76004-1-1



書籍分類：基督教 / 見證 / 宣教 / 慈善
Category: Christian/Witness/Mission/Charity

ISBN 978-988-76004-1-1



9 789887 600411